

## Case Report

# Penile tourniquet injury due to a coil of hair

Suresh M. Chaware, Raj Gajbhiye\*, A. K. Singh

Department of Plastic and Reconstructive Surgery, King George's Medical University, Lucknow (U.P.) and \*Indira Gandhi Medical College, Nagpur, India

**Address for correspondence:** Suresh M. Chaware, c/o Mr. Gunwant Khode, Plot No. 160, Balaji Nagar Extention, Nagpur, Maharashtra - 440027, India. E-mail: surmadhuchaware@yahoo.co.in

### ABSTRACT

Penile strangulation caused by a coil of hair is frequently an unrecognized clinical entity with several potential complications, such as necrosis of glans penis, urethrocutaneous fistulae and partial or complete amputation of the glans. We report on a 7 year old boy with a tourniquet injury to the penis secondary to strands of hair being tied around the glans at the level of the corona.

### KEY WORDS

Coil of hair, penile, tourniquet injury

### INTRODUCTION

The loss of the fingers and toes by accidental entwining of hair is well known. Penile tourniquet syndrome too is worldwide in distribution and has been reported from many countries including Algeria, Egypt, England, Germany, Jordan, Lebanon, Saudi Arabia and the United States. Whether accidental, incidental to circumcision or intentional, it could lead to serious complications: urethral fistula, urethral stricture, penile deformity, gangrene and amputation. It is not always easily recognizable and the physician should keep it in mind whenever a boy or even an older man, presents with unexplained swelling of the penis. Because hair is extremely fine and lies in a groove of edematous and swollen tissues, the diagnosis can be easily missed for balanitis unless specifically thought of.

Utilizing a single stage repair in our patient we were able to save the glans and provide a satisfactory cosmetic

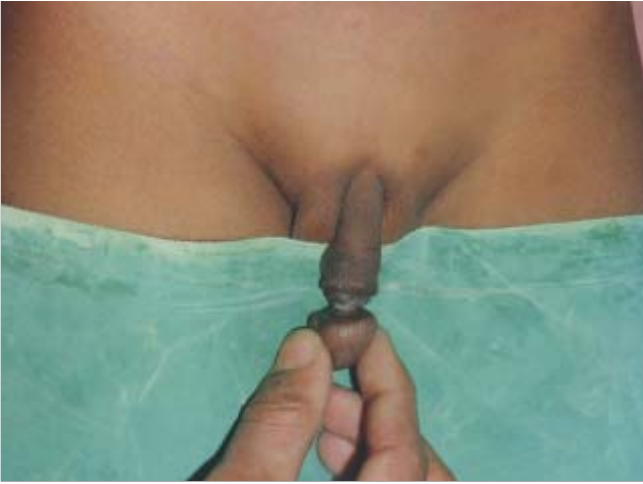appearance.

### CASE REPORT

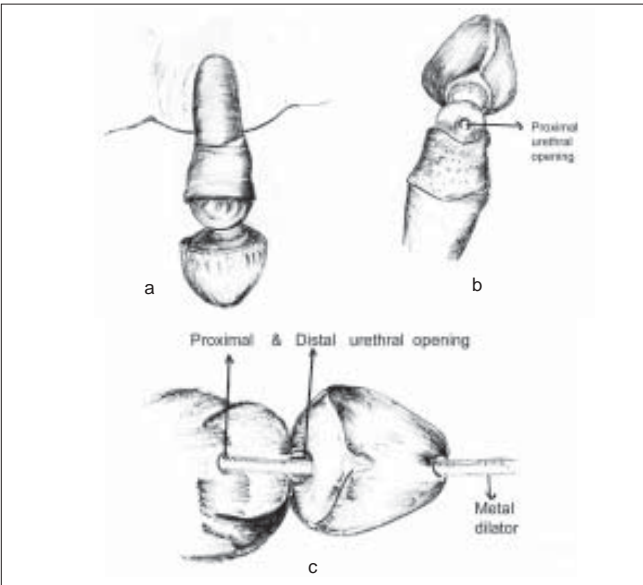
A 7-year-old male patient had history of continuous dribbling of urine since birth. He presented to us for deformity of the penis present since last 2 years. The patient was operated for meningomyelocele at the age of 6 months and had undergone circumcision at the age of one year.

On general examination the clothes were wet with strong foul smell of urine. A healed scar was present in the lumbosacral region.

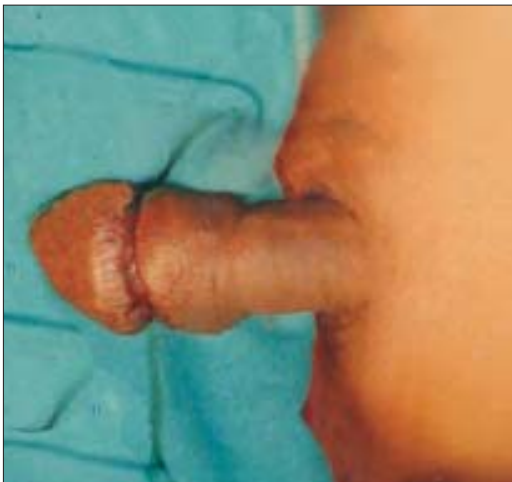The physical findings were localized to the penis. There was a deep circumferential groove at coronal sulcus and an almost amputated glans hanging on a pedicle from the penile shaft [Figure 1]. There was a urethral fistula deep in the sulcus [Figure 2]. On careful examination we found a deeply embedded hair in the groove with



**Figure 1:** Penis shows marked annular constriction at the level at coronal sulcus resulting to near total amputation of the glans with urethral fistula



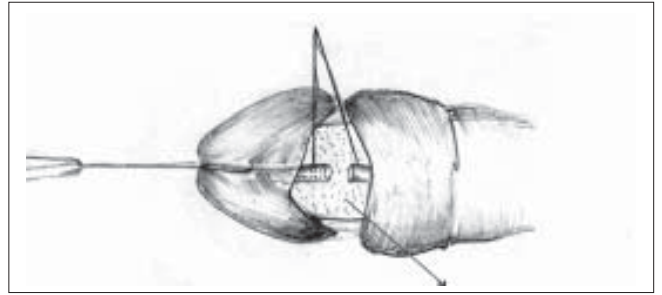
**Figure 2:** (a) Preoperative (dorsal view) shows near total amputation of glans penis. (b) Preoperative (ventral view). (c) Metal stent in proximal and distal urethral openings



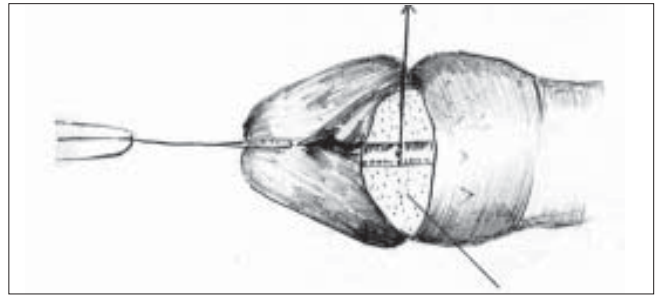
**Figure 3:** Shows postoperative result after single stage repair

necrotic debris. The meatal opening was in the normal position. The dribbling was determined to be of proximal neurological origin (meningomyelocele)

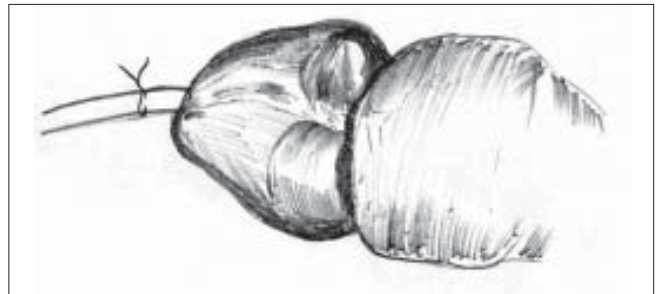
Reconstruction of the penis was done in a single stage. The coils of hair were unwrapped and nonviable tissue was debrided. The urethral fistula was closed with 6-0 vicryl sutures over a 10 Fr silicon catheter with refashioning of the grooved surface of glans [Figures 3-7] and apposing to each other for cosmetic reason. A



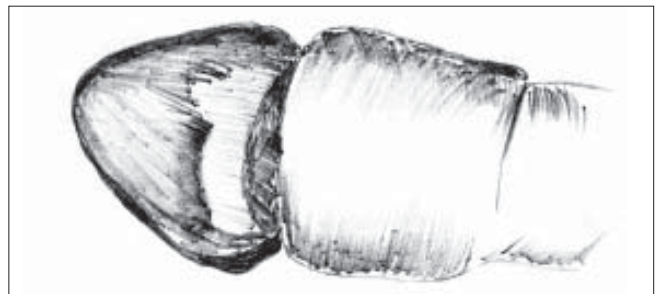
**Figure 4:** Proximal and distal urethral stump mobilised and surface of glans deepithelised



**Figure 5:** Urethral repair done



**Figure 6:** Postoperative (Ventral view)



**Figure 7:** Postoperative (Dorsal view)

short course of antibiotics (250 mg ampicillin 4 times daily) was given.

## DISCUSSION

Penile tourniquet injury probably is not a rare entity and has been reported following the application of the numerous foreign objects, including rings, rubber bands, bottles, pipes, pieces of cloth and threads. A frequently unrecognized and potentially devastating form of penile strangulation is that caused by human hair.

Penile strangulation secondary to human hair was first reported by Morgenstern in 1883.<sup>[1]</sup> Circumcision is an important predisposing factor (Jose *et al.*).<sup>[2]</sup> Alpert and associate<sup>[3]</sup> discussed the physical characteristic of human hair that makes it particularly harmful. Human hair is extremely thin and therefore easily overlooked, especially when there is a foreign body reaction and swelling. Furthermore, human hair stretches when wet and contracts and tightens as it dries. Hair has tensile strength of greater than 29,000 pounds per square inch. These characteristics make it an excellent agent for accidental or intentional constriction.

Basir and EL Barbary<sup>[4]</sup> reviewed important anatomical properties of penile shaft and correlated them to the progressive nature of the injury. The skin devoid of subcutaneous tissue and located most superficially, is affected first. The corpora spongiosum and urethra are covered by relatively thin layer of fibrous tissue and therefore are most susceptible to injury rather than corpora cavernosa which are covered by the tunica albuginea, a dense fibrous layer. As hair cut through ventral aspect of the penis the urethra may be transected, producing an urethrocutaneous fistula. The neurovascular bundle also may be injured.

Joel Sheinfeld *et al.*<sup>[5]</sup> described a case of penile strangulation by coil of hair and stress the importance of early diagnosis and managed conservatively.

William<sup>[6]</sup> reported a case of hair strangulation of glans

penis and reported two stage repairs.

Thatte *et al.*<sup>[7]</sup> reported 4 cases of unusual subtotal penile amputation in children and single stage repair with excellent cosmetic and functional results.

The method by which the hair is wrapped around the penis frequently is a matter of speculation. Application may be accidental or intentional by the patient, siblings, parents or other adults. There are several reports in the literature of parents wrapping hair around a penis in futile attempt to control enuresis. Thomas and associates addressed the psychosocial implication of this situation and alerts us to the possibility of child abuse.

## Management

In early cases removal of hair under general anesthesia and local wound care results in good healing. In more severe cases, corporal body or secondary urethral fistula needs repair.

## CONCLUSION

This uncommon case of near total amputation is presented to call attention to human hair as a potential source of injury in children and to demonstrate a successful one stage repair for this deformity.

## REFERENCES

1. Morgenstern J. Retention of urine and edema of the penis from constriction by hairs. *Pediatrics* 1888;5:284.
2. Jose R, Sotolongo Jr, Saul H. Penile denudation injuries after circumcision. *J Urol* 1985;132:102-3.
3. Alpert JJ, Filler R, Glaser HH. Strangulation of an appendage by hair wrapping. *N Eng J Med* 1965;273:866-7.
4. Bashir AY, El-Barbary M. Hair coil strangulation of the penis. *J Roy Coll Surg Edin* 1980;25:47-51.
5. Sheinfeld J, Cos L, Erturk E, Cockett A. Penile tourniquet injury due to a coil of hair. *J Urol* 1985;133:1042-3.
6. William J, MacClure, Gilbert P. Gradinager. Hair strangulation of the glans penis. *Plast Reconstr Surg* 1985;76:120-3.
7. Thatte RL, Wagh MS, Kulkarni ND. Identical unusual subtotal penile amputation in children: A report of four cases. *Br J Plast Surg* 1993;46:535-7.