

CASE REPORT

Esophagojejunal Anastomotic Leak Managed with Self Expandable Metallic Stent

Arvind Madurandagam Annapillai¹, Biggs Saravanan Ramachandran¹, Senthilkumar Ponniah¹, Hemamala V¹, Kesavan B, Premkumar Karunakaran¹, Prabhakaran Raju², Manoharan G², Chandramohan Servarayan Murugesan², Mohammed Ali Muhammed²

Department of ¹Medical and ²Surgical Gastroenterology, Rajiv Gandhi Government General Hospital, Madras Medical College (MMC), Chennai, India

ABSTRACT

Esophagealjejunal anastomotic leak after gastrectomy is a serious surgical emergency with high mortality. This report describes a 57-year-old male with esophagojejunal anastomotic leak following total gastrectomy for gastric cancer and was managed successfully with self-expandable metallic stent. To our knowledge this is the first such report from India. This case report highlights the need of interdisciplinary coordination in managing this difficult clinical situation. Endotherapy with self-expandable metallic stent (SEM) provided twin benefits of improving respiratory embarrassment and the joy of eating. Therapy of such difficult cases must be individualized; however, SEM stent usage is a viable option (*J Dig Endosc* 2013;4(1):13-15)

Key Words: Anastomotic leak - SEM stent - Endotherapy - Esophagojejunal leak

Introduction

Despite the advances in surgical techniques and improvements in peri-and-post-operative management, esophagojejunal anastomotic leak after total or proximal gastrectomy continues to be a serious problem. Intra-thoracic anastomotic leakage resulting from total gastrectomy and esophagojejuno-stomy are usually exclusively abdominal. Recently, placement of self-expandable metallic stents (SEMs) has emerged as an effective therapy for sealing the esophageal perforations and major anastomotic leaks after esophageal resection or total gastrectomy. Herein, we report a case of a patient who developed anastomotic leakage into the thoracic cavity after total gastrectomy and esophagojejuno-stomy for a biopsy proven growth of cardia (Siewert type III) and was successfully managed with endotherapy using SEM stent.

Case Report

A 57-year-old male was diagnosed to have growth in cardia (Siewert type III A),¹ biopsy proven adenocarcinoma. Total gastrectomy with esophagojejuno-stomy was done (postoperative stage III A). Patient developed respiratory distress on 2nd post-operative day. Chest X ray showed moderate left sided pleural effusion. Pleural fluid was turbid and amylase of 716 U/L suggested anastomotic leak. Patient had Glasgow Coma Score of 13/15 at this time. He also had tachycardia, tachypnea, diminished oxygen saturation, fever

Reprints requests and correspondence:

Dr. Arvind MA,
E 81, First Cross Street, Anna Colony, Besant Nagar,
Chennai 600090, India
Mobile - 9176120714, Landline - 044-24461623,
janardhananarvind@gmail.com

and a diminished air entry in left chest. Eight hundred ml of pleural fluid was drained. After insertion of intercostal chest drainage tube on left side (Figure 1).

Fluoroscopic oral contrast study confirmed leak into left thoracic cavity (Figure 2). Esophageal covered SEMS stent placement was done under monitored anesthetic control (MAC) (Figure 3). Patient's general condition improved and he tolerated oral feeds by 20th post-operative day. Thus SEM stent by obliterating the anastomotic leak improved respiratory embarrassment and restored joy of eating.

the clinical outcome (Figure 4). SEM stent seals leakage in 90% of cases and allows oral feeding to resume. SEP stent has the advantage of retrievability but migration rate is higher although a recent case series showed good outcomes with a lesser migration rate.¹⁰

Conclusion

Use of SEM stent is an accepted treatment modality in selected cases of upper GI anastomotic leaks especially post esophagectomy leaks. Our case has shown that use of SEM

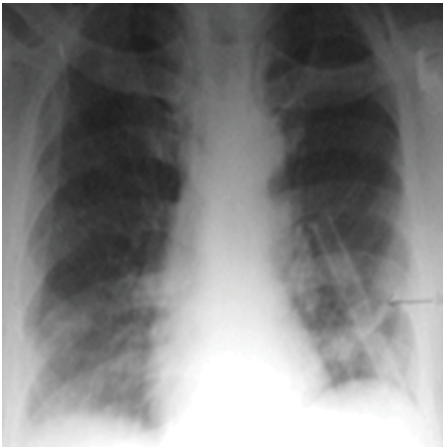


Figure 1

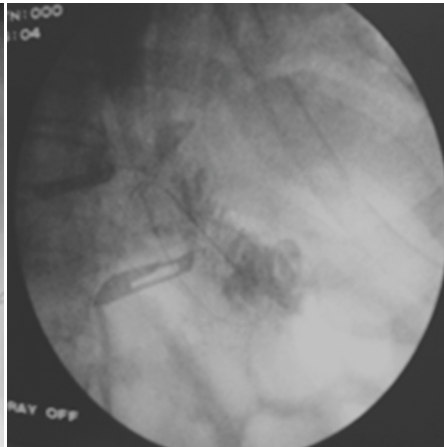


Figure 2

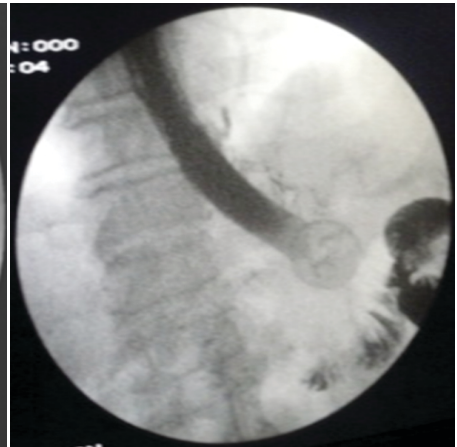

Figure 3

Discussion

An abdominal leak after esophagojejunal anastomosis is expected but intra thoracic leak occurs rarely. There have only been few individual case reports and case series of 2-4 cases in worldwide literature. Theoretically, this rare complication is believed to be due to increased tension in the anastomosis as a lesion high in the stomach is resected with esophagus being dragged down for anastomosis with jejunum. Esophagus retracts back into the thorax in post surgery period and therefore, anastomotic dehiscence presents as leak into the pleural cavity. Thus, ischemia coupled with high tension in the anastomosis is postulated mechanism in such leaks. Early leaks require urgent emergent interventions. The treatment options available include repeat surgery and endotherapy. Endo therapeutic options include placement of SEM or self-expandable plastic (SEP) stent, and application of fibrin glue or clips. There is no consensus opinion regarding management. Treatment must be individualized. Surgical therapy is reserved for patients with gross mediastina/pleural soilage and is associated with high morbidity and mortality,²⁻⁴ ranging from 3-25 mm.⁵ Endoscopic application of fibrin glue has been shown to be of benefit in case reports.⁶ There have been case reports of use of SEM stent in such leaks with definite success.⁷⁻⁹ Yong Gang *et al* also showed that small reflux of the intestinal fluid into the thoracic cavity can still occur along the sides of the SEM stent even after the leak site is bridged although it does not affect

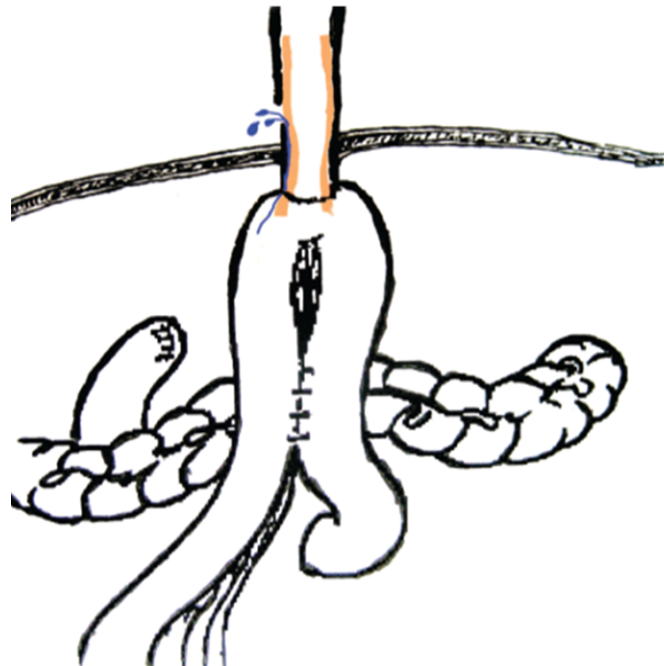


Figure 4: Showing reflux of intestinal fluid into the thoracic cavity. The blue color indicates that the refluxed intestinal fluid could leak from the gap between the stent (brown color) and the jejunal wall to the thoracic cavity through the orifice

stent in total gastrectomy and esophagojejunal anastomotic leak has dramatically improved general condition of the patient and also restored the joy of eating thus providing twin benefits. This is the first case of SEM stent use in esophagojejunal anastomotic dehiscence being reported from India.

References

1. Classification of adenocarcinoma of the esophagogastric junction. *Br J Surg* 1998;85:1457-9.
2. Alanezi K, Urschel JD. Mortality secondary to esophageal anastomotic leak. *Ann Thorac Cardiovasc Surg* 2004;10:71-5.
3. Kakavoulis TN, Avgoustou CC, Koniaris HG, Penlidis PC. Subcutaneous esophagojejunal reconstruction in the management of esophagogastric anastomotic leak: a staged procedure. *Dis Esophagus* 2005;18:345-8.
4. Lang H, Piso P, Stukenborg C, Raab R, Jähne J. Management and results of proximal anastomotic leaks in a series of 1114 total gastrectomies for gastric carcinoma. *Eur J Surg Oncol* 2000;26:168-71.
5. Qadeer MA, Dumot JA, Vargo JJ, Lopez AR, Rice TW. Endoscopic clips for closing esophageal perforations: case report and pooled analysis. *Gastrointest Endosc* 2007;66:605-11.
6. Truong S, Bohm G, Klinge U, Stumpf M, Schumpelick V, et al. Results after endoscopic treatment of postoperative upper gastrointestinal fistulas and leaks using combined Vicryl plug and fibrin glue. *Surg Endosc* 2004;18:1105-8.
7. Yonggang LV, Shifang Yuan, Jun Yun, Qing Yao, Jianghao Chen, Jun Yi, Rui Ling, Ling Wang. Management of intrathoracic leakage after radical total gastrectomy. *J Thorac Dis* 2010;2: 180-84.
8. Profili S, Feo CF, Cossu ML, Scanu AM, Scognamillo F, Meloni F, et al. Effective management of intrathoracic anastomotic leak with covered self-expandable metal stents. Report on three cases. *Emerg Radiol* 2008;15:57-60.
9. Kauer WK, Stein HJ, Dittler HJ, Siewert JR. Stent implantation as a treatment option in patients with thoracic anastomotic leaks after esophagectomy. *Surg Endosc* 2008;22:50-3.
10. Fernández A, Vila JJ, Vázquez S, González-Portela C, de la Iglesia M, Lozano M, Toscano E. Self-expanding plastic stents for the treatment of post-operative esophago-jejuno anastomosis leak. A case series study. *Rev Esp Enferm Dig* 2010;102:704-10.

Source of support: Nil; Conflict of interest: none declared