

## Case Report

# Familial distichiasis

**Siti Roy Chowdhury, Shamita Chatterjee<sup>1</sup>**

Dr. B. N. Basu Memorial Clinic, Kolkata, India, <sup>1</sup>R. G. Kar Medical College and Hospital, Kolkata, India

**Address for correspondence:** Dr. Siti Roy Chowdhury, 7 Bepin Pal Road, Kolkata - 700 026, India. E-mail: sitirc@sify.com

### ABSTRACT

Congenital familial distichiasis is a rare condition usually accompanied by other symptoms. Isolated familial distichiasis is rarely heard of. Various modalities of treatment have been tried over the years. We present a case of familial distichiasis spanning over three generations. Our patient was treated with eyelid splitting and follicular extirpation with bipolar cautery. At two years follow-up, there is no recurrence of the distichiatic lashes, with excellent functional and cosmetic result.

### KEY WORDS

Eyelid surgery, familial distichiasis

### CASE REPORT

A 20-year-old male patient presented with complaints of recurrent reddening and sticky discharge from the left eye. There was severe pain in the eyes on and off. The patient also complained of diminished vision in the left eye since childhood.

On examination, it was found that he had bilateral upper and lower eyelid distichiasis with congenital cataract of the left eye [Figure 1]. The accessory rows of upper and lower eyelashes were turned inwards in the left eye and were abrading against the conjunctiva and cornea, leading to conjunctival irritation and corneal ulceration. But in the right eye, the accessory row of eyelashes, though present, were not turned inwards to graze against the conjunctiva and cornea and were hence, asymptomatic. Assessment of ophthalmic status revealed high myopia (6/24) of the right eye. The left eye, which had congenital cataract, had no perception of light.

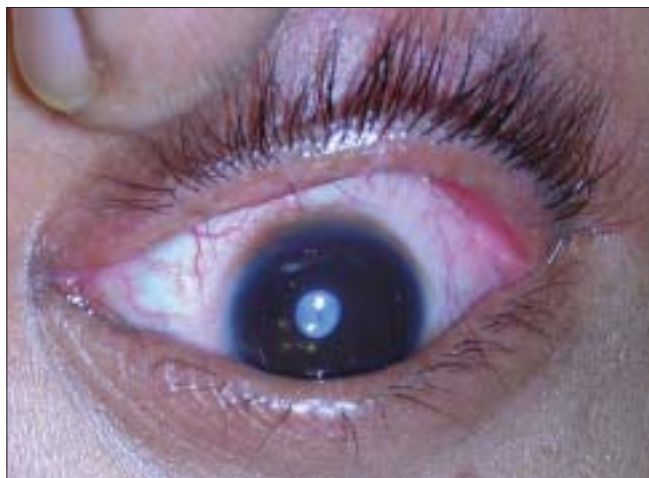Further enquiry revealed that there were other members in his family, who had similar complaints [Figure 2]. His younger brother also had bilateral distichiasis of both

the upper and lower eyelids, but was asymptomatic. His mother had bilateral upper eyelid distichiasis only and was also asymptomatic. His maternal aunt and both her male children suffered from distichiasis. Both the male children had bilateral lower lid distichiasis and were symptomatic. Our patient's maternal grandmother had bilateral upper and lower eyelids involved, but was asymptomatic.

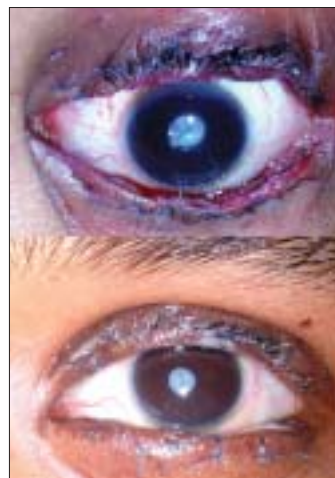The patient had started receiving treatment since the age of four years. Electrolysis was done every one to two years. But there was recurrence within months, leading to chronic irritation with chronic conjunctivitis and corneal irritation. Between 2002 and 2004, he underwent multiple sittings of lid margin cryotherapy, but with recurrence within two months of each sitting.

It was realized that the patient required some form of treatment which would give him long-term relief. Moreover, till the distichiasis was treated, management of the congenital cataract would not be very beneficial.

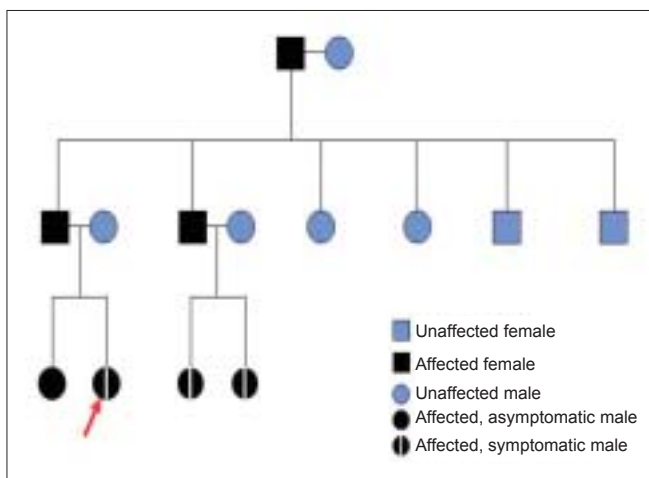
The patient was taken up for surgery, in which, the eyelid was split using the gray line incision i.e. immediately



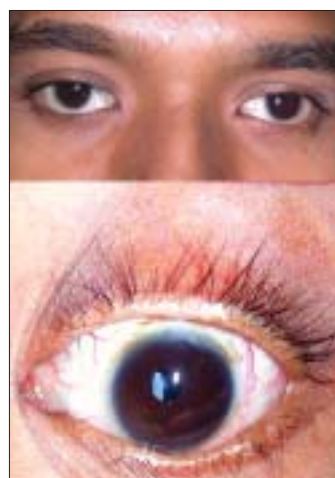**Figure 1:** Photograph of the left eye showing distichiasis eyelashes in contact with the conjunctiva and the cornea



**Figure 3:** Immediate postop picture (top) and two weeks follow-up picture (bottom) showing good healing of lid margin



**Figure 2:** Family tree representing three generations of affected individuals. Arrow indicates the index patient



**Figure 4:** Two years follow-up

anterior and parallel to the abnormal eyelash line. Full height of the tarsus was exposed to gain access to the bases of the inner layer of lashes. The improperly directed ones were cauterized using a bipolar diathermy. Ultimately, the skin and muscle layer was sutured to the anterior face of the tarsus. Within two weeks there was good healing of the eyelid margin [Figure 3].

Four months later, the congenital cataract was treated by intraocular lens implantation.

At two years follow-up, the patient has no conjunctivitis or corneal ulceration. There is no recurrence of the distichiasis lashes and there is complete preservation of the normal eyelashes [Figure 4]. There is improved perception of light in the left eye.

## DISCUSSION

Distichiasis is a rare congenital or acquired eyelid anomaly in which an accessory row of eyelashes arise from the openings of the meibomian glands or near them. The abnormal cilia are posterior to the normal row of cilia. If congenital, it is an autosomal dominant developmental anomaly. The condition may involve a few lashes or the entire lid margin. In acquired distichiasis, the accessory row of lashes occurs as a result of conditions such as Steven-Johnson syndrome, ocular pemphigoid or chemical and physical injuries.

Distichiasis by itself is a rare condition. Incidence of multiple cases of distichiasis in a family, spanning over three generations, is even rarer. When multiple cases in

a family occur, they may be accompanied by lower limb lymphedema.<sup>[1]</sup> Other deformities associated with this syndrome are strabismus, pterygium coli and partial ectropion of the lower lid. There may be vertebral anomalies and spinal extradural cysts. In our case, none of these other anomalies were present.<sup>[2]</sup>

Distichiasis may not necessarily produce symptoms. Symptoms like reddening, watering from the eyes, discharge from the eyes and pain leading to complications like conjunctivitis, corneal irritation and corneal ulcers may be produced only if the accessory eyelashes are turned inward and abrade the eye. Histological examination demonstrates that the aberrant lashes result from a metaplasia of tissues in or around the meibomian glands.

Various modalities of treatment have evolved over a period of time for the management of distichiasis. Epilation is the most basic treatment, but has a very high rate of recurrence. Lid margin cryotherapy or eyelid splitting and cryotherapy to the posterior lamella are also commonly done,<sup>[3,4]</sup> but again has high incidence of recurrence. Folliculectomy, with anterior lamellar resection may be done, but complications like trichiasis, loss of normal eyelashes, cicatricial entropion and eyelid margin deformities may occur. Other options include eyelid splitting with excision or microhyfreaction<sup>[5]</sup> and eyelash trephination.<sup>[6]</sup> Our experience while doing an eyelid splitting and follicular extirpation with a bipolar diathermy proved to be quite rewarding with not only excellent result at two year follow-up but also very good cosmesis. Use of bipolar diathermy for the above procedure is yet to be reported in literature. Some prefer

to do the same surgery with a monopolar cautery,<sup>[7]</sup> but cosmesis is not as rewarding.

## CONCLUSION

Thus, familial distichiasis with no other associated anomalies is a very rare pathology. This requires early commencement of treatment to reduce complications. Most modalities of treatment have a very high rate of recurrence. Eyelid splitting and follicular extirpation using bipolar diathermy is a simple yet effective modality of treatment, with very low rate of recurrence.

## REFERENCES

1. Hoover RE, Kelley JS. Distichiasis and lymphedema: A hereditary syndrome with possible multiple defects. A report of a family. *Trans Am Ophthalmol Soc* 1971;69:293-306.
2. Patil BB, Bell R, Brice G, Jeffery S, Desai SP. Distichiasis without lymphoedema? *Eye* 2004;18:1270-2.
3. Anderson RL, Harvey JT. Lid splitting and posterior lamella cryosurgery for congenital and acquired distichiasis. *Arch Ophthalmol* 1981;99:631-4.
4. O'Donnell BA, Collin JR. Distichiasis: Management with cryotherapy to the posterior lamella. *Br J Ophthalmol* 1993;77:289-92.
5. Vaughn GL, Dortzbach RK, Sires BS, Lemke BN. Eyelid splitting with excision or microhyfreaction for distichiasis. *Arch Ophthalmol* 1997;115:282-4.
6. McCracken MS, Kikkawa DO, Vasani SN. Treatment of trichiasis and distichiasis by eyelash trephination. *Ophthal Plast Reconstr Surg* 2006;22:349-51.
7. Chi MJ, Park MS, Nam DH, Moon HS, Baek SH. Eyelid splitting with follicular extirpation using a monopolar cautery for the treatment of trichiasis and distichiasis. *Graefes Arch Clin Exp Ophthalmol* 2005;1-4.

**Source of Support:** Nil, **Conflict of Interest:** None declared.