

Original Article

What is the best choice for repair of distal penile hypospadias: The tubularized incised plate urethroplasty or anterior urethral advancement technique?

Mohamed M. S. Awad, Adel M. Tolba, Khaled M. Saad*, Mahmoud R. Zaghlol*, Ahmed Ezzat Rozigque*, Osama H. Gharib*, Saalim A. Khalil**

Plastic Unit, *Pediatric Unit, Surgical Department and **Pediatric Unit, Surgical Urology Department, Zagazig University Hospitals, Egypt Zagazig, Egypt

Address for correspondence: Mohamed M. S. Awad, Plastic Unit, Surgical Department, Zagazig University Hospitals, Egypt Zagazig, Egypt.
E-mail: dadlahm@yahoo.com

ABSTRACT

Background and Aim: Numerous ingenious methods have been introduced to repair hypospadias with variable results. We tried to evaluate the two techniques, tubularized incised plate urethroplasty (TIP) and anterior urethral advancement (AUA) for repair of distal hypospadias and choose the best method to treat the distal type of penile hypospadias with the least complications. **Materials and Methods:** A total of 140 boys with distal penile hypospadias were divided into two groups. Group A (68 patients) was treated with TIP and Group B (72 patients) was treated with AUA. All the patients had an average age of three years (2-19) with variable meatal sites coronal (44) sub coronal (53) and anterior penile hypospadias (43). There was no significant difference between both groups with respect to the age and meatal sites. **Results:** The fistula rate in Group A was 8.8% versus 1.3% in Group B. There was no urethral stricture in both procedures. Wound dehiscence did not occur in Group A versus one case in Group B (1.3%). In Group A, 26 cases (38.3%) had mild glanular torsion and five (7.3%) had moderate glanular torsion versus none in Group B postoperatively. No postoperative chordee or binding in Group A, versus four patients (5.5%) in Group B. No significant difference was observed in both groups with respect to meatal stenosis (7.3% versus 5.5% respectively). There was a significant difference between both groups with regard to the operative time in favour of Group B. Good cosmetic appearance of the glans was achieved in both techniques. **Conclusion:** Both techniques can treat this anomaly with a high success rate but the modified AUA technique appears to be a good choice due to its simplicity, short operative time and less fistula rate with good cosmetic results.

KEY WORDS

Advancement, choice, hypospadias, urethra

Hundreds of procedures have been introduced to repair hypospadias with variable results. The distal penile hypospadias is the most common site of this anomaly (75%).^[1] Urethrocutaneous fistula is the most common complication after hypospadias repair with an incidence of 10-15%, that has been treated successfully using a variety of techniques.^[2] Our study evaluates both techniques, AUA and TIP for repairing of

the distal penile anomaly in order to choose a technique which produces less trauma, fewer complications and creates a nearly normal urethra.

MATERIALS AND METHODS

A total of 140 boys, with a mean age of approximately three years, [range from 2 to 19 years], were treated in our

department during the period between March 2003 and December 2004 for distal hypospadias. They had no history of previous hypospadias repair; and the preoperative meatal sites were coronal in (20, 24), subcoronal in (25, 28) and ant. Penile hypospadias in (23, 20) patients. Figures in brackets refer to the number in each of the two groups. The mean age was 2.4 years [range 2-19] and 2.8 years [range 2-18] in both groups respectively.

The operations were done by any of the surgeons in our department in a random fashion with no bias of surgeon or procedure. In 12 cases [7 and 5 in the two groups] chordee was associated in both groups respectively, nothing was done to treat the chordee in any patients and in 110 patients, [47 and 63] they were non-circumcised [Table 1].

Surgical technique

Both procedures were performed under general anaesthesia; we did not prefer the caudal type as it may be associated with a higher incidence of bleeding in our experience. The general principles of repair for all our patients included minimal use of cautery, avoidance of tension on the repair, use of loupe magnification but not the operating microscope.

Patients in Group A [n = 68] were treated as originally described by Snodgrass (1994), by tubularized incised plate urethroplasty.^[3]

A well-vascularised dartos fascia flap from the prepuce was used to cover the neourethra as a barrier in non-circumcised boys and from the dorsal shaft in circumcised boys.

Group B [n = 72] patients were treated with anterior urethral advancement technique (AUA) as originally

described by TI Chang Ching.^[4] We had three modifications to facilitate the technique.

The first, starting dissection of the urethra from its middle aspect rather than anteriorly as described originally, the second modification was tangential cutting of the distal 2mm of the urethra more toward the posterior aspect associated with 2 mm excision of the distal tip, the third was a vertical glanular slit by the blade of the knife before tunnelling the urethra into the glans. Finally the catheter was kept as a stent in all patients and removed after 48 h. Systematic postoperative analgesic treatment (paracetamol oral 15 mg/kg_four times a day) was given on a regular basis during the first two or three days, complemented if necessary with nalbuphine (0.2 mg/kg IV) during the first hours after the procedure. The follow-up period ranged from six to 12 months with a mean 7.4 months. Figures 1-8 show the intraoperative details of both techniques.

RESULTS

Retention

Four and seven boys (5.8%), (9.7%), in both groups respectively, suffered from postoperative urinary retention. Only one patient in Group B requiring bladder drainage, the other patients required hot fomentation and analgesic only. None of these children later developed meatal stenosis or fistula through the follow-up period.

Fistula and wound dehiscence

In Group A urethrocutaneous fistula was observed in six boys (8.8%), the fistulae were diagnosed at two to eight weeks postoperatively. Two fistulae were small and successfully healed conservatively and in the remaining four, the fistulae were large and redo procedures were needed to treat them. No wound dehiscence was observed in Group A. One of the patients in Group B developed a big fistula [1.3%], in which the urethra was retracted to its primary site due to bad postoperative management and wound infection followed by wound dehiscence and cut-through.

Meatal stenosis

Meatal stenosis occurred in five children in Group A (7.3%) versus patients, (5.5%), in Group B. Urethral dilatation twice weekly for three weeks without anaesthesia, relieved the symptoms and none of these children developed fistula in both groups. The stenosis was

Table 1: Preoperative patient characteristics

Preoperative characteristics	TIP (n=68)	AUA (n=72)	Total (n= 40)
Age (years)			
2-<5	25	32	57
5-8	22	25	47
<8	21	15	36
Meatal site			
Coronal	20	24	44
Subcoronal	25	28	53
Ant. penile	23	20	43
Chordee			
With	7	5	12
Without	61	67	128
Circumcision			
Non-circumcised	47	63	110
Circumcised	21	9	30

TIP - Tubularized incised plate, AUA - Anterior urethral advancement

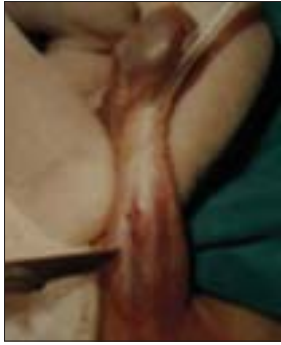

Figure 1: Starting urethral dissection from its middle [AUA]

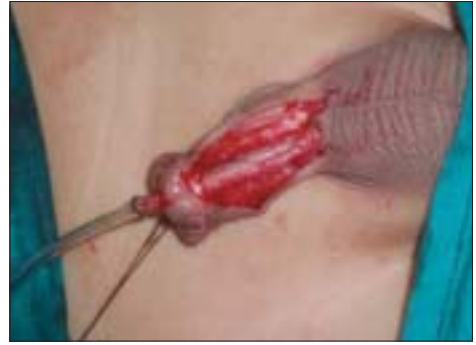

Figure 5: Tunneling the urethra within the glans [AUA]

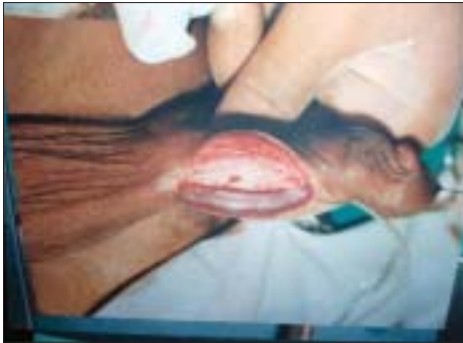

Figure 2: Complete urethral dissection including its corpora [AUA]

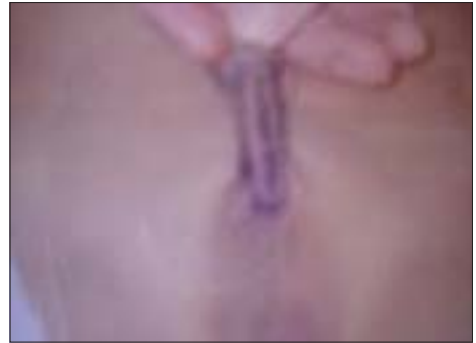

Figure 6: Preoperative marking of the midline and U shaped incisions [TIP]

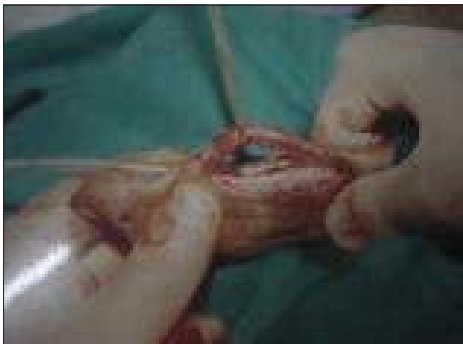

Figure 3: Middle urethral elevation [AUA]

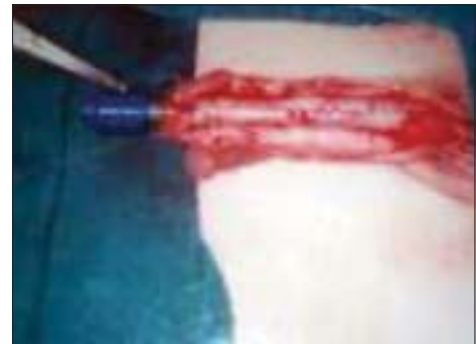

Figure 7: Intraoperative picture after urethral tubularisation

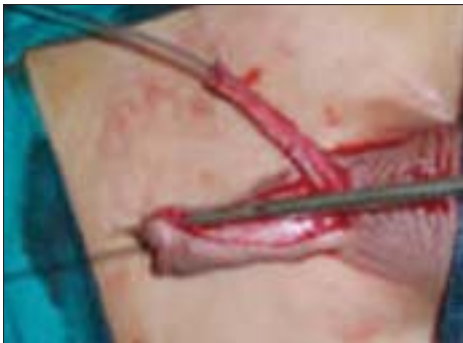

Figure 4: Making vertical meatus with the blade of the scalpel [AUA]

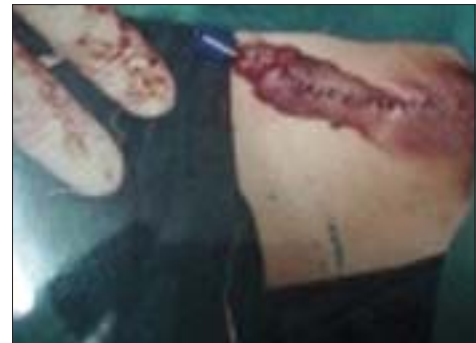

Figure 8: Tubular-shaped glans after TIP

noticed by disturbed and painful urinary flow, usually after two to eight weeks postoperatively and we started the urethral dilatation after one month to allow proper healing and urethral fixation.

Glanular torsion and postoperative binding

This was noted in most patients in Group A [TIP], with either left or right lateral rotation with variable degrees. It was mild in 26 patients (38.2%) slightly noticed by the patients or parents and moderate in five patients (7.3%) easily noticed by the parents. In Group B ventral binding occurred in four [5.6%] patients, nearly all self corrected within four to eight months postoperatively, this slight binding was due to urethral stretching [Table 2].

The operative time

The time of operation was calculated after completion of induction of anaesthesia until complete dressing. In Group A it ranged from 50-90 min with an average time of 70 min and in Group B from 30-50 min with an average of 45 min [Table 3].

Cosmetic appearance

A vertically slit meatus with conical glanular shape and direct urinary stream is the final good result which we hope to obtain, angled urinary stream and oval or round-shaped meatus with regressed glans are satisfactory cosmetic results [Figures 9-15]. In Group A, 58 patients (85.2%) had good results versus 62 (86.1%) patients in Group B [Table 4].

Table 2: Early postoperative results in both groups

Post complications	TIP	AUA
Urinary retention	4 (5.8)	7 (9.4)
Urethral fistulas	6 (8.8%)	1 (1.3%)
Urethral stricture	5 (7.3%)	4 (5.5%)
Dehiscence	0	1 (1.3%)
Meatal stenosis	5 (7.3%)	4 (5.5%)
Glanular rotation		
Mild (unnoticed)	26 (38.2%)	0
Moderate (noticed)	5 (7.3%)	
Ventral binding	0	4 (5.6%)

TIP - Tubularized incised plate, AUA - Anterior urethral advancement

Table 3: Operative time in both techniques

Operative time (min)	TIP (no) (patients)	AUA (no) (patients)
30-50	2	45
50-70	38	20
70-90	21	7
>90	5	0
Average time	75	45

TIP - Tubularized incised plate, AUA - Anterior urethral advancement

DISCUSSION

There are hundreds of procedures described for repair of hypospadias, almost none of these procedures can be universally applied for all hypospadias types, some are suitable for distal and some are suitable for various degrees of proximal hypospadias.^[5] The presence or absence of chordee can also determine the suitability of various procedures. Within the presence of this plethora of techniques, we needed to clearly mark a realistic goal and to follow a protocol to evolve a guideline on the management of hypospadias. This protocol aimed to make as nearly normal a urethra as possible in such patients, in the least traumatic manner, with the least number of complications and a good cosmetic appearance. In general for all our patients in both groups we used a loop magnification to do both procedures and stented the patients for one week. Several studies have emphasized the need for magnification and its correlation with a successful outcome.^[6] Some authors have published that no statistically significant difference in outcome was observed for stented versus unstented patients. Leclair *et al.*^[7] published that absence of urethral stent after TIP urethroplasty for distal hypospadias repair does not seem to increase postoperative complication rate. Danie *et al.*^[8] used stents for complex repairs, with no statistically significant difference in outcome for stented versus unstented patients.

We stressed in this work, four criteria for hypospadias management. The *first* was regarding the indications for both techniques. The TIP operation has a wide range of indications in that it can be done for primary and recurrent hypospadias and for distal, mid-penile and even proximal hypospadiac patients,^[9] versus AUA technique which has a limited indication for coronal, subcoronal and anterior penile with a maximum distance of about

Table 4: Late postoperative results and cosmetic appearance

	TIP (n=68) %	AUA (n=72) %
Cosmetic appearance	58	62
Good.		
Direct urinary stream	(85.2)	(86.1)
Conical-shaped glans		
A slit vertical meatus		
Satisfactory results		
Angled stream	10	10
Regressed glans	(14.8)	(13.9)
Oval or rounded meatus		
Urethral fistula	4(5.8)	1(1.3)

TIP - Tubularized incised plate, AUA - Anterior urethral advancement

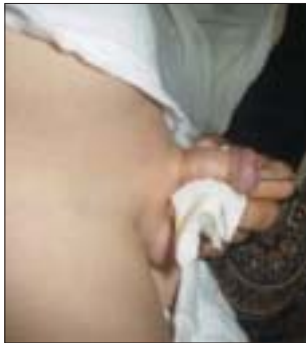

Figure 9: Postoperative picture after one and half years with direct urinary stream [AUA]

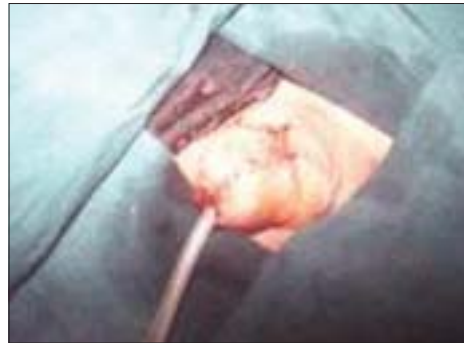

Figure 13: Good cosmetic appearance, conical shaped glans, after [TIP]

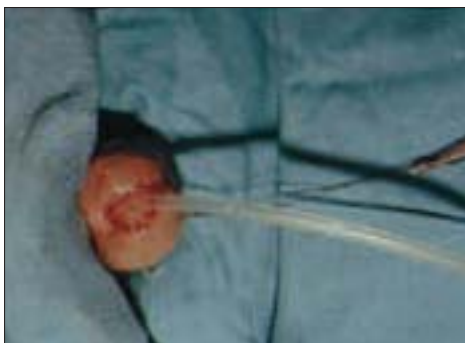


Figure 10: Immediate postoperative picture of the glans and meatus after [AUA]



Figure 14: Postoperative picture after one and half years with direct urinary stream [TIP]



Figure 11: Good cosmetic appearance, conical shaped glans, after [AUA]



Figure 15: Good postoperative picture one and half years with slight left sided angulation [TIP]

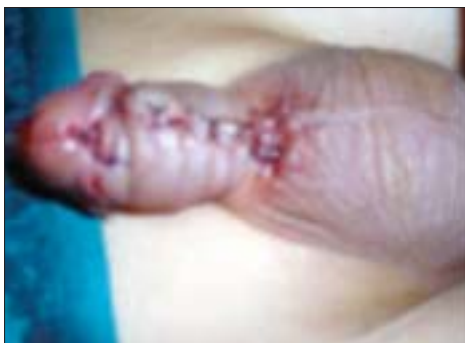

Figure 12: Immediate postoperative picture after with slight ventral binding [AUA]

1.5 cm as reported by El Saadi *et al.*^[10] As a realistic goal, to create a nearly normal urethra, we believe that AUA operation is the most optimum technique, as the urethra itself is mobilized within its corpus spongiosum until the neomeatus and no one is able to create a urethra like the naturally formed urethra. Also, the TIP operation may need an expert surgeon for tubularisation of the neourethra and its calibration, it may also decrease the chance for repeat operation due to previously incised urethral plate versus AUA that does not affect the urethral plate. There is however contrary data published by Elicevik *et al.*^[11]

They have shown that the previously incised urethral plate appeared normal without any obvious scar failure after TIP operation. In our opinion AUA procedure is superior to TIP for the same meatal site. The *second goal* is to choose the less traumatic approach. The TIP operation is a more traumatic technique than AUA. It needs a complete degloving of the penis, an incision of the urethral plate and the use of the dartos fascia as a barrier layer; all these steps are bloody and need more operative time. Against this the AUA technique needs only urethral dissection and tunnelling of the glans after skin incision. Thus, in our study we observed a significantly shorter operative time for AUA operation the *third goal* is to achieve a procedure of least complications. Meatal stenosis in our study was a less common event in both groups without a significant difference (7.3% and 5.5% respectively). To avoid meatal stenosis in the AUA operation, we incised the distal end of the urethra for a distance of about 2 mm from its posterior aspect, then fixed the urethra at three sites. We also cut the distal 2 mm of the urethra as it is a fibrotic part, has no urothelium and may cause a postoperative meatal stenosis or even wound sloughing. Some authors claimed that the incidence of fistula and stricture may be caused by suture types or technical failure and thus it can be avoided;^[12] others believed that the use of a dartos flap to cover the neourethra reduces the risk of fistula development from 4.7% to 1.6%.^[13] But if the preputial dartos flap is not available, as is the case for circumcised boys or those undergoing reoperation, approximation of adjacent tissues alongside the neourethra is not an adequate substitute.^[14]

One of the difficulties in doing the TIP operation is the absence of the preputial flap that is of high rate of fistula versus the AUA technique which doesn't depend on the preputial flap. Even the use of dartos flap as a third layer is controversial. Elbakry^[15] argued that the dartos flap should not be used because it hinders tension-free closure of the glans flaps and increases the risk of glanular dehiscence but Kamal^[16] published that dehiscence in the presence of the dartos flap is a rare complication.

From the incidence of fistula in our study in both techniques, 8.8% and 1.3% in TIP and AUA operations respectively, it is clear that there is a higher incidence of fistula after TIP versus AUA as the AUA technique is devoid of any line of anastomosis, thus this complication was avoided except in one patient who had suffered from wound dehiscence, due to wound infection. Some authors like

Elicevik *et al.*^[11] claimed that this high incidence of fistula after TIP operation was attributed to the high incidence of postoperative meatal stenosis or a narrow neourethra after TIP operation. They reported an incidence of 8% fistulae and 7% meatal stenosis in their study.

We had no postoperative urinary retention in both groups except for weak urinary flow and painful micturition in four (5.8%) and seven (9.4%) patients respectively after catheter removal with no effect on surgical outcome. This agrees with the published results by Leclair *et al.*^[7] but with 2.5% incidence of retention, Conversely, El-Sherbiny (2003) showed that the absence of stent in toilet-trained children was associated with a 24% rate of urinary retention and a high re-operation rate.^[17]

Finally, the *fourth goal*, i.e. the cosmetic appearance after both techniques. With good preoperative planning to evaluate the actual distance of advancement of the neomeatus and good urethral dissection we had a good conical-shaped glans, a slit-like meatus and a well directed urinary stream without chordee or angulations that was noticed in patients after TIP operation. Also, the glans was more bulky in the AUA group as we added urethral tissues to it, versus the other group that was more tubular and less bulky as we created a urethral tube from within the glans. The glanular angulations due to application of the dartos flap may be corrected by some authors through the use of double dartos flaps Kamal,^[16] One of the most expected complications after AUA operation is the ventral binding of the penis when the urethra is forcibly drawn to the tip of the glans without proper measuring of the urethral length, but all were self-corrected within the period of follow-up, as we mentioned previously.^[18]

CONCLUSION

Anterior urethral advancement with our modifications is the first choice to treat distal penile hypospadias, especially in circumcised and recurrent cases as it has a less fistula rate, less trauma rate and less operative time with a good cosmetic results but a bulkier glans.

REFERENCES

1. Latifoglu O, Yavuzer R, Unal S, Cavusoglu T, Atabay K. Surgical treatment of urethral fistulas following hypospadias repair. *Ann Plast Surg* 2000;44:381-6.
2. Shankar KR, Losty PD, Hopper M, Wong L, Rickwood AM. Outcome of hypospadias fistula repair. *BJU Int* 2002;89:103-5.

3. Snodgrass W. Tubularized, incised plate urethroplasty for distal hypospadias. *J Urol* 1994;151:464-5.
4. Chang TS. Anterior advancement a one stage technique for hypospadias repair. *Br J Plast Surg* 1984;37:530.
5. Landau EH, Gofrit ON, Meretyk S, Katz G, Golijanin D, Shenfeld OZ, *et al.* Outcome analysis of tunica vaginalis flap for the correction of recurrent urethrocutaneous fistula in children. *J Urol* 2003;170:1596-9.
6. Masterson JS, Johnson HW, Coleman GU, Ettinger SL, McLoughlin MG. The development of microsurgical techniques in experimental and clinical repair of urethrocutaneous fistulas. *J Urol* 1982;128:285-6.
7. Leclair MD, Camby C, Battisti S, Renaud G, Plattner V, Heloury Y. Unstented tubularized incised plate urethroplasty combined with foreskin reconstruction for distal hypospadias. *Eur Urol* 2004;46:526-30.
8. Snyder CL, Evangelidis A, Hansen G, St Peter SD, Ostlie DJ, Gatti JM, *et al.* Management of complications after hypospadias repair. *Urology* 2005;65:782-5.
9. Nguyen MT, Snodgrass WT. Tubularized incised plate hypospadias reoperation. *J Urol* 2004;171:2404-6.
10. El Saadi MM. Anterior urethral advancement technique for repair of hypospadias Modifications. *Zagazig Med Assoc J* 2001;2:24-6.
11. Elicevik M, Tireli G, Sander S. Tubularized incised plate urethroplasty: 5 years' experience. *Eur Urol* 2004;46:655-9.
12. Elbakry A. Tubularized-incised urethral plate urethroplasty: Is regular dilatation necessary for success? *BJU Int* 1999;84: 683-8.
13. Snodgrass WT. Re: Effect of the depth and width of the urethral plate on tubularized incised plate urethroplasty. *J Urol* 2001;166:633.
14. Snodgrass W, Koyle M, Manzoni G, Hurwitz R, Caldamone A, Ehrlich R. Tubularized incised plate hypospadias repair: Results of a multicenter experience. *J Urol* 1996;156:839-41.
15. Elbakry A. Further experience with the tubularized-incised urethral plate technique for hypospadias repair. *BJU Int* 2002;89:291-4.
16. Kamal BA. A double dartos flaps in tubularized incised plate hypospadias repair. *Urology* 2005;66:1095-8.
17. El Sherbiny MT. Tubularized incised plate repair of distal hypospadias in toilet trained children: Should a stent be left? *BJU Int* 2003;92:1003-5.
18. Awad MS. Urethral advancement technique for repair of distal penile hypospadias: Revisit. *Indian J Plast Surg* 2006;39:48-53.

Source of Support: Nil, **Conflict of Interest:** None declared.