

Original Article

Management of unresolved hemangiomas and venous malformations by N-butyl cyanoacrylate

Ashim Kumar Roy, Bijay Kumar Majumdar, Saswati Majumdar*

Departments of Plastic Surgery and *Pathology and Microbiology, Institute of Postgraduate Medical Education and Research and S.S.K.M. Hospital, Kolkata, India

Address for correspondence: Dr. Bijay Kumar Majumdar, E 303, OXFORD VIEW, 32/36, D.H. Road, Kolkata - 700 008, India.
E-mail: bijaykumar_majumdar@yahoo.co.in

ABSTRACT

Management of unresolved hemangiomas and venous malformations is a real challenging problem because of their grotesque nature and aesthetic considerations. In our study we have used percutaneous injection of N-butyl cyanoacrylate (NBCA) in such lesions to make these lesions amenable to easy excision. When the NBCA comes in contact with tissue fluid, it causes intercompartmental tissue adhesion, thus there is cessation of blood flow into the vascular malformation tissue. After few injections the whole mass forms a solid polymer, which is then excised. During excision there is remarkably minimum bleeding. In small lesions, per-operative injection just prior to surgery was also done.

KEY WORDS

N-butyl cyanoacrylate, venous malformation, unresolved hemangiomas

INTRODUCTION

Many drugs and many methods have been tried in the last three decades for the management of unresolved hemangiomas and venous malformations. These methods include sclerotherapy, multiple site diathermy coagulation or steroid therapy. The drugs used for sclerotherapy are alcohol, ethanolamine oleate, amobarbital etc.^[1,2] Excision is another option, but without prior sclerotherapy the procedure is usually cumbersome and time-consuming.

In our study we have used N-butyl cyanoacrylate (NBCA) as a strong adhesive. NBCA is injected inside the vascular malformation (VM) and UH tissue after compressing the

lesion. NBCA is injected in different layers of the lesion area, which causes intercompartmental tissue adhesion.^[3,4] Thus, there is cessation of blood flow, and the whole mass turns into solid polymer after NBCA comes in contact with tissue fluid. The procedure is repeated as per response with the aim of excision and completing the treatment within the next 30 days. After these multiple injections, the area is excised without much bleeding. In small lesions less than 2 cm², we have also injected the NBCA on the OT table and after waiting for 10 min we could excise the lesion.

MATERIALS AND METHODS

We carried out this study from January 2002 to December 2005. A total of 90 cases were done. In our study the exclusion criteria were - children below two years, adults above 50 years and patients with cardiological problems.

Presentation: Conference: APSICON 2002 as preliminary report.
Place: Bangalore. Date: 30.11.2002 at 5.15 P.M.

Ocular and periocular lesions were also excluded. Of the 90 we treated, 78 patients had vascular malformations and 12 patients had unresolved hemangiomas. The clinical details are given in Table 1.

NBCA was injected intralesionally via percutaneous route or through the mucosa. The materials used were: 1 ml insulin syringe and four intramuscular needles. One needle was used to draw NBCA and the other three for subsequent injections because the area gets occluded almost instantly, hence the use of multiple needles at adjacent sites. The following protocol was followed as per the size of lesions.

- Lesions < 2 cm - one immediate preoperative injection
- Lesions between 2 and 5 cm - Usually, two injections with an interval of three to four days
- Lesions between 5 and 10 cm - Usually four injections with the same interval. Compartmentalization done in larger lesions
- Lesions > 10cm(always done after compartmentalization) As per response. Not less than six injections were given before excision, which was at times subtotal needing subsequent repeat procedures.
- Following sclerotherapy the whole area gets polymerized and forms a rocky substance, which is subsequently excised. There is minimum bleeding during excision. Hence any form of VM (except ocular or periocular VM) can be managed with injection NBCA.

RESULTS

On the whole NBCA injection served its purpose in all cases. There was no side-effect noted in follow-up

cases. Figures 1 and 2 show results of sclerotherapy and subsequent excision of VM in a 16-year-old boy and Figures 3 and 3a shows result of sclerotherapy in a tongue lesion.

In a number of lesions (six in the tongue and two in the palate), sclerotherapy with NBCA alone was sufficient for resolution without the need for excisional surgery.

In 20 cases where the lesions were small, NBCA was injected on the operation table just before excision. This helped to solidify the lesions, reduce their vascularity and made surgery easier.

After excision, we undertook histopathological study of the lesion, which also confirmed blockage of the vessels by formation of polymer.

Histological findings: There was fibrous thickening of the vessel and intervening tissue with the lumen of some of the smaller vessels being obliterated. NBCA was present as homogenous, pale, refractile, eosinophilic material in the lumen of larger vessels whose endothelial lining showed mild proliferation. Chronic inflammatory cell infiltration and foreign body giant cell reaction were present around these vessels [Figure 4].

DISCUSSION

The monomeric form of NBCA consists of an ethylene

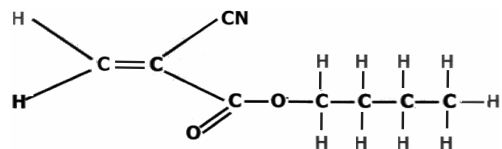


Table 1: Profile of lesions treated by NBCA

Site	No. of lesions	Dimensions (cm)				UH	VM
		<2	2-5	5-10	>10		
Nose	3	2	1	0	0	1	2
Cheek	21	3	12	6	0	6	15
Tongue and floor of mouth	18	6	11	1	0	1	17
Lower lip	11	3	6	2	0	2	9
Upper lip	11	3	5	3	0	0	11
Neck	2	0	0	1	1	0	2
Palate	2	0	2	0	0	0	2
Left upper limb	3	0	1	1	1	1	2
Right upper limb	2	0	0	1	1	0	2
Scapular region	2	0	0	0	2	0	2
Left lower limb	5	0	0	2	3	0	5
Right lower limb	8	0	0	3	5	1	7
Right ear	2	0	0	1	1	0	2
Total	90	17	38	21	14	12	78

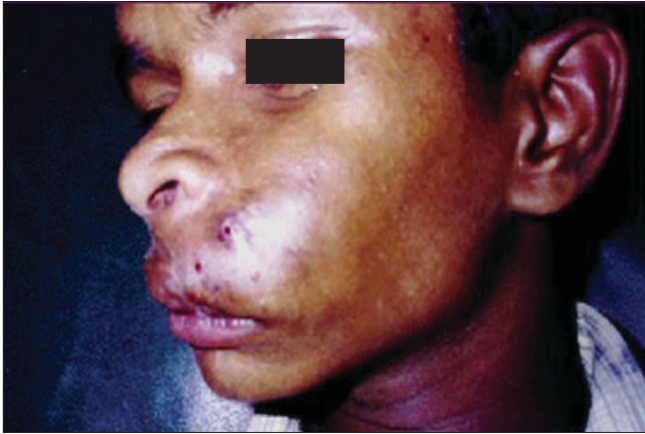

Figure 1: Unresolved large hemangioma before injection of cyanoacrylate

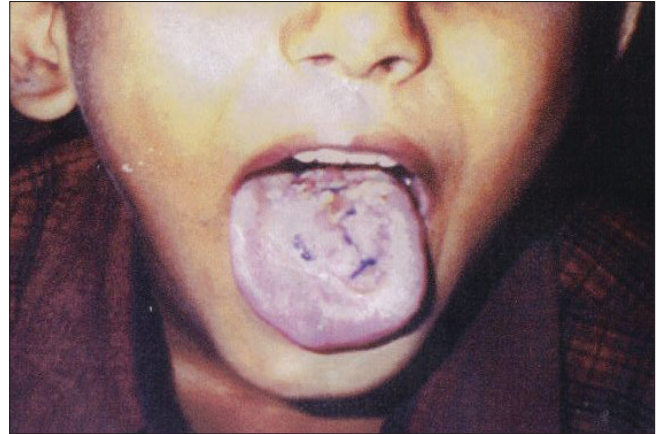


Figure 3a: Post operative photograph after injection of cyanoacrylate and excision

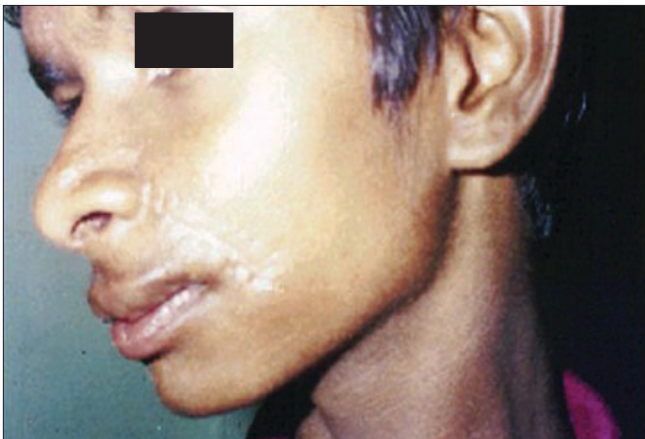

Figure 2: Result after cyanoacrylate injection followed by excision

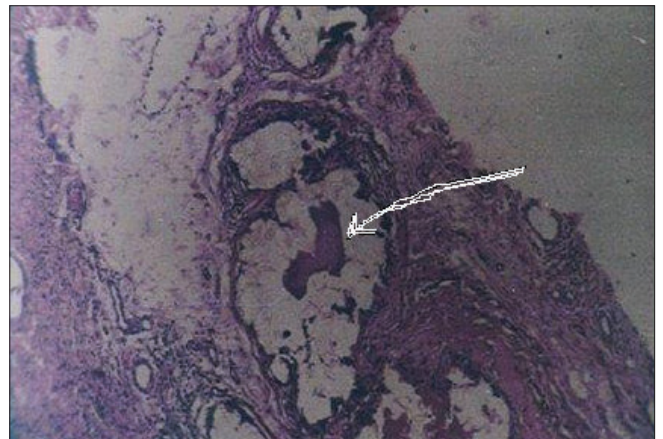


Figure 4: Histopathological picture showing vascular intraluminal cyanoacrylate (H & E, x400)

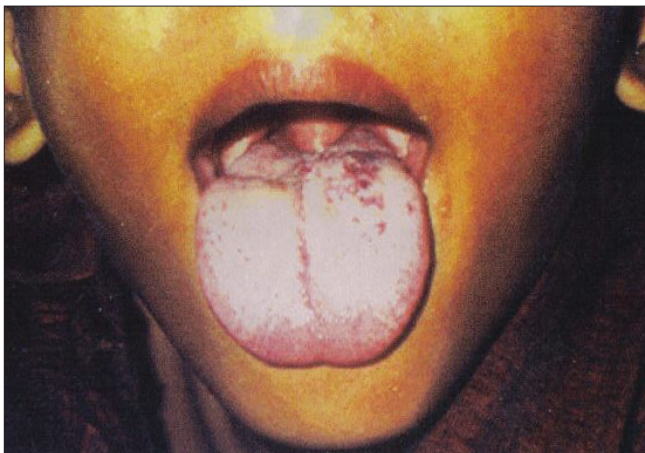


Figure 3: Venous malformation tongue

molecule with a cyano group and an ester attached to one of the carbons. The ester can have various hydrocarbons attached to it (the R-position). The hydrocarbon in this position also contributes to the name of cyanoacrylate e.g., isobutyl cyanoacrylate, NBCA; when

exposed to an anion such as hydroxy moiety in water or various anions found in blood, polymerization is initiated with bonding of ethylene units.^[2,5,6]

Structure of NBCA

Use of cyanoacrylate was restricted in the United States due to development of fibro sarcoma in animals after injection of large amounts of this material. In contrast, surgeons in Germany, France, Switzerland, Canada and Japan have been using cyanoacrylate, such as methyl-2 cyanoacrylate or isobutyl cyanoacrylate for sealing vascular aneurysm, intestinal repairs, gynaecological surgery, skin wound closure and skin graft adhesion to the skin around an open wound for more than three decades.^[7-10]

Cyanoacrylate is widely used in orthopaedics for hardware fixation and has been used for aortic and liver trauma, but it has limited use in plastic surgery in blood vessel

anastomosis, wound closure, flexor tendon repair, application of skin graft or haemostasis.

Recently, the FDA has approved medical use of cyanoacrylate. Cyanoacrylate is easy to handle in the operation theatre.^[5] In the US, recently, cyanoacrylates are the main liquid adhesive used in the vascular system and have an important role in managing vascular abnormalities, especially arteriovenous malformations. Vascular occlusion results as these agents polymerize, forming a cast of glue on exposure to anions in the blood.^[6] There is biological interaction—the deposition of cyanoacrylate within a vessel results in an acute inflammatory reaction in the wall and surrounding tissue. This progresses to a chronic and granulomatous process after approximately one month with a foreign body type of giant cell granuloma and fibrosis although occlusion created by glue (NBCA) is permanent.

CONCLUSION

NBCA is a superglue and leads to adhesion of endothelial layers of VM forming rocky hard polymer when it comes in contact with anions of blood. After that VM tissue is excised off, and there is minimum bleeding during operation.

ACKNOWLEDGMENT

We are thankful to the Medical Superintendent, SSKM Hospital, Kolkata for letting us use the hospital records and also thank the Head of the Department, Plastic Surgery and Pathology, SSKM Hospital, Kolkata for permission to carry out the work.

REFERENCES

1. Kesavdas C, Joseph S, Gupta AK, Nair R, Rao VR. Selective catheterization of external carotid artery feeder and embolization with hydrogel only b) hydrogel foam c) gel foam and d) direct percutaneous puncture and injection of N-butyl Cyanoacrylate. *J Plast Surg* 2000;33:58-64.
2. Lee BB, Bergan JJ. Multidisciplinary approach for vascular malformation, Arterio venous fistula and venous malformation by both ethanol and NBCA as sclerotherapy agent. *Cardio Vasc Surg Dec.*, 2002; 10:823-33.
3. De Merritt JS, Pile-Spellman J, Mast H, Moohan N, Lu DC, Young WL, *et al.* Outcome of analysis of pre-operative embolization with N-butyl cyanoacrylate in cerebral arterio venous malformation. *AJNR Am J Neuroradiol* 1995;16:1801-7.
4. Weinzweig J. *Plastic Surgery secrets*, 1st ed. Cyanocrylate - a strong biodegradable tissue adhesive used in aortic and liver trauma. 1999. p. 27.
5. Pollok JS, White RJ Jr. The use of Cyanoacrylate adhesive in peripheral embolisation. *J Vasc Interv Radiol* 2001;12:907-13.
6. Han MH, Seong SO, Kim HD, Chang KH, Yeon KM, Han MC. Craniofacial arteriovenous malformation: Preoperative embolization with direct puncture and injection of n-butyl cyanoacrylate. *Radiology* 1999;211:661-6.
7. Cremwell LD, Kerbee CW. Modification of cyanoacrylate for therapeutic embolization: Preliminary experience. *Am J Roentgenol* 1979;132:799-809.
8. Debrum GM, Aletich V, Ausman JI, Charbel F, Dujovny M. Embolization of the nidus of brain arteriovenous malformations with n-butyl cyanoacrylate. *Neurosurgery* 1997;40:112-21.
9. Kuneko R, Tobnai, I Udea M, Negoro M, Yoshida J, Yamada Y. Curative treatment of central hemangioma in the mandible by direct puncture and embolisation with n-butyl-cyanoacrylate (NBCA). *Oral Oncol* 2001;37:605-8.
10. Grabb WC, Smith JW. *Plastic Surgery*, 3rd ed. Surgeons in Germany, France, Switzerland, Canada and Japan are using Cyanoacrylate, such as methyl Cyanoacrylate for sealing vascular aneurysm. 1979. p. 16-1.

Source of Support: Medical Superintendent, SSKM Hospital, Kolkata,
Conflict of Interest: None declared.

Announcement

www.isapscongress2008.org

Dear Colleague,

One year from today, the 19th ISAPS Congress will begin!

Mark your Calendar:

Melbourne, Australia

February 9-13, 2008

Look for more emails about the scientific program, registration, travel, hotels, and tours. Now is the time to start thinking about and planning for all the other wonderful places you can visit when you come to Melbourne in 2008!