

Case Report

Diagnostic dilemma in Kaposi's sarcoma

Satish B. S. Rao, Leo F. Tauro, Leo Theobald Menezes, B. Nandakishore, K. Praveen Kumar

Department of General Surgery, Fr. Muller Medical College Hospital, Kankanady, Mangalore - 2, Karnataka, India

Address for correspondence: B. S. Satish Rao, Department of General Surgery, Fr. Muller Medical College Hospital, Kankanady, Mangalore - 2, D.K., India. E-mail: dr_satishrao@rediffmail.com

ABSTRACT

Kaposi's sarcoma is described as cutaneous and extracutaneous neoplasm predominantly affecting older individuals. Though earlier uncommon and endemic to certain African areas, its incidence is on a rise due to infections with human immunodeficiency virus and also due to transplant-associated immunosuppression. Further, certain benign conditions like Pseudo Kaposi's sarcoma, certain infective conditions like bacillary angiomatosis of acquired immunodeficiency syndrome can mimic Kaposi's sarcoma both clinically and histologically leading to a diagnostic dilemma. We report such a case here.

KEY WORDS

Kaposi's sarcoma, pseudo Kaposi's sarcoma, diagnosis

INTRODUCTION

Kaposi's sarcoma was first described in 1872 by Moritz Kaposi as cutaneous and extracutaneous neoplasms predominantly affecting older individuals and running a protracted clinical course. It is a tumour mainly composed of proliferating vessels and spindle-shaped cells. Its well-known association with the human immunodeficiency virus (HIV) has provoked considerable interest in this previously uncommon entity. Further, certain benign angioformative lesions can mimic Kaposi's sarcoma both clinically and histologically. We report such a case here.

CASE REPORT

A 46-year-old female patient with filarial lymphoedema of right leg presented with a chronic nonhealing ulcer of two years duration on the same leg which initially occurred due to some trivial trauma [Figure 1]. She was initially seen by a dermatologist who advised biopsy of the lesion.

The biopsy was reported as Pseudo Kaposi's sarcoma. She was admitted to the hospital. A wide excision of the ulcer followed by superficial thickness skin grafting was done and the excised specimen was sent for histological confirmation. The histopathological examination revealed "Aggressive Kaposi's sarcoma".

The patient was found to be HIV negative. She was advised to undergo ultrasound of abdomen, chest X-ray and C.T. scan of brain to look for secondaries and if negative was planned for an above knee amputation and chemotherapy. The patient refused all further investigations and treatment and left against medical advice.

DISCUSSION

Kaposi's sarcoma is an angioformative lesion classically seen in elderly East European and Mediterranean males. Nowadays its incidence is on the rise due to its association with HIV patients.^[1] There are four clinically recognized subtypes:

1. Sporadic (classic)
2. Endemic (African type)
3. Iatrogenic (in immunocompromised post transplant patients)
4. HIV related (Epidemic).

The classic variant has a genetic basis and is HLA-linked whereas the endemic variety is usually seen in black Africans and is not associated with immunodeficiency.^[2] Although HIV-associated (epidemic type) is now the most common variety, it is also being encountered with increasing frequency in organ transplant recipients.^[3]

Kaposi's sarcoma usually starts as a bluish red macule on the distal portions of the lower extremities and the lesions progress slowly and may coalesce to form large plaques. As the lesions age, they become brownish in color and may progress to firm nodular and fungiform

tumors or may erode and ulcerate. The early angiomatous lesions are soft and spongy to touch while older tumors are firm. Histologically there is dermal proliferation of interlacing bundles of spindle cells and intimately related, poorly defined slit-like vessels with angulated vascular spaces. These spindle cell components show variable nuclear pleomorphism and mitotic figures. In early stages, there is associated inflammatory cell infiltrate consisting predominantly of lymphocytes and plasma cells [Figure 2].

Pseudo Kaposi's sarcoma, also called Mali's disease or acroangiokeratosis has been described as unilateral, subacute to chronic dermatitis, often with postinflammatory hyper-pigmentation occurring in amputees with poorly fitting appliances, in A-V fistulas, venous hypertension etc. [Figure 3]. These lesions may closely resemble Kaposi's sarcoma both clinically and

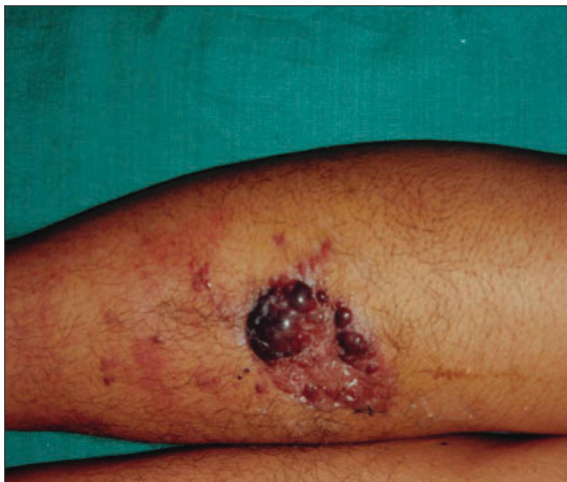

Figure 1: Ulcer with bluish red macules on anterior aspect of leg with multiple small and similar lesions seen distally

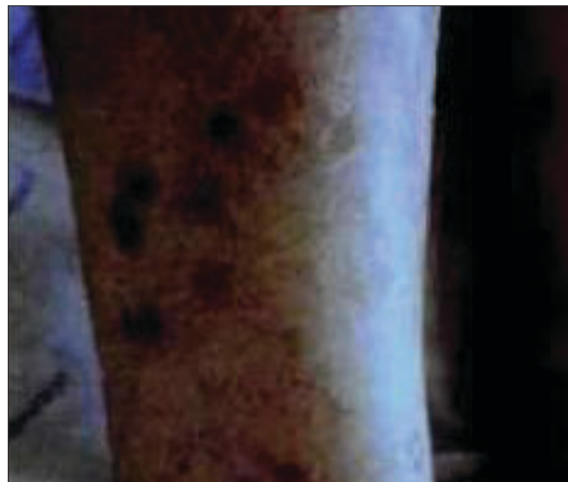

Figure 3: Clinical photograph of pseudo kaposi's sarcoma of leg

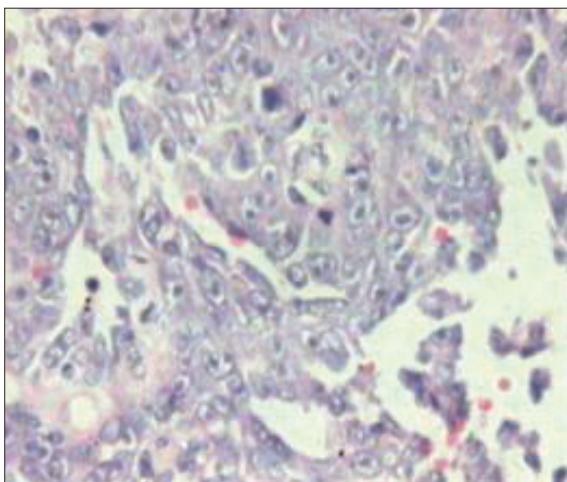


Figure 2: Histopathology showing proliferation of spindle cells and slit like vessels with angulated vascular spaces

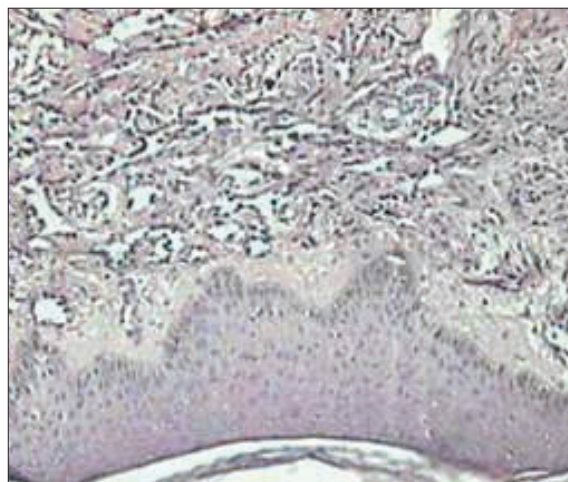


Figure 4: Pseudokaposi's sarcoma showing lack of slit like vessels and cell proliferation

histopathologically. These lesions show proliferation of capillaries which is accompanied by extravasation of red blood cells and deposition of hemosiderin. Although both Kaposi's and pseudo Kaposi's sarcoma are angioproliferative lesions, it is imperative to have a clear-cut distinction between the two, especially in HIV negative patients, owing to high malignant potential of Kaposi's sarcoma which has to be treated aggressively with multiple modalities like surgery, radiotherapy, chemotherapy and immunotherapy.^[4] The problem of distinguishing between these entities is confounded by the fact that the histological differentiation is based on criteria like the quantum of dissecting vessels^[5] etc, which may lead to subjective errors during reporting.

To minimize these type of errors it is important to remember the key points of distinction in Pseudo Kaposi's sarcoma, which are lack of progression and importantly, lack of cell proliferation and absence of slit-like vessels [Figure 4]. Further, immuno-labeling with CD 34 antigen, a marker of Kaposi's sarcoma cells could be of value in distinction between these two angioproliferative disorders.^[6]

Finally, in any recurrent benign angioformative lesions,

the possibility of Kaposi's sarcoma should be kept in mind and should be carefully evaluated and investigated for the same.

Long-standing venous stasis of any cause may produce skin lesions resembling Kaposi's sarcoma making the diagnosis difficult, especially if the patient is HIV negative, thus giving rise to a diagnostic dilemma.

REFERENCES

1. Beral V, Peterman TA, Berkelman R, Jaffe HW. Kaposi's sarcoma among persons with AIDS: A sexually transmitted infection? *Lancet* 1990;335:123-8.
2. Kestens L. Endemic African Kaposi's Sarcoma is not associated with immunodeficiency. *Int J Cancer* 1986;36:49.
3. Penn I. The changing pattern of post transplant malignancies. *Transplant Proc* 1991;23:1101-3.
4. Deichmann M, Thome M, Jackel A, Utermann S, Bock M, Waldmann V, *et al.* Non - HIV Kaposi's Sarcoma can be effectively treated with low dose interferon- alpha despite the persistence of herpesvirus-8. *Br J Dermatol* 1998;139:1052-4.
5. Hong A, Lee CS. Kaposi's sarcoma: Clinico pathological analysis of HIV and non HIV associated cases. *Pathol Oncol Res* 2002;8:31-5.
6. Kanitakis J, Narvaez D, Claudy A. Expression of the CD 34 antigen distinguishes Kaposi's sarcoma from Pseudo-Kaposi's sarcoma (acroangiokeratosis). *Br J Dermatol* 1996;134:44-6.