

Brief Report

Flexor accessorius longus: A rare variation of the deep extrinsic digital flexors of the leg and its phylogenetic significance

P. Jaijesh, M. Shenoy*, L. Anuradha*, K. K. Chithralekha**

Department of Anatomy, Melaka Manipal Medical College, Manipal - 576104, Karnataka, *Kasturba Medical College, Mangalore - 576004, Karnataka, **Department of Zoology, Higher Secondary School, Kamballore, Kasaragod, Kerala, India

Address for correspondence: Jaijesh P, Department of Anatomy, Melaka Manipal Medical College (Manipal campus), Manipal - 576104, Karnataka, India. E-mail: jaijesh@yahoo.co.in

ABSTRACT

Anomalies of the calf muscles are rare. One such anomalous muscle, known as the Muscle Flexor accessorius longus (also named accessorius ad accessorium, accessorius secundus, accessory flexor digitorum longus or pronator pedis) is of morphological significance. When present, this originates in the deep fascia of the tibia or fibula and inserts in the foot either into the flexor digitorum accessorius or into the tendons of the flexor digitorum longus. In this report we present a discussion of the morphological significance and phylogenetic history of one such muscle observed. In this case report we describe an anomalous calf muscle which extends from the popliteal region, runs along the posterior compartment of the leg, reaches the sole and is inserted to the flexor digitorum longus muscle. This kind of muscle variations are considered to be the higher origin of the flexor digitorum accessorius muscle of the sole. Here we discuss the phylogenetic history of this muscle as this muscle variant is present in some primitive mammals, absent in apes and in this particular case appeared as one of the muscles of the flexor compartment of the leg.

KEY WORDS

Flexor accessorius longus, flexor digitorum accessorius, foot, muscular variations

INTRODUCTION

Variations of the deep extrinsic digital flexors among the calf muscles in humans are uncommon, some such variants being of considerable morphological significance. One of them commonly known as the M. flexor accessorius longus (also named accessorius ad accessorium, accessorius secundus, accessory flexor digitorum longus or pronator pedis) is a very variable slip, both in its origin and insertion.^[1] Most commonly, when present it arises from the fibula

or from both the fibula and tibia and ends, after passing beneath the flexor retinaculum, by joining the flexor digitorum accessorius muscle in the sole of the foot.^[1] Here we report an anomalous muscle of this type, but with some difference in its origin, which we came across during our routine lower limb dissection.

The muscle quadratus plantae or flexor digitorum accessorius has been reported as present in 28% of gorillas, in 48% of orang-outangs, in 50% of chimpanzees and in 100% of humans.^[1,2] The flexor accessorius in

humans originates by two heads, from the concave medial surface of the calcaneus and from the area anterior to the lateral tubercle of the calcaneus. The flexor accessorius inserts onto the lateral margin of the tendon of the flexor digitorum longus.^[3]

The total or partial absence of one of the heads of origin of the flexor digitorum accessorius has classically been reported [Figure 1].^[1-3] In a similar way, the existence of supernumerary fascicles coming from the leg has also classically been reported [Figure 2].^[1-3]

These supernumerary bellies have been reported with different names: accessorius ad calcaneum of Gantzer and Wood;^[4] peroneo-calcaneous internus of Macalister;^[1] accessorius secundus of Humphry; accessorius ad accessorium of Turner;^[4] flexor accessorius digiti longus;

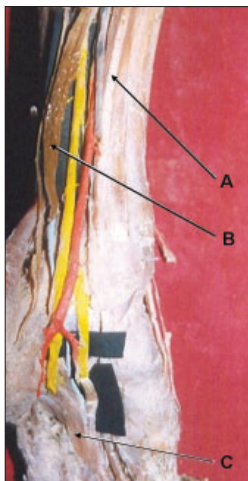


Figure 1: A-Flexor digitorum longus B-Flexor accessorius longus C-Flexor digitorum accessorius. Posterior view of left leg

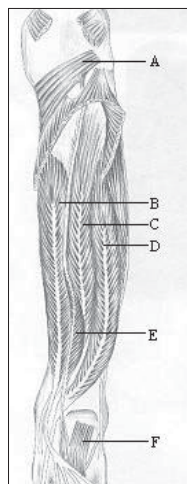


Figure 2: A-Popliteus B-Flexor digitorum longus C-Tibialis posterior D-Flexor hallucis longus E-Flexor accessorius longus F-Flexor digitorum accessorius. Diagram of left leg showing the course of flexor accessorius longus

accessorius ad quadratum plantae; accessorius longus ad flexor digitorum longum; accessorius flexori hallucis longi superior; etc.^[2,3]

The reported origin of the aforesaid muscles varies widely, from the tibia or fibula or from both bones, the deep fascia or one of the muscles of the deep compartment of the leg.^[1-3] Also, their insertion has been reported in a variable way, joining the flexor digitorum accessorius (quadratus plantae) or the flexor digitorum longus tendon in the sole.^[1-3,5]

The course of the tendon of these variant muscles has been reported passing beneath the flexor retinaculum of the foot, they are located in the pre-Achilles fat pad of the lower calf, so it may appear radiographically as a soft-tissue mass.^[5]

It is commonly assumed that the function of the flexor digitorum accessorius is to straighten out the pull of the flexor digitorum longus, aligning its action along the long axes of the phalanges. However, electromyography has shown that (together with the flexor digitorum brevis) its primary function is to supplement the work of the flexor digitorum longus when more flexing power is required during bipedal progression.^[6]

CASE REPORT

During the course of routine dissection, we found this flexor muscle in the crural region of the leg, deep to the deep transverse fascia, bilaterally in a female cadaver. As a bipinnate muscle, it had a tendinous origin from the fascia covering the popliteus muscle. The narrow tendinous slip then passed through the tendinous arch of the soleus to lie between the flexor digitorum longus and tibialis posterior. In the lower third of the posterior compartment of the leg, the tendon formed a prominent bipinnate muscular belly, which was crossed by the posterior tibial artery and the tibial nerve from the lateral to medial side. In crossing, the posterior tibial artery was close to the surface and the tibial nerve was found deep in the muscle and the muscle was supplied by both. In the lower part of the leg this anomalous muscle again became tendinous and was situated lateral to the contents of the flexor retinaculum. After entering the sole of the foot, the tendon passed along the medial margin of the flexor digitorum accessorius. Some of the tibial head fibers of the flexor digitorum accessorius were inserted into this tendon and finally the tendon

became inserted into the deep surface of the flexor digitorum longus at its division into four digital slips.

DISCUSSION

The morphology of the flexor accessorius longus is related to the phylogenetic history of the flexor digitorum accessorius. According to Wood,^[7] it seems clear that the flexor digitorum accessorius is a constituent part of the deeper layer of the flexor-pronator group of muscles that has come to occupy a position confined to the sole of the foot.

The flexor digitorum accessorius is almost a dual muscle, consisting typically of distinct tibial and fibular-sided heads.^[7] In monkeys and apes, only the fibular-sided head is present. The tibial-sided head is present only in humans and, oddly, in some of the most primitive mammals. Thus, the flexor digitorum accessorius is an essential human specialization, since its extensive attachment to the tibial side of the calcaneus is absent in monkeys and apes.^[7]

According to Wood Jones, in primitive mammals, the flexor digitorum accessorius muscle presents a higher tibial and fibular-sided origin and in humans, this muscle would seem to have descended into the sole.^[7] The origin of this muscle, in many primitive mammals is from the pronator pedis element, representing part of the deep stratum of the flexor-pronator mass that is present at the junction of the two distal segments of the hind limb. Survival of this deep stratum is recognized in occasional human muscles that, arising somewhat variably in the leg, become blended with the flexor digitorum accessorius in the foot.^[7]

Wood John. reported a similar case in the right leg of a female: "it was found as a complete specimen of the flexor accessorius digitorum longus pedis, arising by a single penniform belly from the lower third of the outer border of the fibula and the post-tibial fascia and ending in a tendon which joined that of the flexor digitorum longus at the point where the normal *-massa carnea Sylvii-* was connected with it".^[4]

Wood John. also explained that he found this variant muscle in four male subjects out of 68 and in one female out of 34. In all it arose from the lower third of the

fibula and the fascia covering the flexor hallucis longus. In three of the males it was found in both legs. In the fourth male and in the female it was found in the right leg only.^[4]

It is probable that the flexor accessorius longus, the accessorius ad accessorium, accessorius secundus etc. would all be landmarks along the line of passage of the flexor digitorum accessorius into the sole of the foot by way of the tibial aspect of the knee joint. If this account of the morphology is correct it would seem that the tibial-sided higher origin would be phylogenetically older and that, in retaining it, humans have preserved a more primitive muscular plan than that characteristic of monkeys and anthropoid apes. Also, by having retained this primitive type of muscle, humans have specialized towards specifically human gait features.^[4]

The accessory flexor digitorum longus has been reported to be found in 12 of 100 cadavers by Nathan *et al.*^[8]

The other generalization that should be recalled here is that although many primitive mammalian muscles are preserved in the human foot, in most cases they do not retain their primitive function.^[4]

REFERENCES

1. Macalister A. Additional observations on muscular anomalies in human anatomy (3rd series) with a catalogue of the principal muscular variations hitherto published. Trans Royal Ir Acad 1875;25:1-134.
2. Testut L. Les anomalies musculaires chez l'homme. Masson: Paris;1884.p.688-94.
3. Le Double AF. Traité des variations du système musculaire de l'homme et de leur signification au point de l' anthropologie zoologique, vol. W. Librairie C. Reinwald, Schleicher Frères: Paris;1897.p.402-6.
4. Wood J. Variations in human myology observed during the winter session of 1867-68 at King's College, London. Proc Roy Soc 1868;16:483-525.
5. Bergman RA, Thompson SA, Afifi AK, Saadeh FA. Compendium of human anatomic variation. Urban and Schwarzenberg: Baltimore;1988.p.27-8.
6. Resser LA, Susman RL, Stern J. Electrogromiographic studies of the human foot: Experimental approaches to hominid evolution. Foot and Ankle 1983;3:391-407.
7. Wood JF. Structure and Function as seen in the Foot. 2nd ed. Bailliere, Tindall and cox: London, England;1949.p.157,188,225.
8. Nathan H, Gloobe H, Yosipovitch Z. Flexor digitorum accessorius longus. Clin Orthop Relat Res 1975;113:158-61.