

Original Article

Does closure of chronic pilonidal sinus still remain a matter of debate after bilateral rotation flap? (N-shaped closure technique)

Mohamed M. S. Awad, Khaled M. Saad

Department of Plastic Surgery, Zagazig University Hospital, Egypt

Address for correspondence: Mohamed MS. Awad, Department of Plastic Surgery, Zagazig University Hospital, Egypt.
E-mail: dadlahm@yahoo.com

ABSTRACT

Background: Controversy still exists about the exact cause of pilonidal sinus either acquired or congenital, and also about what is the best surgical technique for the treatment of the disease. We successfully treated chronic pilonidal sinus with a new flap technique {N-shaped bilateral rotation flap} for closure of the defect.

Materials and Methods: Thirty-two patients (30 men and two women) were treated by eccentric elliptical excision of the diseased tissues down to the postsacral fascia and closure of the defect with our flap [which is a random pattern flap], then a closed suction drain was placed at the base of the wound, with its tip being brought out in the gluteal region at least 5 cm lateral to the lower end of the suture line.

Results: All our patients healed completely without recurrence during a period of average follow-up of two years. Mean hospital stay was 1.5 days (range 1-5 days). Mean time to complete healing was 11.9 days (range 6-18 days). Mean time off work was 13.7 days (range 10-21 days). Two patients had wound infection and one patient a partial breakdown. The recurrence rate was 0%.

Conclusions: A tension-free suture via bilateral rotation flaps with a good suction at the button of the wound for drainage of blood from the bottom of the wound is the key to the success of repair without recurrence.

KEY WORDS

N-shaped flap, pilonidal sinus, rotation flap

INTRODUCTION

Pilonidal sinus is an acquired condition usually seen in young adults that carries high postoperative morbidity and patient discomfort. The most important predisposing factors for the development of pilonidal sinus are the existence of a deep natal cleft and the presence of hair within the cleft.^[1,2] A deep natal cleft is a favourable environment for sweating, maceration, bacterial

contamination and penetration of hairs. Thus, for treatment and prevention, these causative factors must be eliminated.^[3,4] Despite the controversy about the best surgical technique for the treatment of pilonidal sinus, the aim of this study is to reach an ideal operation that would minimize financial cost to the community and the patient (e.g., earlier return to work), be simple, not require a prolonged hospital stay, have low recurrence rate and be associated with low complication rate and minimal pain.

MATERIALS AND METHODS

Thirty-two patients were treated with bilateral elliptical cutaneous rotation {N-shaped} flap during the period April 2003 to June 2004. All patients had chronic pilonidal sinus. Ten patients had recurrent disease after a failed surgical procedure; the rest were primary surgery. All patients were admitted to the hospital the day before the surgery and operated under general or spinal anaesthesia. The natal cleft was shaved the day before the surgery. The patients were placed in prone jack-knife position on the operating table with the legs slightly abducted and the buttocks strapped apart by adhesive tapes on the table.

The surgical procedure is a vertical elliptical excision of all the diseased tissue down to the postsacral fascia; we prefer to excise it in an eccentric manner with respect to the skin level [Figures 1 and 4]. This was done to get the

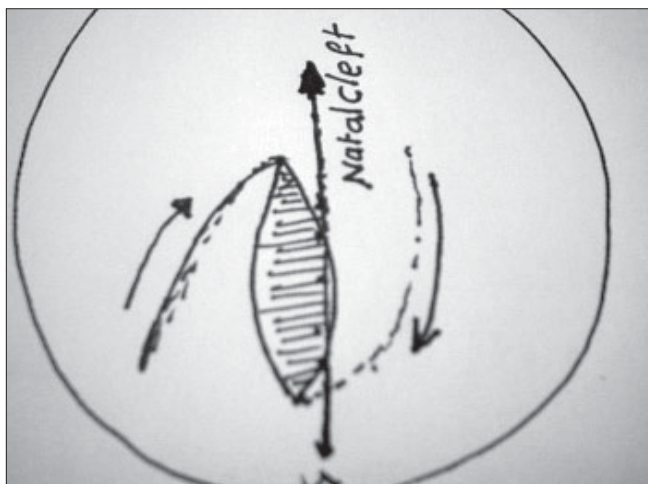


Figure 1: Marking of the eccentric excision

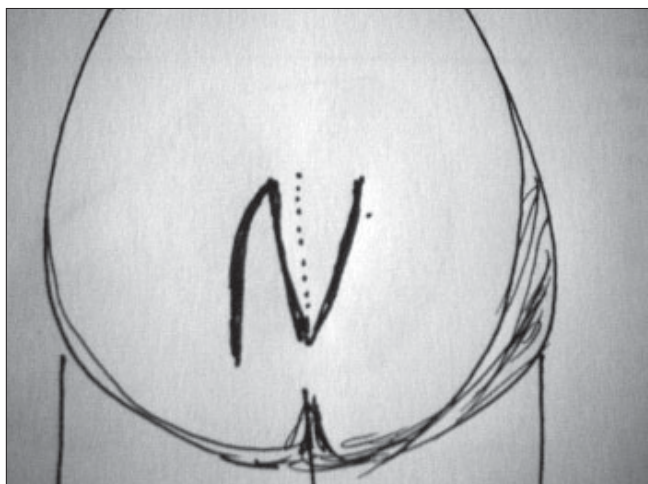


Figure 2: Postoperative N shaped closure technique

eventual line of closure away from the midline [Figures 2 and 5]. This will be elaborated later. Care must be taken to handle tissues as gently as possible and meticulous hemostasis should be accomplished. N-shaped cutaneous skin flap was marked on both sides of the excised sinus over the gluteus muscle fascia [Figure 4].

The flaps were then raised, rotated and advanced on both sides and sutured subcutaneously with 3-0 Polyglactin beginning from its lower edge [Figures 5, 6]. The stitch should include the postsacral fascia so as not to leave a dead space. The skin was sutured with vertical mattress stitch of 3-0 Prolene. The secondary defect was sutured primarily with the same material in a similar fashion after cutaneous release on both sides [Figure 2]. Closed suction drains were placed in potential space in all patients and removed after 14 days.

Wound inspection and dressing were done twice each week [Figure 7], followed by a firm dressing to cause physiological compression at the natal cleft site, removal of sutures was done after ten days. The patients were instructed to have bed rest, backing supine position without fear of vascular compromise.

RESULTS

Thirty-two patients with chronic pilonidal sinus were treated with this technique. Of these ten patients had recurrent disease after a failed previous surgical procedure.

Mean age was 30.4 years (range 18 to 45). Mean follow-up was 22 months (range 12 to 32). The mean time of hospital stay was 1.5 days range (1-5) days. The mean time of complete healing was 11.9 days (range 6-18 days). There was no recurrence, Figures 8 and 9 show our long term results only one case had partial wound breakdown due to collected seroma and two patients had wound infection [6.3%]. Incidentally, in both these patients, the shaving of the operative site was done in the operating theatre immediately before surgery. These cases were controlled with daily dressing and antibiotics according to the culture sensitivity [Table 1].

Table 1: Postoperative outcome

Mean hospital stay (d) (range)	1.5 (1-5)
Mean time to complete healing (d) (range)	11.9 (6-18)
Mean time off work (d) (range)	13.7 (10-21)
Wound infection (%)	2 (6.3%)
Wound breakdown (%)	1 (3.3%)
Recurrence (%)	0

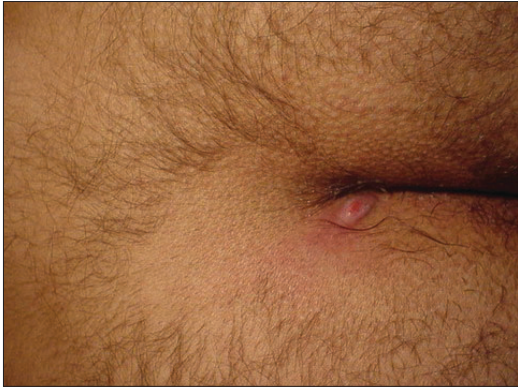

Figure 3: single sidewall pilonidal cyst

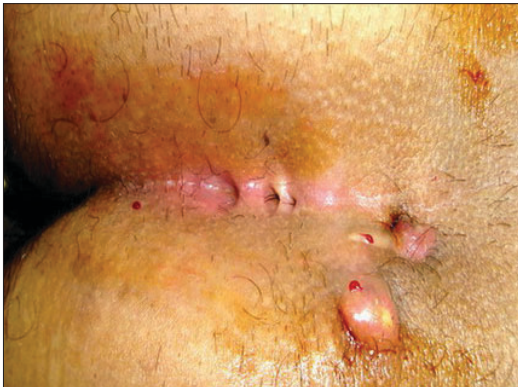

Figure 4: Multiple sinuses

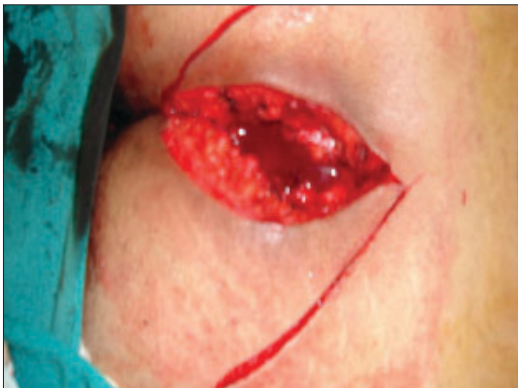

Figure 5: Eccentric excision and N shaped

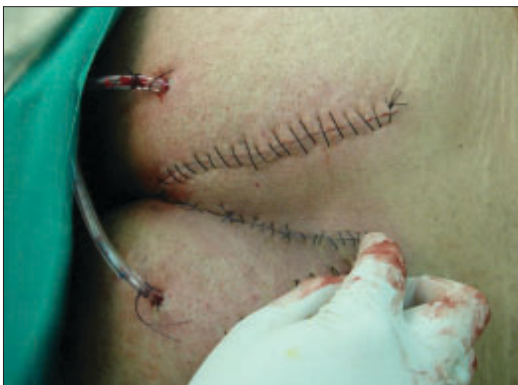

Figure 6: Intraoperative picture

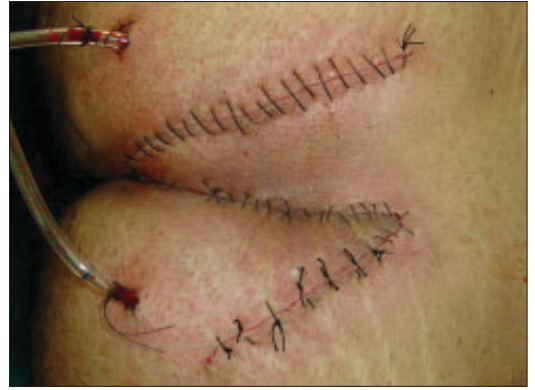

Figure 7: Postoperative picture after one week

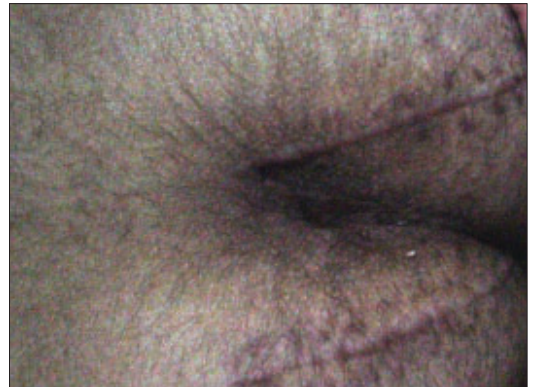

Figure 8: after 2 years

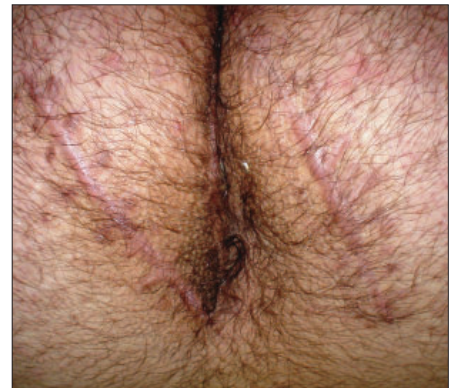

Figure 9: Postoperative picture in another patient after 2.5 years

Comments

Surgical treatment of chronic pilonidal sinus includes open excision;^[5,6] primary closure;^[7] just lay open and^[8] excision and flap closure. 'Lay open' is the simplest technique among these but the complete healing time is long and the recurrence rate is 10%.^[6] Open excision technique needs long hospitalization and wound dressing daily. Wound breakdown is also another disadvantage caused by premature closing of the skin edges before complete wound healing. Excision of the diseased tissue down to the postsacral fascia is generally accepted but the management of the remaining defect is still a matter

of debate. Primary closure of the wound is a simple technique but it has a high recurrence rate due to continuing natal cleft. But Tritapepe and Padova 2002^[9] after 5 to 15 years follow-up in 243 cases with chronic sinus irrespective of lifting the natal cleft, stated that excision and primary closure with a catheter at the bottom of the wound and the use of antiseptic/saline flushing are essential for primary intention healing and the avoidance of recurrences Bascom^[7] reported that pilonidal abscesses never begin on a convex surface and reducing the depth of the concave fold that harbours the problem cures the disease.

In our study with respect to the site of the sinus we found that high incidence occurred at the side wall of the natal cleft more toward its upper end [Figure 3], [Table 2]. Another important issue is wound tension. Tension-free closure improves patient comfort and shortens hospital stay. In this regard, flap procedures have an advantage. Several flap techniques have been described with various results.

The Z-plasty procedure has been described by Monro and MacDermott^[8] in 1965. The disadvantage of this procedure is that part of the wound is in the midline which is the main cause of recurrence. Besides, flap tip necrosis has been reported.

The W-plasty technique has been described by Roth and Moorman in 1977.^[10] Part of the wound is still in the midline and recurrence rate is high (8%).

Table 2: Preoperative patient characteristics

Preoperative patients	No.
Age	
(18-38)	17 (53)
(38-48)	15 (47)
Sex	
Male	30 (93)
Female	2 (7)
Character	
Primary	22 (68.7)
Recurrent	10 (31.3)
Hair density in the area	
Course	18 (56.3)
Scanty	14 (43.7)
Natal cleft	
Shallow	8 (25)
Deep	24 (75)
Site of the sinus in the cleft	
Upper mid	11 (34.4)
Lower mid	9 (28.3)
Side wall	12 (37.3)

Figures in parentheses are percentage

To decrease the incidence of recurrence, many procedures were developed to avoid the midline sutures like "D" excision which is a surgical technique of elliptical incision and primary wound closure. The overall success rate is 80%.^[11] Another flap technique that avoids the midline wound is the advancement flap operation described by Karydakis.^[9,12] After excision of the pilonidal sinus, one of the wound edges is undermined and advanced against the other wound edge and sutured. Its recurrence rate is 1% to 4%, complication rate 8.5% to 9% and the mean hospitalization stay is three to four days.^[13]

Either with D excision or Karydakis and Bascom techniques, the common factor is all of them excised the diseased skin and subcutaneous tissue in a limited manner to avoid a big excision that may lead to tension sutures and wound breakdown.

Karydakis^[12] noticed the presence of hair in all his patients thus he advocated to excise the diseased tissue including that containing hair with suturing of the defect away from the midline to avoid the weak or macerated skin in the mid line and lifting the natal cleft. These manoeuvres all avoid trapping the loose hair from the body and decrease the recurrence rate.

In our study only three patients had hair in the sinus. We are still not certain whether hair is the cause of the disease or whether the accumulation of hair is merely incidental in the disease process but we found that all of our patients had an itching tendency either in the natal cleft or between the fingers. Thus we advocate the main problem is from itching, through creation of macerated skin, which is liable to attract and collect any necrotic debris and loose hair eventually forming the pilonidal sinus. Also, it is notable that the data collected in our study shows the sinus present mostly in patients with scanty hair and shallow natal cleft.

The closure of the defect with a flap technique has been a matter of debate until now. We advocate that the problem of recurrence after pilonidal sinus management may be due to incomplete excision of the diseased tissue and closure of the defect with tension sutures that leads to wound breakdown during the shearing movement at the natal area. We closed the defect after wide excision of all diseased tissue down to the postsacral fascia with bilateral cutaneous rotation flap without any tension at

the suture line and with a minimal arc of rotation versus the elliptical rotation flap done by others that need rotation at right angle it also it had a narrow pedicle which can be easily compromised.

Despite controversy about the best surgical technique for the treatment of pilonidal sinus, an ideal operation should be simple, should not need a prolonged hospital stay, should have a low recurrence rate and should be associated with minimal pain and wound care to decrease time off work.^[14]

The Limberg flap is another transposition technique; it is suitable only for closure of rhomboid defects with angles of 60 and 120 degrees and the flap depends on the looseness of adjacent skin. Reported complication and recurrence rates are 6% and 4.9%, respectively.^[15]

Closure of the defect with a rotation flap is described by Cherry.^[16] The technique seems to be similar to elliptical rotation flap at first glance. However, it creates a line of tension along the radius of the arc that may necessitate back-cut. This decreases the blood supply to the flap.^[17] It has an 8% recurrence rate.

Elliptical rotation flap for pilonidal sinus was published by Nasser *et al.*, in 2003^[18] A random pattern flap based on the subdermal plexus allows elevation of an elliptical-shaped flap of skin and subcutaneous tissue with a length to width ratio in the range of 2 to 1.5:1. Although limited in reach, this random pattern flap can be elevated and rotated to provide viable skin and subcutaneous tissue to close an adjacent wound.^[19]

We agree that this method has minimal inconvenience and lower recurrence rates than other methods but this method requires much more experience because it requires the dissection of cutaneous and subcutaneous tissue and gluteus muscle fascia.^[20] In addition, only a 1-cm pivot point in its lower corner has been used in this technique. After the rotation of the flap, the vascular elements in the flap can be destroyed and flap necrosis can occur easily, so this surgical technique is not advisable in our opinion for all kinds of pilonidal sinus disease.

The Limberg flap scores in simplicity but it needs excessive mobilization, it also needs an expert surgeon and more excision of a normal skin for marking the rhomboid shape of 60 and 120 degree.

Our flap in the present study depends on basic knowledge of performing the rotation flap. It also carries the advantage of minimal dissection and the bilateral rotation has a big advantage of tension-free sutures. Thus it easy to rotate without any compromise of the blood supply of the flap. This results in no recurrence and minimum period off from work.

CONCLUSION

Shifting of the natal cleft away from the midline and obliteration of dead space by our flap has an advantage over other techniques like Z-shaped and rhomboid operations.

REFERENCES

1. Karydakis GE. The etiology of pilonidal sinus. *Hellenic Armed Forces Med Rev* 1975;7:411-6.
2. Page BH. The entry of hairs into a pilonidal sinus. *Br J Surg* 1969;56:32.
3. Eryilmaz R, Sahin M, Alimoglu O, Dasiran F. Surgical treatment of sacrococcygeal pilonidal sinus with the Limberg transposition flap. *Surgery* 2003;134:745-9.
4. Karydakis GE. Hair insertion (pilonidal sinus). *Hellenic Armed Forces Med Rev* 1968;2:273-85.
5. Jensen SL, Harling H. Prognosis after simple incision and drainage for a first-episode acute pilonidal abscess. *Br J Surg* 1989;75:60-1.
6. Notaras MJ. A review of three popular methods of treatment of postanal (pilonidal) sinus disease. *Br J Surg* 1970;57:886-90.
7. Bascom J. Skin flaps for pilonidal disease. *Ann Plast Surg* 1998;41:338.
8. Monro SR, MacDermot FT. The elimination of causal factors in pilonidal sinus treated by Z-plasty. *Br J Surg* 1965;52:177-81.
9. Tritapepe R, Di Padova C. Excision and primary closure of pilonidal sinus using a drain for antiseptic wound flushing. *Am J Surg* 2002;183:209-11.
10. Roth RF, Moorman WL. Treatment of pilonidal sinus and cyst by conservative excision and W-plasty closure. *Plast Reconstr Surg* 1977;60:412-5.
11. Mann CV, Springall R. 'D' excision for sacrococcygeal pilonidal sinus disease. *J R Soc Med* 1987;80:292-5.
12. Karydakis GE. Easy and successful treatment of pilonidal sinus after explanation of its causative process. *Aust N Z J Surg* 1992;62:385-9.
13. Kitchen PR. Pilonidal sinus: Experience with the Karydakis flap. *Br J Surg* 1996;83:1452-5.
14. Akýncý OF, Coskun A, Uzunkoy A. Simple and effective surgical treatment of pilonidal sinus: Asymmetric excision and primary closure using suction drain and subcuticular skin closure. *Dis Colon Rectum* 2000;43:701-7.
15. Urhan MK, Kucukel F, Topgul K, Ozer I, Sari S. Rhomboid excision and Limberg flap for managing pilonidal sinus. *Dis Colon Rectum* 2002;45:656-9.
16. Cherry JK. Primary closure of pilonidal sinus. *Surg Gynecol Obst* 1968;126:1263-9.
17. Aston SJ, Beasley RW, Thorne CHM. *Grabb and Smith's plastic surgery*. 5th ed. Lippincott-Raven: Philadelphia;1997.

18. Nessar G, Kayaalp C, Seven C. Elliptical rotation flap for pilonidal sinus. *Am J Surg* 2004;187:300-3.
19. Mathes SJ, Nahai F. *Reconstructive Surgery: Principles, Anatomy and Technique*. Churchill-Livingstone: New York; 1997.
20. Yazicioglu B, Polat C, Gokce O. Elliptical rotation flap for pilonidal sinus. *Am J Surg* 2006;191:142.

Author Help: Reference checking facility

The manuscript system (www.journalonweb.com) allows the authors to check and verify the accuracy and style of references. The tool checks the references with PubMed as per a predefined style. Authors are encouraged to use this facility before submitting articles to the journal.

- The style as well as bibliographic elements should be 100% accurate to get the references verified from the system. A single spelling error or addition of issue number / month of publication will lead to error to verifying the reference.
- Example of a correct style
Sheahan P, O'leary G, Lee G, Fitzgibbon J. Cystic cervical metastases: Incidence and diagnosis using fine needle aspiration biopsy. *Otolaryngol Head Neck Surg* 2002;127:294-8.
- Only the references from journals indexed in PubMed would be checked.
- Enter each reference in new line, without a serial number.
- Add up to a maximum 15 reference at time.
- If the reference is correct for its bibliographic elements and punctuations, it will be shown as CORRECT and a link to the correct article in PubMed will be given.
- If any of the bibliographic elements are missing, incorrect or extra (such as issue number), it will be shown as INCORRECT and link to possible articles in PubMed will be given.