Published online: 2020-05-14

Free full text on www.ijps.org

Original Article

Orbicularis oris musculomucosal flap for anterior palatal fistula

V. K. Tiwari, Sujata Sarabahi

Department of Burns and Plastic Surgery, Safdarjung Hospital, New Delhi, India

Address for correspondence: Sujata Sarabahi, B-18, 1st floor, Kailash Colony, New Delhi - 110 048, India.
E-mail: ssarabahi@yahoo.co.in

ABSTRACT

Anterior palatal fistulae or residual anterior clefts are a frequent problem following palatoplasty. Various techniques have been used to repair such fistulae, each having its own advantages and disadvantages. We have successfully used orbicularis oris musculomucosal flap to close anterior fistula and residual clefts in 25 patients. This study shows the superiority of this flap over other techniques because of its reliable blood supply, easy elevation and transfer to fistula site and finally because it is a single-stage procedure.

KEY WORDS

Labiobuccal sulcus, musculomucosal flap, palatal fistula

INTRODUCTION

The most common complication following palatoplasty is a fistula or a residual cleft in the anterior palate. Fistulae occur more frequently after repair of a complete cleft of the primary and secondary palate than after isolated secondary palate repair. The main reasons for anterior palatal fistula are inadequate anterior repair at primary surgery of the lip in a complete cleft, infection, hematoma, excess tension on repair or flap necrosis. Fistulae can be large or small. Small defects can be ignored but large defects cause significant functional problem in speech and nasal regurgitation of food and fluids and therefore have to be repaired early. There is considerable scarring in the palate after palatoplasty because of raising of mucoperiosteal flaps. Hence, even though local palatal flaps can be used to close the fistula, the mucoperiosteum which is stiff and scarred by previous procedures, is difficult to transpose. Also, it will further increase the scar tissue which causes deformities in the maxillary arch because of its contracture. Therefore, labiobuccal flap, which includes the orbicularis oris muscle along with the mucosa, being a regional flap is a better alternative to local palatal tissue for repair of these fistulae. It is a safer flap because of its well-defined blood supply. The advantage of including the muscle with the mucosa is that in all such cases the lip has also been operated upon so there is a scar line in the lip and buccal sulcus. So if the mucosa is raised alone then only a small random pattern flap can be raised. Since muscle is included along with mucosa, the superior labial artery along with its branches is included in the flap base. As these branches supply the muscle, a longer flap can be raised, which increases its reach till the anterior two-thirds of the hard palate. It can also be combined with bone grafting because of the extra vascularity provided by the muscle.

MATERIALS AND METHODS

We have operated on 25 patients [Table 1], of which 10

Table 1: Details of cases

Sr. No.	Age	Sex	Defect (U/L or B/L)	Size defect (cm)	Flap of (U/L or B/L)	Result
1.	4 yrs	M	U/L	0.5 x 1	U/L	Good
2.	5	M	B/L	1.5 x 2	U/L	Good
3.	8	M	U/L	1 x 1	U/L	Good
4.	6	F	U/L	1.5 x 1.5	U/L	Good
5.	10	M	U/L	1.5 x 2.5	B/L	Partial necrosis residual fistula+
6.	15	M	U/L	0.5 x 1	U/L	Good
7.	4	F	U/L	0.75 x 1	U/L	Good
8.	6	F	U/L	2 x 2	U/L	Good
9.	12	F	B/L	2 x 2.5	U/L	Partial necrosis no residual fistula
10.	15	F	U/L	1 x 1	U/L	Partial necrosis no residual fistula
11.	5	F	B/L	0.5 x 1	U/L	Good
12.	10	F	U/L	2 x 2	B/L	Good
13.	8	M	U/L	1.5 x 2	U/L	Good
14.	5	F	U/L	1 x 1	U/L	Good
15.	4	F	B/L	2 x 2	U/L	Good
16.	6	M	U/L	2.5 x 2.	B/L	Good
17.	10	F	U/L	1 x 2	U/L	Good
18.	8	F	U/L	2 x 2.5	B/L	Good
19.	13	M	U/L	2 x 2	U/L	Good
20.	11	F	U/L	1.5 x 1.5	U/L	Good
21.	9	F	B/L	2.5 x 2.5	B/L	Partial necrosis residual fistula+
22.	10	M	U/L	2 x 1.5	U/L	Good
23.	10	F	U/L	1 x 2.5	U/L	Good
24.	6	F	U/L	1.5 x 1.5	U/L	Good
25.	5	M	U/L	2 x 2.5	U/L	Good

U/L - Unilateral, B/L - Bilateral

were male and 15 were female aged 5 to 15 years. Of these, 20 patients had undergone a primary push back palatoplasty using mucoperiosteal flaps for unilateral complete clefts of the primary and secondary palate (Group III Ritche -Davis) and five patients had undergone the same for bilateral complete clefts. Fifteen patients had already undergone a previous repair for anterior fistula using some local palatal tissue and hence had excessively scarred palate. The width of the fistulae varied from 0.5 to 1.5 cm and length varied from 0.5 to 2.5 cm.

Anatomy of the flap [Figures 1A-1C]

The superior labial artery on the lateral side of the cleft lip follows the course of the orbicularis muscle bundles and the edge of the cleft upwards to the nasal ala where it anastamoses with the lateral nasal or angular artery. The flap is raised from the labiobuccal sulcus based superiorly proximal to the scar line of the operated lip. Inferiorly, the scar line is included as the margin of the flap, making it a 'L' shaped flap. Hence the flap is based on the branches of the superior labial artery (which runs along the vermilion of the repaired lateral segment) which are given off proximal to its terminal end which had been ligated or cauterized during lip repair. A good chunk of the orbicularis oris muscle included in the flap is supplied by these branches thus making it a myomucosal flap.

Operative procedure

The nasal lining in all cases was provided by raising hinge flaps a - a" [Figure 1] from the margins of the defect. Following this the actual defect for which the oral lining cover was required could be assessed. Of the 25 patients, a unilateral labiobuccal musculomucosal flap was raised in 20 patients from the same side as the cleft and bilateral flaps were raised in five patients in whom the defect was larger. Everting the lip and cheek, the parotid duct opening was localized. Then the flap was marked and raised including the mucosa and the underlying orbicularis oris muscle till the periosteum. The distal most end of the flap can extend till the parotid duct opening depending on the length of the flap required [Figure 1A].

The superior margin of the flap runs 3 mm above the gingival margin and extends till the scar line of the repaired lip. The inferior margin stops before the scar line at a distance 'X' which is equal to the width of the flap 'Y', thus raising an 'L' shaped flap based on the superior labial artery which runs in the margin of the vermilion. The donor defect was closed primarily by interrupted sutures. This flap was then transposed through the cleft in the alveolar arch to the fistula and sutured to the margins of the oral lining of the palate around the fistula to provide cover over the hinge flap [Figure 1C].

In four cases the alveolar arch had no visible cleft with all teeth in position. As a result the flap pedicle passed over the lateral incisor / canine tooth and was likely to be bitten off between occluded teeth postoperatively. Therefore, a plastic protector was made and placed over the dentition at the end of operation to protect the pedicle.

In five cases the residual cleft was large and midline in

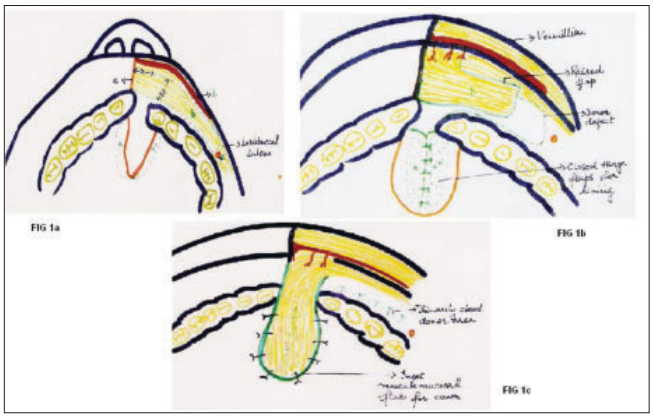

Figure 1: 1A - showing markings for the flap. a, a" – hinge flaps. b - 'L' shaped labiobuccal musculomucosal flap. c - Parotid duct opening. d - Superior labial artery. e - scar line of repaired lip. x = y (x – base of pedicle , y – width of flap). 1B. Showing raised flap. 1C. Showing inset flap

Figure 2: Large anterior palatal fistula in a repaired bilateral cleft lip and palate. B. Lip divided for secondary revision along with marking of the flap. C. Postoperative view showing healthy inset flap with no residual fistula

position and single flap was insufficient to cover the defect. In these cases, bilateral orbicularis oris musculomucosal flaps were raised and transposed to completely cover the defect. In two cases the procedure was combined with secondary revision of the lip of same side.

This was largely a single-stage procedure and did not need division of the pedicle as it passed through the cleft in the arch, except in the four cases in which the flap passed over the permanent dentition.

RESULT [TABLE 1]

The flap healed without any complication in 21 cases [Figures 2-3]. In four cases in whom the dentition impinged upon the pedicle of the flap, the flap was partially lost as the bite block could not be maintained as these patients were all children. However, the hinge flap provided adequate cover to the fistula and there

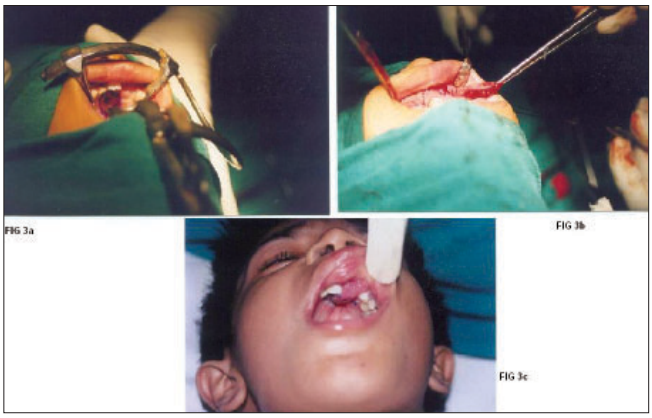

Figure 3: Preoperative view of anterior palatal fistula with marking of hinge flaps. B. Preoperative view showing raised flap. C. Postoperative view of healthy inset flap with no fistula

was no residual defect in two cases. In the remaining two cases there was a residual fistula which needed a secondary repair at a later stage.

DISCUSSION

Anterior palatal fistulae have been closed by conventional methods by various surgeons using local, regional or distant tissue.[1] Most often either hinge flaps alone or along with local advancement flap, rotation flap[2] or palatal island flap[3] are used for small fistulas.

Lehmann[4] used Veau flaps with buccal mucosal flap for fistula closure along with bone graft to fill bony defect. Herbert[5] used bilateral mucoperiosteal island flap as lining and cover both, for middle third fistulas in unscarred palate. But in postpalatoplasty cases with large fistulas, local mucoperiosteal flaps cannot move much because of severe fibrosis and scarring from primary surgery. Furthermore, if palatal mucosa is again widely mobilized and raised, there is more scar contracture which hampers maxillary growth and causes arch deformities also. For such cases regional tissue or distant tube pedicle flaps from the arm or abdomen[6,7] were considered to be a better option.

Large palatal fistulae were first shown to be successfully managed by tongue flap by Guerro-Santos and Altamirano[8] and later by Pigott *et al*, Qattan, Guzel *et al*.[9-11] and many other authors. However, it has the disadvantage of being a two-stage procedure with anticipated intubation and extubation difficulties, risk of flap separation because of tongue movement,

aesthetically unpleasant bulky tissue, postoperative tongue deformity with articulation defects.

In the past two decades, the buccal mucosa with buccinator muscle has also been widely used for cleft palate repair[12] and for palatal fistula repair.[13] Though it has a reliable blood supply with no donor site morbidity, it is a two-stage procedure. It was useful mainly for fistulae in the middle third and posterior third of the palate and unreliable for anterior hard palate fistulae.

Rintala[14] used the labiobuccal mucosal island flap with hinge flaps for anterior fistulae and residual clefts but since it was a random mucosal flap with no specific vascular supply its length was limited.

Another random pattern buccal mucous membrane flap from gingivobuccal sulcus has been used by Hirshowitz and Mahler[15] for alveolar clefts where canine and first molar tooth are missing.

The principal advantages of our orbicularis oris musculomucosal flap are as follows:

1) It is a safer and more reliable flap as compared to other local transposition flaps because of its well-defined blood supply. It can therefore be combined with bone grafting as the muscle provides extra vascularity.
2) The length of the flap is not a limitation usually as in the case of a mucosal flap where the maximum dimension is 2:1. In our flap, since the orbicularis oris muscle is included with the superior labial artery branches, a longer flap can be safely raised. This increases its reach till the anterior two-thirds of the hard palate.
3) There is no donor site morbidity as the donor site is closed primarily in contrast to the tongue flap where there may be severe postoperative tongue deformity along with speech and taste impairment. Also mouth opening is not restricted postoperatively as in the case of cheek flap, where a large flap is raised and donor area is closed primarily.
4) No anesthetic complications seen as encountered during tongue flap division where usually there are intubation difficulties.
5) Normal diet may be resumed soon after surgery.
6) The flap closely resembles the palatal mucosa in texture and consistency compared to tongue flap.

The only limitation of our flap is seen in cases where the entire dentition is intact with no cleft in the alveolar arch because of which the flap pedicle runs over the teeth and is likely to be bitten off if a bite block is not maintained properly postoperatively.

REFERENCES

1. Schultz RC. Management and timing of cleft palate fistula repair. Plast Reconstr Surg 1986;78:739-47.
2. Rintala AE. Surgical closure of palatal fistulae: Follow-up of 84 personally treated cases. Scand J Plast Reconstr Surg 1980;14:235-8.
3. Henderson HP. The tadpole flap: An advancement island flap for the closure of anterior palatal fistulae. Br J Plast Surg 1987;35:163-6.
4. Lehman JA Jr, Curtin P, Hass DG. Closure of anterior palatal fistulae. Cleft Palate J 1978;15:33-8.
5. Herbert DC. Closure of a palatal fistula using a mucoperiosteal island flap. Br J Plast Surg 1974;27:332-6.
6. Reid Campbell DA. Fistulae in hard palate following cleft palate surgery. Br J Plast Surg 1962;13:377-86.
7. Padgett EC. The repair of cleft palates after unsuccessful operations. Arch Surg 1930;453-72.
8. Guerrero-Santos J, Altamirano JT. The use of lingual flaps in repair of fistulas of hard palate. Plast Recontr Surg 1966;38:123-8.
9. Pigott RW, Reiger FW, Moodie AF. Tongue flap repair of cleft palate fistulae. Br J Plast Surg 1984;37:285-93.
10. Al-Qattan MM. A modified technique of using the tongue tip for closure of large anterior palatal fistula. Ann Plast Surg 2001;47:458-60.
11. Guzel MZ, Alintas F. Repair of large anterior palatal fistulas using thin tongue flaps: Long term follow up of 10 patients. Ann Plast Surg 2000;45:109-17.
12. Maeda K, Ojiki H, Utsugi R, Ando S. A T-shaped musculomucosal buccal flap method for cleft palate surgery. Plast Reconstr Surg 1987;79:888-96.
13. Nakakita N, Maeda K, Ando S, Ojimi H, Utsugi R. Use of a buccal musculomucosal flap to close palatal fistulae after cleft palate repair. Br J Plast Surg 1990;43:452-6.
14. Rintala A. Labiobuccal mucosal island flap for closure of anterior palatal fistulae. Scand J Plast Reconstr Surg 1979;13:480-2.
15. Hirshowitz B, Mahler D. Two surgical procedures for closure of palatal fistulae. Cleft Palate J 1970;685-9.