

Case Report

Blast injury lower face: An unusual and rare case

A. Soni

Department of Burns and Plastic Surgery, MP Shah Medical College, Jamnagar, Gujarat, India

Address for correspondence: Ashutosh Soni, C-17, Medical Campus, MP Shah Medical College, Jamnagar - 361 008, Gujarat, India.
E-mail: drashutoshsoni@yahoo.co.in

ABSTRACT

Isolated blast injuries of the face are rare and injuries due to blasting of low voltage batteries in or near the mouth are even rarer. We present here a case of an 18 year old boy who suffered from extensive injury and tissue loss involving the lower half of the face due to blasting of a low voltage battery used in a flash light due to apparent shortcircuiting when the boy put the two short wires connected to a low voltage battery in his mouth in order to deinsulate them. This resulted in a blast leading to severe injuries and tissue loss which included the lower nose, upper lip, all teeth, both cheeks, floor of mouth tongue, chin, the maxilla and mandible.

KEY WORDS

Blast injury, defect, delto pectoral flap, pectoralis major osteo-myo-cutaneous flap, reconstruction, low voltage battery

INTRODUCTION

Facial injuries are common in today's times due to vehicular and industrial trauma, explosions, assault, warfare etc. but isolated blast injury of face due to low voltage electrical sources are extremely rare.^[1,2]

Most facial blast injuries are due to firecrackers, warfare, bombs, gunshots, etc.

The injury may involve part or whole of the face with resultant loss of tissue and defects that may be involving various structures of the face ranging from skin to the bony skeleton; the resultant defect leading to cosmetic and functional losses to the patient.

Various modes of reconstruction have been described in literature for reconstruction of facial defects for soft tissues and bone- ranging from local flaps and regional flaps to free flaps.

CASE REPORT

A young man of 18 years of age was referred to the Department of burns and plastic surgery with a history of 'bursting of a bomb' in the patient's mouth.

The patient was in a state of shock and fear, with restlessness and distress, due to pain, bleeding and difficulty in breathing.

On detailed enquiry it was found that there was a blast of a low voltage battery (used in flash lights) [Figure 1] very close to the patients mouth after the patient shook the battery and was removing the insulation (plastic covering) of both wires simultaneously with his mouth so as to connect the battery to play his tape recorder. Suddenly the battery exploded with resultant severe injury of the lower half of his face leading to tissue destruction and defects. The patient had been referred to our tertiary centre from a local rural health centre after first aid.

The areas injured included the lower part of the nose including both ala and columella, upper and lower lips, the maxilla, compound comminuted fractured of the mandible with loss of the central part, both medial cheeks, anterior part of the tongue (which was lacerated), floor of the mouth and teeth [Figure 2].

On examination, active bleeding had stopped and there was no CSF leak. Rest of the body including all four limbs were unaffected. A tracheostomy was done under local anaesthesia and after preliminary assessment and examination it was decided to salvage the tissues that could be saved and do a debridement of all the dead tissues. The nose, cheeks, tongue and floor of mouth were repaired as far as possible and the remaining tissues were sutured and anchored [Figure 3].

After a week, the defect of the lower part including the lost central mandible, lower lip and chin regions were reconstructed with a pedicled-pectoralis-major osteo-myo-cutaneous (PMMC) flap and delto-pectoral (DP) flaps; the pedicled- pectoralis-major osteo-myo-cutaneous flap with the sixth rib being used for the lining and mandible replacement and the delto -pectoral flap was used to provide the cover [Figure 4].

Looking at the bulk of the PMMC flap, the pedicle was not tunnelled through the skin but kept outside and covered with a split skin graft. Both the pedicled flaps ie pectoralis- major osteo- myo -cutaneous flap and delto-pectoral flaps were detached after three weeks and formally inset.

The final result of this reconstruction is seen in Figures 5 and 6.

The patient was initially fed with a Ryles tube till the definitive first stage reconstructive surgery and for a week after the reconstruction using the pedicled flaps; subsequently he was allowed to take liquids orally; later he could take semi solids by mouth after about 2 weeks of final flap inset At the time of discharge he was taking semisolids by mouth. A plan for reconstruction of the upper lip was planned in the next stage but the patient did not turn up for follow up.

DISCUSSION

Facial injuries are generally associated with warfare^[3,4]

or in civilian settings can be due to fireworks, vehicular accidents, letter bomb injuries, bottle blasts etc.^[5-7] Very few cases of similar injuries have been reported in literature,^[1,2] which makes our case even more interesting due to its rarity.

Low voltage electrical source like car battery, flash light battery etc., used in homes, in appliances, for inverters etc., are frequently improvised for domestic lighting and playing musical instruments in our rural areas. Facial injury due to low-voltage electrical sources and by flow of heavy current due to short-circuiting a low-voltage battery is extremely rare.^[1]

Low voltage batteries contains a tremendous amount of energy. The low internal resistance of such a battery, when short-circuited, permits the flow of heavy current. Short-circuiting of wires instantaneously vaporizes a minuscule portion of wire at approximately 2000 K resulting in a blast in closed cavity^[1] causing sudden rise of intraoral pressure which can lead to extensive damage of circum oral structures.^[1]

Facial injury is not life threatening unless it is associated with airway problems.^[8]

The major risks to the airway in patient's management with massive facial trauma are due to anatomic alteration of airway patency through bony disruption, soft tissue swelling and the increased potential for aspiration of body fluids.^[9]

It is quite common for the young patients to do manoeuvres in ignorance, which can prove dangerous and may produce grievous injury. A small lapse in precaution can lead to not only physical trauma but also psychological trauma and distress due to facial disfigurement.

The present case stresses the importance of the need to educate the general public and make them more aware regarding proper and careful handling of household low voltage electric and other appliances.

The plastic surgeon, when treating a patient with massive loss of soft tissue and bone of the face secondary to blast injury, must carefully consider available treatment options.^[10] The choice of procedure should be dictated by the likelihood of success, donor site morbidity and



Figure 1: Replica of the low voltage battery of a flash light that caused the blast injury

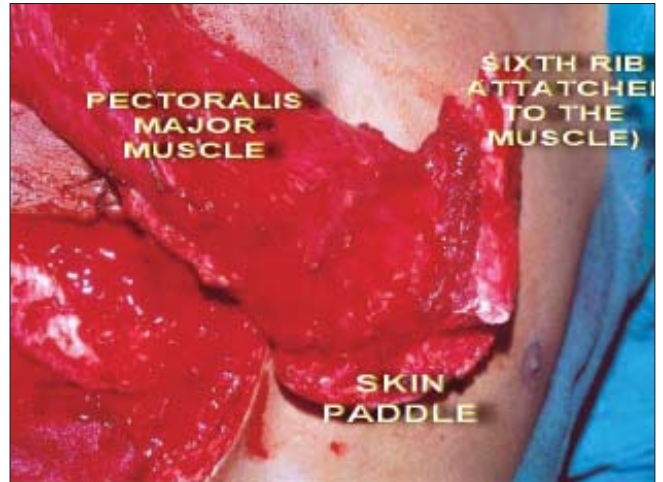


Figure 4: The Pectoralis major osteo myo cutaneous flap used in the reconstruction of the defect

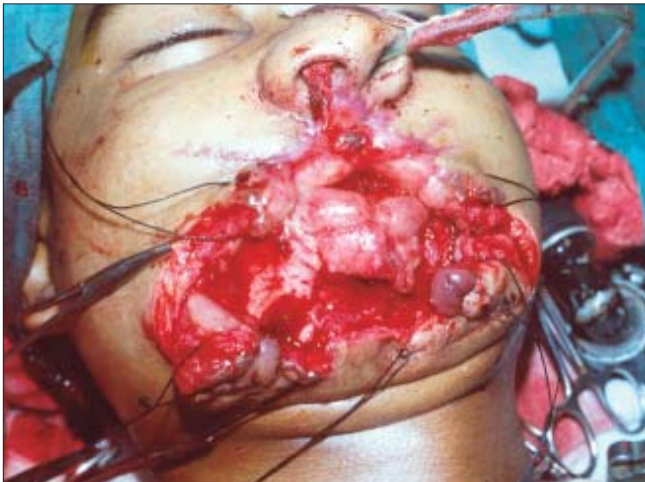

Figure 2: Tissues lost by the blast injury

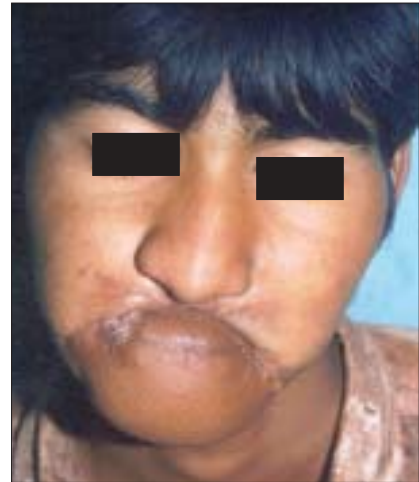

Figure 5: Post operative photo at 3 months-front view

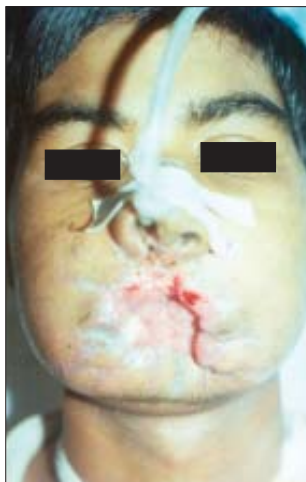

Figure 3: Photograph after the first stage surgery to salvage the tissues

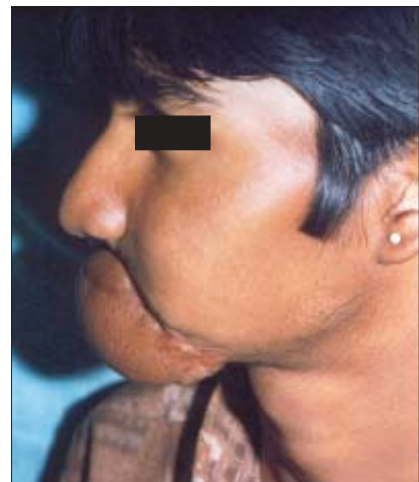

Figure 6: Post operative photo at 3 months-side view

the potential for complications.^[11] We chose this procedure as we were familiar with head and neck reconstructions using the PMMC and DP flaps. Follow

up was lost because the young man was a tribal person probably on the move and he did not come back to our city again.

REFERENCES

1. Singh SK, Jain P, Sinha JK. Extensive facial damage caused by a blast injury arising from a 6 volt lead accumulator. *Br J Plast Surg* 1999;52:149-51.
2. Bhadani U, Tripathi M, Ramraj PN, Singh I. Silent Blast in Oral Cavity: Is the Car Battery Innocuous? *Indian J Pediatr* 2005;72:367.
3. Danic D, Progmet D, Milicic D, Leovic D, Puntric D. War injuries to the head and neck. *Mil Med* 1998;163:117-79.
4. Shuker T. Maxillofacial blast injuries. *J Craniomaxillofac Surg* 1995;23:91-8.
5. Jamara FA, Halasa A, Salman S. Letter bomb injuries: A report of three cases. *J Trauma* 1974;14:275-9.
6. Efrati Y, Sarfaty S, Klin B, Eshel G, Segal S, Vinograd I. Oral blast injury caused by an accident. *Ann Otol Rhinol Laryngol* 1993;102:528-30.
7. Hubbard TJ, Dado DV, Izquierdo R. Massive craniofacial injuries from recreational fire works: A report of three cases. *J Trauma* 1992;33:767-72.
8. Ardekanian L, Rosen D, Klein Y, Peled M, Michaelson M, Laufer D. Life-threatening complications and irreversible damage following maxillofacial trauma. *Injury* 1998;29:253-6.
9. Cantrill SV. Massive facial trauma and direct Neck Trauma. *In: Robert H. Dailey, Barry Simon, Gary P. Young, Ronald D. Stewart. The Airway: Emergency Management. Mosby Year book Inc; 1992. p. 259-69.*
10. Pensler JM, Rosenthal AJ. Reconstruction of the oral commissure after an electrical burn. *Burn Care Rehabil* 1990;11:50-3.
11. Close LG, Lomba JA. Facial reconstruction following blast injury. *Head Neck Surg* 1983;6:639-52.

NOTICE

Dear Colleague,

We are pleased to announce you the international symposium "Virtual Diagnosis and Treatment Planning of Cranio-Maxillo-Facial Deformity" which will take place on November 10th, 2006 in Bruges, Belgium.

The symposium is organized by the Division of Maxillo-Facial Surgery, Department of Surgery in close collaboration with the Department of Radiology and Medical Imaging, General Hospital St.-Jan, Bruges, Belgium. The symposium intends to present state-of-the art lectures. There will be no free papers.

Additional to the symposium, two limited attendance workshops will be organized on November 11th, 2006 in Bruges, Belgium.

Workshop 1: 3D dental model analysis by A. Kuijpers-Jagtman DDS PhD, FDSRCS Eng, Nijmegen

Workshop 2: 3D cephalometry by G. R. J. Swennen MD DMD PhD, Bruges

*Both work-shops consist of hands-on teaching on individual PC and are limited to 30 participants

The symposium and limited attendance workshops will be hold in the recently renovated Congress Centre " Site Oud Sint-Jan", located on the spot of the former historical "Sint-Jan" hospital in the historical centre of Bruges. The city of Bruges in known for its beautiful canals, historic buildings, museums and its gastronomy.

Attached you will find the digital preliminary announcement. The final announcement will be forwarded by e-mail in April 2006.

We cordially invite you to attend the symposium and/or limited attendance workshops and sincerely hope to welcome you in Bruges.

Best regards,

The organizing committee

Registration is already possible by sending an e-mail message at:

E-mail: 3D@azbrugge.be or info@ireenrientjes.nl

For further information, please contact the course secretary:

Ireen Rientjes Congresorganisatie

Kalmarstraat 25

7559 JA Hengelo, The Netherlands

Tel./fax: 0031 74 2782983