

## Original Article

# 'Sure closure'—skin stretching system, our clinical experience

K. I. Subramania, S. Mohit, P. R. Sasidharan, M. K. Abraham, P. Arun, V. Kekatpure

Department of Head and Neck/Plastic and Reconstructive Surgery, Amrita Institute of Medical Sciences, Kochi, Kerala, India

**Address for correspondence:** KI Subramania Iyer, Department of Head and Neck/Plastic and Reconstructive Surgery, Amrita Institute of Medical Sciences, Kochi, Kerala, India, E-mail: [subu@aimshospital.org](mailto:subu@aimshospital.org)

### ABSTRACT

**Objective:** In clinical practice of reconstructive surgery one of the problems one routinely comes across is skin and soft tissue defects, which require coverage. Coverage of such wounds requires primary/secondary closure, skin grafting or flaps. The objective of our clinical series was to assess the efficacy of sure closure skin stretching system for closure of defects which otherwise would have required major flap cover or skin grafting.

**Methods:** Our series included five patients with different causes and types of wound defects namely:

1. Post-traumatic soft tissue defect on dorsum of hand.
2. Post fasciotomy wound on leg (anterolateral aspect).
3. Abdominal wound dehiscence following surgery for enterocutaneous fistula.
4. Leg soft tissue defect following dehiscence of fasciocutaneous flap.
5. Secondary defect following harvesting a lateral arm/forearm free flap.

The device was applied to skin edges after preparing the wound under local anesthesia and the skin edges were brought together by turning the skin-stretching knob. After adequate approximation of the edges of the wound it was sutured by conventional suturing techniques.

**Results:** All the wounds could be successfully closed using the skin stretching system in our series. The time taken for the closure ranged from 2 to 48 h.

**Conclusions:** Sure closure skin stretching system is an effective device for closing some of the skin defects which otherwise would have required skin flaps or grafts. In all the patients wound closure could be achieved by this method and was carried out under local anesthesia. Use of this technique is simple and helps to reduce the morbidity and cost of treatment by allowing the reconstructive surgeon to avoid using major flaps or grafts.

### KEY WORDS

Skin defects, Skin closure, Sure closure device

Management of skin defects which are not amenable to primary wound closure necessitates the use of bigger procedures like skin flaps or grafts. Stretching of the skin either slow or rapid has been found to be an effective way to achieve primary closure of these defects. Sure closure skin stretching device is

designed to bring the skin margins together rapidly so that they may be safely sutured or stapled, using conventional methods. By applying a controlled amount of tension evenly along the wound margin this system uses the viscoelastic properties of skin to cause it to rapidly stretch and extend while minimizing its tendency to recoil. This process is

known as 'mechanical creep'. The amount of tension applied can be monitored clinically and as the skin stretches additional tension can be applied incrementally in repeated cycles until the skin margins are brought into close approximation for suturing. The wound is then closed and the device can then be removed.

## MATERIALS AND METHODS

Five patients with skin defects which otherwise would have required skin flaps or grafts were included in the study. The defects included post-traumatic soft tissue defect on dorsum of hand, post fasciotomy wound on leg, abdominal wound dehiscence following surgery for enterocutaneous fistula, tissue defect of the leg following dehiscence of fasciocutaneous flap and secondary defect following harvesting a lateral arm/forearm.

A rapid skin-stretching device (Sure Closure<sup>®</sup>) was used in these cases to achieve closure of the defects. The device contains:

1. Two U arms with pins;
2. Two intradermal pins;
3. Locking mechanism;
4. Tension indicator.

Wound was cleaned and prepared and local anesthesia was given. The two long transfixing pins were inserted 5 cm from the wound margin along the longitudinal axis of the wound. The 'U' arm was now fixed in such away that the sharp hook shaped needles engaged the skin beyond the long needles.

The device was then locked and ready for stretching.

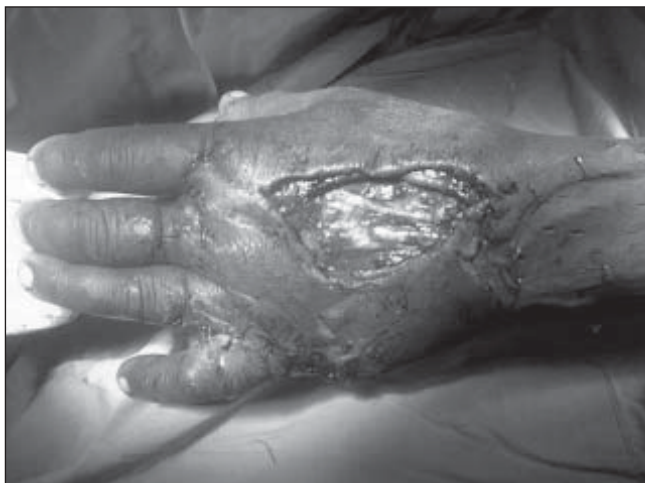

Figure 1: post-traumatic defect dorsum of hand

Stretching was now started by turning the tension knob clock wise which brought both 'U' arms together and starts approximating the skin edges. (In the refined version of the device, which is available now and has been used by us this is achieved by pressing the arms together). The knob turning was continued until the patient felt discomfort or there was either blanching or shininess at the wound edges. The device incorporates a safety mechanism in the form of a tension indicator and it can be used to avoid overstretching at anytime. As the skin stretched over time tension on the bar was reduced and was reflected by the reference tension indicator and further stretching could be achieved by turning of the knob clockwise. This procedure was repeated until wound margins were approximated so they could be sutured or stapled together. The application of the technique in our cases is as follows.

### Case 1

A 51-year-old male patient was seen with a traumatic defect on dorsum of hand leading to exposed tendons. Dimension of wound was 6.5 cm and would have required a skin flap for closure of the defect. The skin-stretching device was applied and incremental stretching done over a period of 24 h closed the defect. [Figure 1, 2, 3, 4]

### Case 2

A 46 years male who had an embolic occlusion of the popliteal artery followed by compartment syndrome underwent successful embolectomy but needed fasciotomy on the leg resulting in a large raw area. The wound measured 8 x 5 cm and would have needed a skin graft for closure. The skin stretching device was applied on the fourth postoperative day and closure of the wound could be achieved in 3 h. [Figure 5, 6, 7]

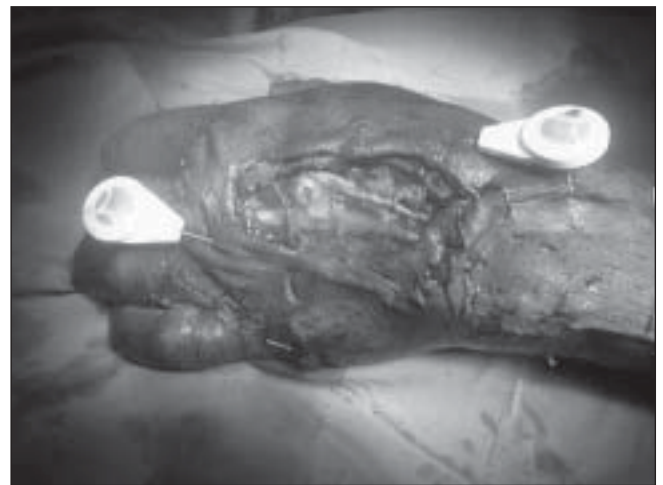

Figure 2: Intradermal pins applied

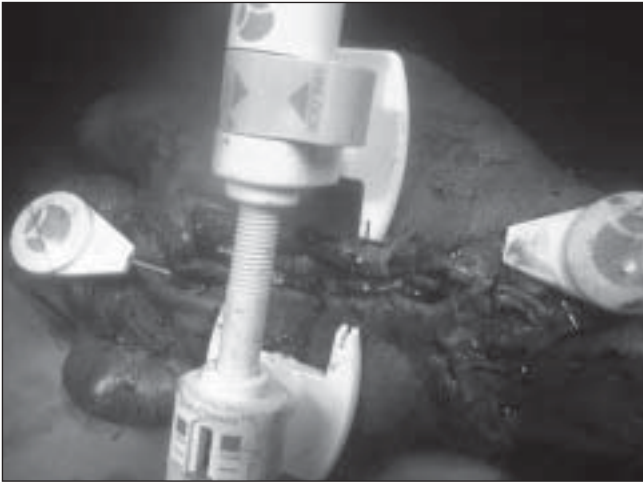


Figure 3: Sure Closure device in place




Figure 6: Sure closure device in place

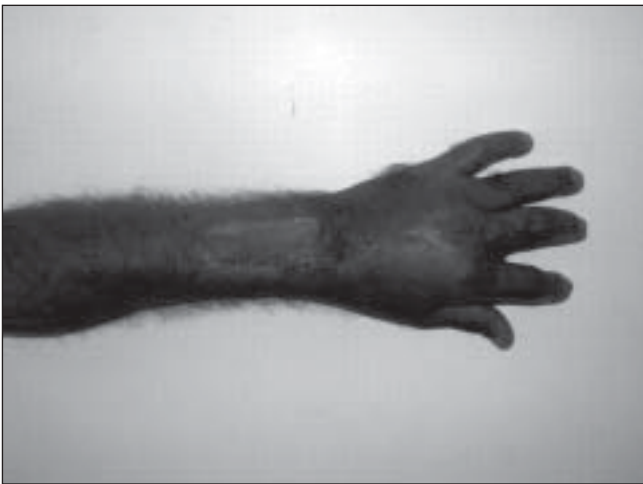

Figure 4: Healed wound 3 month postoperative

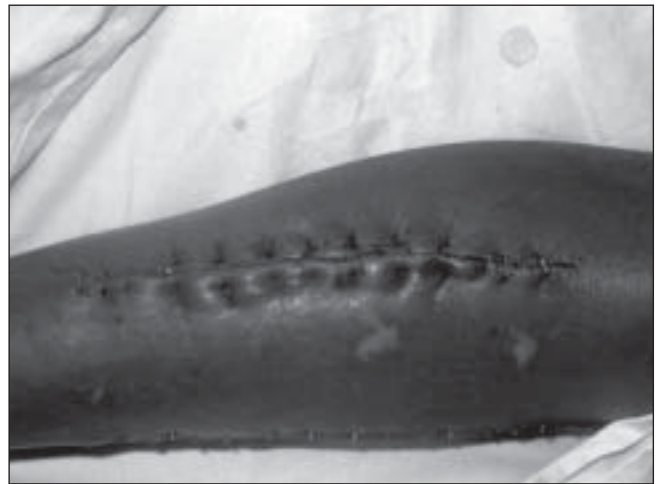

Figure 7: Closed wound

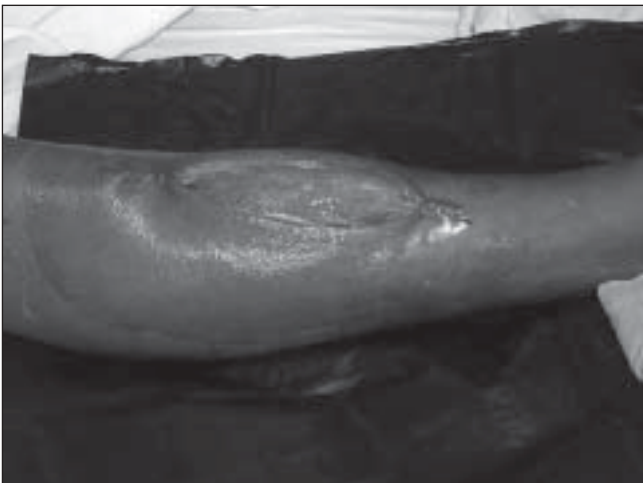

Figure 5: Post fasciotomy wound leg

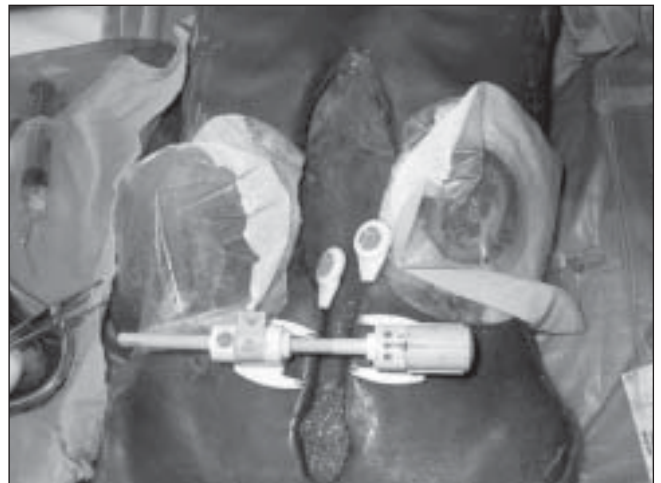

Figure 8: Application in abdominal wound dehiscence

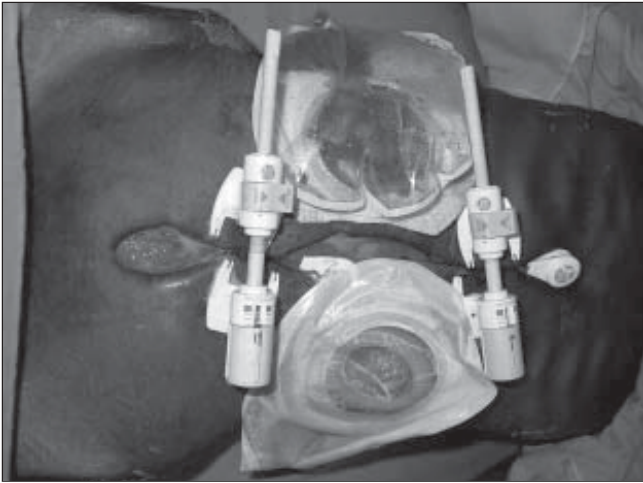


Figure 9: Two devices in place

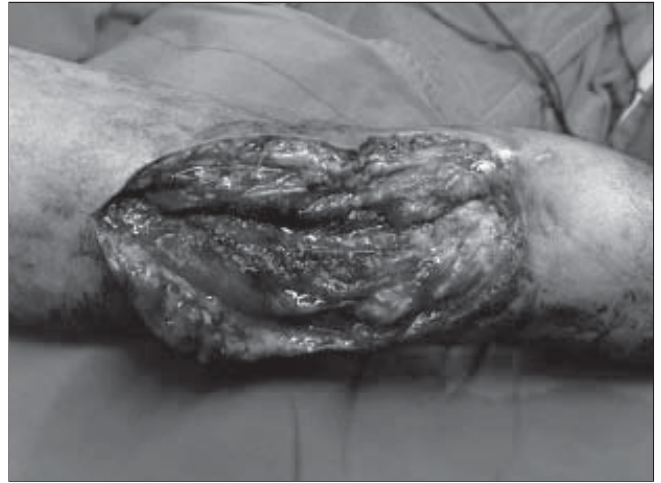

Figure 12: Lateral arm free flap donor site defect

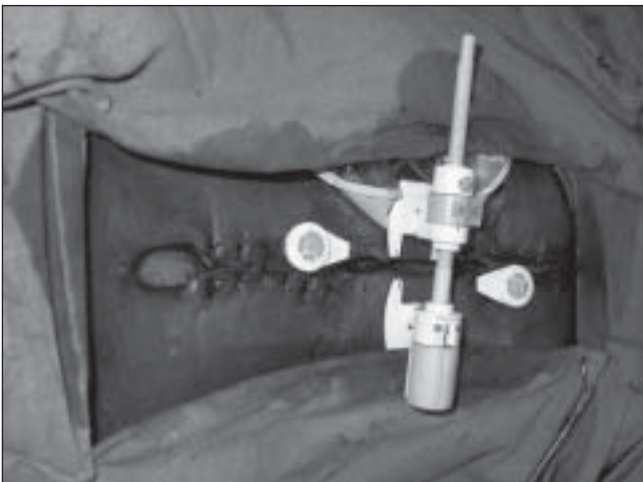


Figure 10: Reapplication of device for the upper end

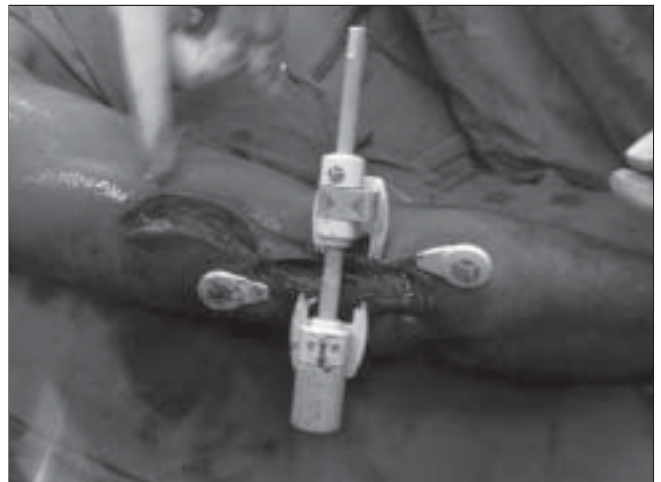

Figure 13: Device in place

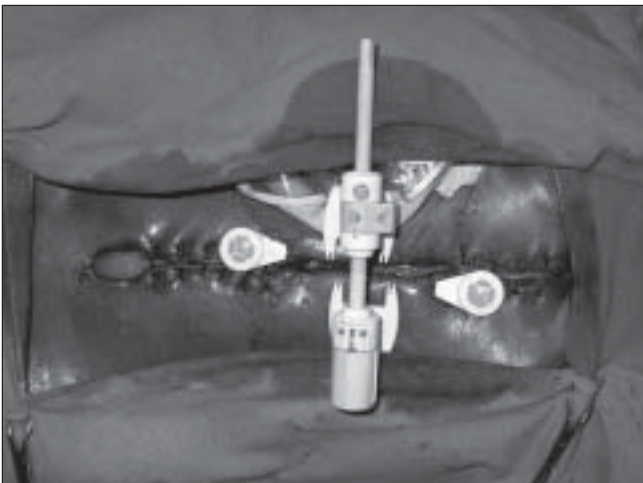


Figure 11: Wound closed, lower end kept open for drainage

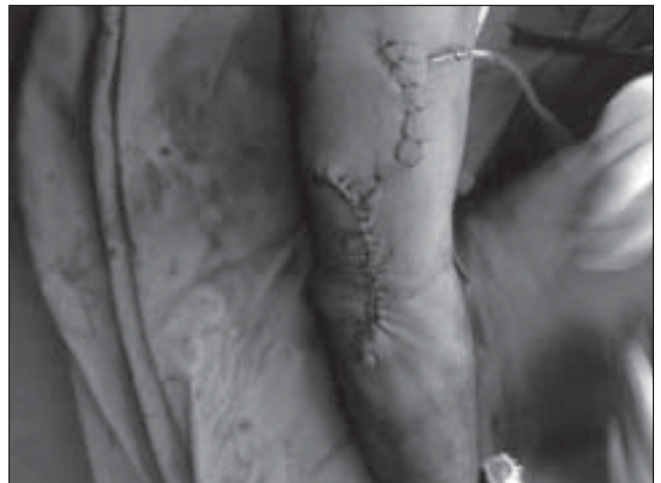

Figure 14: Closed wound

### Case 3

A 35-year-old male patient had blunt abdominal trauma and underwent splenectomy, enteric resection and anastomosis, developed anastomotic leak. He was reoperated but developed enterocutaneous fistula and abdominal wound dehiscence. Both bowel ends were exteriorized and patient had a midline wound of 25 x 8 cm size.

Because of the length of the wound as well as the presence of the two stomas we used two skin-stretching devices and the wound closure could be achieved in 24 h. [Figure 8,9,10,11]

### Case 4

A 52-year-old male patient who underwent partial glossectomy for squamous cell carcinoma was reconstructed by lateral arm flap. To increase the length of vascular pedicle the flap was partly extended to forearm. The forearm skin being more unyielding than the lateral arm, the primary closure of the wound became difficult therefore we opted for skin stretching by sure closure and we were able to close the wound in 40 min completely. [Figure 12, 13, 14]

### Case 5

A 20-year-old male patient had a exposed bone in the leg for which a local transposition fasciocutaneous flap was used. There was dehiscence at one edge of the flap resulting in a defect of 4 x 3 cm. This was subsequently covered using the skin stretching system. But the wound showed dehiscence in part of the area again after 5 days. The edges were freshened and the device was applied again and the skin was approximated. The wound healing was satisfactory after the second procedure.

## RESULTS

We could successfully close the wound in all the five patients in whom we used the skin-stretching device. In all these patients after achieving skin approximation the closure could be achieved by sutures or clips. These wounds healed very well and faced no subsequent problems. In most cases the device could be applied at bedside under local anaesthesia except for one patient where the use was intraoperative. All the patients had good aesthetic and functional results and had stable wound coverage on follow up.

## DISCUSSION

Providing cover for soft tissue defects, which cannot be closed primarily, and the defects, which would not accept skin grafts, has always been a problem for surgeons. The methods adopted by reconstructive surgeons to tackle this situation are local and pedicled flaps as well as microvascular free tissue transfer. These procedures, although indispensable in certain situations can be avoided in few patients by utilizing the property of the skin to expand and stretch. This saves the patient from unnecessary surgery, extra scars, additional morbidity and of course increase in the cost of treatment. The average expenses incurred by a patient for cover of similar defects by procedures ranging from skin grafts, pedicled flaps to free flaps in our institution will come to Rs 5000 to Rs 35000 for the surgery alone. If the sure closure device is used in multiple patients, as we have done in this study the cost of treatment can come down to approximately Rs 3000, that too in many situations can be done without the need of hospital stay.

Many surgeons have utilized the stretch ability of the skin for closure of such skin defects. One way of achieving this is by placing tissue expanders preoperatively. The expanders are filled with saline repeatedly over few weeks to get the desired expansion. In this technique there is stretching and thinning of the dermis and growth of the epidermis by increasing the mitotic activity. But tissue expanders are costly devices and needs to be placed by an operative procedure. The patient has also to bear with the period of discomfort and disfigurement during the period of expansion. Intraoperative rapid tissue expansion is another method where multiple small expanders are placed along the wound edges and rapidly inflated and deflated cyclically leading to the expansion of the skin. But these expanders are costly and need undermining of the surrounding skin with the possible attendant risk of compromised viability.

One of the methods recently described for closure of such soft tissue defects is by the use of a skin stretching system. By using this device a controlled amount of tension is applied along the wound margins. The load is kept constant over time and the skin in accordance to its viscoelastic properties is stretched and extended. Moreover its tendency for recoil is also minimized. The process is known as

'mechanical creep' and does not impair immediate or long-term viability of the skin.

In all the patients we used the device the wound closure could be done successfully. The time taken for the stretching of the skin so as to facilitate closure without tension varied from 40 min to 48h. In our first patient with defect on dorsum of hand, we took 24h to close the wound probably because of lack of experience with the use of device. In subsequent cases we could achieve the closure in considerably shorter time. In the patient with leg fasciotomy wound we faced problems in form of muscle entrapment in between two intradermal pins. This was overcome by manually pressing the muscle down and readjusting the device while the stretching was being carried out. The patient with abdominal wound dehiscence had a very large wound, preventing closure in single sitting. In this case we used two devices, closed the wound partially on day 1 and reapplied one of the devices in central region, after removal of stoma adhesive tape on the next day. Small part of the wound at the lower end was left open to allow for the drainage that could be closed by simple sutures after 2 weeks. This procedure gave us the idea that in large wounds even a single device can be used sequentially to obtain a good result.

The problem with closure was seen only in the patient in whom the device was applied for closure of the fasciocutaneous flap dehiscence. There was an initial failure on the first application but wound could be successfully closed after second application of device and use of tension suture. The wound in this case was indurated and there was fixity of the surrounding skin. In such cases use of the skin-stretching device may not be suitable. To determine the suitability for skin stretching a 'pinch test' should be performed previously.

#### **The possible adverse effects seen with the use of this method of skin closure are**

1. Chance for hypertrophic scars because the skin edges are closed under tension;
2. Local infection due to intradermal placement of pins;
3. Ischemic necrosis of the skin edges if adequate care is not given while stretching;
4. Failure to close the defect because of increased tension

'Sure closure'—skin stretching system, our clinical experience

on the skin. This may happen if there is a clinical judgmental error on the part of the physician.

#### **The contraindications to the use of the skin stretching include**

1. Presence of nonviable or atrophic skin at the edges of the wound;
2. Presence of infection at the wound site;
3. History of local radiation to the area;
4. Inability to maintain a distance of at least 7 mm from deeper vital structures while introducing the intradermal pins;
5. Nearness of wound to structures like eyelids and genitalia.

#### **The notable advantages of using a skin stretching system include**

1. It does not need undermining of the skin edges so that no compromise on the skin viability occurs;
2. It can be done as a bedside procedure;
3. It can be done under local anesthesia;
4. It reduces the cost of treatment and hospital stay.

The skin stretching system utilized in this study has been found to be a safe and effective means for wound closure in a large majority of cases. Its proper use can save the need of major surgical procedures in many patients.

#### **REFERENCES**

1. Hirshowitz B. The two—state face lift. *Br J Plast Surg* 1978;31:159.
2. Hirshowitz B, Kaufman T, Ullman J. Reconstruction of the tip of the nose by load cycling of the nasal skin and harnessing of extra skin. *Plast Reconstr Surg* 1986;77:316.
3. Sasaki GH. Intraoperative Sustained Limited Expansion (ISLE) as immediate reconstructive techniques. *Clin Plast Surg* 1987;14:563.
4. Hirshowitz B, Jack IT. An attempt to harness the visco – elastic properties of skin in face – lifts operations. A preliminary report. *Ann Plast Surg* 1987;18:188.
5. Liang MD, Briggs P, Heckler FR, Futrell JW. Pre – suturing new techniques for closing large skin defects. *Clinical and experimental studies—J plast reconstr Surg* 1988;81:694.
6. Gibson T. The physical properties of skin, in *Plastic Surgery*, McCarthy J Ed 1990;1:207.
7. Hirshowitz B, Linden Baum E, Har–Shai Y. A skin-stretching device for harnessing of the visco–elastic properties of skin. *J Plast Reconstr Surg* 1994;92:260.