

Original Article

Wound coverage of plantar metatarsal ulcers in leprosy using a toe web flap

J. Joshua, V. Chakraborty

Premananda Memorial Leprosy Hospital, The Leprosy Mission, Kolkata, India

Address for correspondence: J. Joshua, Premananda Memorial Leprosy Hospital, 259 A, Acharya Prafulla Chandra Road, Maniktala, Kolkata 700006, West Bengal, India, E-mail: tlmkolkata@tlm-india.org, jerryjoshua@yahoo.com

ABSTRACT

Plantar metatarsal ulcers and sinuses are frequently seen problems in anaesthetic feet in leprosy. They may occur singly or as multiple sinuses. Many flaps have been described in the management of small defects of the forefoot. During the course of four years, from March 2000 to February 2004, a total of 708 plantar metatarsal ulcers in anaesthetic feet due to leprosy were seen. 280 surgeries were performed on 257 cases. Most of these were debridement and or excision of the metatarsophalangeal joints through a dorsal incision. Thirteen cases were dealt with by a toe web flap, using the plantar metatarsal artery as the source of supply to the flap. Nine were to cover defects under the 1st metatarsophalangeal joint. Three were to cover defects under the second and third metatarsophalangeal joints and one involved coverage of a defect under the 5th metatarsophalangeal joint. In all cases except the last, the big toe contributed the flap. In the last case the fourth toe was the donor. In all cases the flaps survived and did well. The secondary defects were covered with split thickness skin graft. Wound dehiscence was seen in one case and recurrence of a sinus, was seen in one case. Hyperkeratosis of the secondary defect was seen in three cases. Follow up ranged from 3 years to six months. We found this flap to be durable and safe with little chance of recurrence when used to cover plantar metatarsal ulcers.

KEY WORDS

Plantar metatarsal ulcers, Plantar metatarsal artery, Digital artery, Leprosy, Toe web flap

INTRODUCTION

Disintegration of the feet is the most common problem faced by leprosy patients and a major part of this is associated with plantar ulceration.

Plantar ulceration serves as both the cause and the effect of such disintegration. Among those with plantar ulceration, ulcers of the forefoot contribute 70% of the total.¹ 55% of ulcers occur over the metatarsal heads¹. These

ulcers over the plantar aspect of the metatarsal heads may occur as sinuses leading down to the underlying structures or as shallow ulcers involving the tissues at various levels.¹ These ulcers occur and recur

1. due to repeated high direct pressure and
2. due to the shearing stresses on the normal tissue or the scar beneath the metatarsal heads on walking².

Where these ulcers have penetrated the underlying tissues down to the bone and into the metatarsophalangeal joint,

there is no choice but to excise the joint through a dorsal incision and salvage as much plantar tissue as possible and minimise the scar on the plantar aspect by closing the plantar wound to promote healing by primary intention.³ When the tissue involvement stops short of bone, then healing by secondary intention can be promoted by immobilisation.

Recurrence of these ulcers is common (8% within one year in our series) in spite of providing appropriate footwear with orthosis to redistribute pressure and minimize shearing stresses. These forces were addressed by providing extra padding in the form of a toe web flap⁴ based on the plantar metatarsal artery and its digital branch. In this paper, the procedure for the toe web flap and the results of this procedure on 13 patients are presented and discussed.

MATERIALS AND METHODS

Of 708 patients with plantar metatarsal ulcers seen over a four-year period, 257 cases underwent dorsal incisions and excision of the metatarsophalangeal joint because of septic arthritis of that joint. Thirteen who had involvement of the underlying tendon or joint capsule without septic arthritis, underwent the toe web flap procedure described below. The rest were treated non-operatively by immobilization alone, as the deeper structures were not involved. In 22 of these cases, the wounds were larger than 3.5cm x 3.5cm and a toe web flap would not have sufficed.

The work was done between 1st March 2000 and 28th February 2004, a total of four years.

Operative technique

Indications

This procedure was performed in patient with plantar metatarsal ulcers or sinuses, not involving the metatarsophalangeal joints in an anaesthetic foot. Defects ranged between 1.5cm x 2cm and 2.5cm x 3.5 cm. The ulcer was shallow or deep involving the tendon or tendon sheath. Chronic inflammation was sometimes present. There was however no infection or cellulites.

Pre-operative preparation

The patient was admitted and taught walking with crutches. All patients who came with infection of the forefoot wound or other sites of infection were treated with a course of broad-spectrum antibiotics preoperatively and the wound

was debrided. Septic tenosynovitis was also dealt with, in addition, by immobilisation in a weight bearing window plaster cast until the discharge from the wound subsided.

Anaesthesia

Spinal anaesthesia was preferred but ankle block anaesthesia was also used.

Procedure

The plantar sinus or ulcer was first excised taking care not to injure the plantar metatarsal artery and its digital branch to the side of the toe donating the flap (usually the lateral aspect of the big toe). The flap of required dimensions was outlined on the lateral aspect of the big toe taking care to avoid the nail and nail bed. A longitudinal incision was marked from the most proximal part of this island flap to the base of the toe (if this was not already occupied by the base of the flap). Then an angular incision was marked to connect this to the defect. (Figure 1-10)

The incision was then made starting from the distal aspect of this flap and including the digital neurovascular bundle of the lateral aspect of the big toe in the flap. This was raised proximally and the flap was islanded incising the skin and subcutaneous tissue superficially at the proximal extent of the islanded flap. The connecting incision between the island flap and the plantar metatarsal defect, which had been marked out already, was made. The plantar digital artery and the plantar metatarsal artery were dissected out along with the plantar digital nerve and the entire neurovascular bundle was raised deep to the superficial transverse metatarsal ligament after cutting this ligament. The flap was laid on the plantar defect and sutured. The connecting incision was also closed and the secondary defect is closed with a split thickness skin graft.

Sutures were removed on the 10th post operative day and when the wounds had completely healed, usually by the 21st post operative day, walking exercises were started. All patients were provided with appropriate orthosis and footwear

RESULTS

Thirteen cases underwent this procedure, nine for defects over the 1st metatarsophalangeal joint, three over the 2nd or 2nd and 3rd metatarsophalangeal joint region and one over the 5th metatarsophalangeal joint region. Three patients were female and ten were male. Their ages ranged

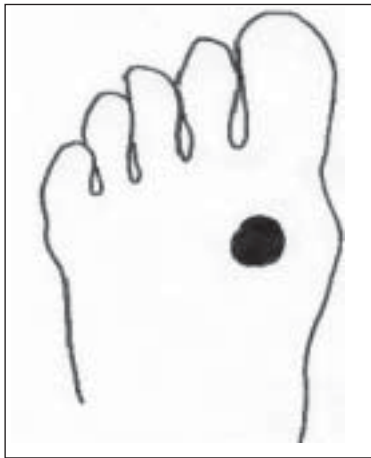


Figure 1: Plantar ulcer beneath metatarso-phalangeal joint

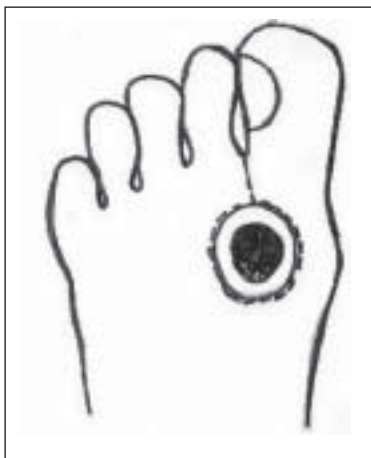


Figure 2: Incisions to excise ulcer, raise flap and dissect the digital vessel

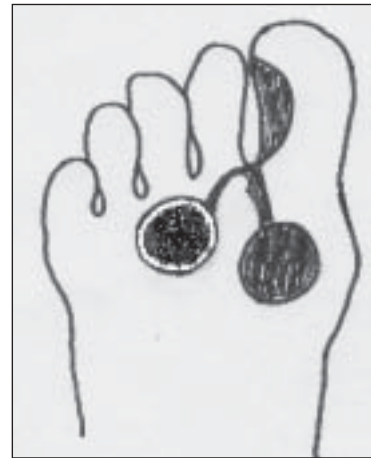


Figure 3: Flap with arterial pedicle

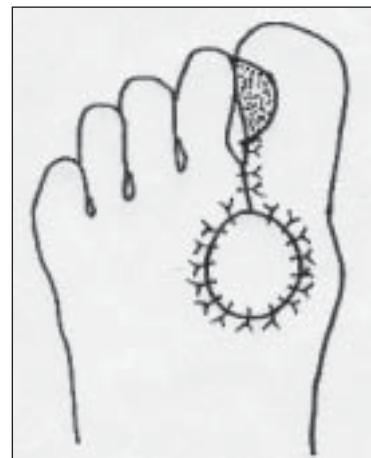


Figure 4: Completed procedure with flap sutured

from 20 to 63. The median age was 38 years. The duration of the ulcer ranged from 5 months to 12 years. The median duration was 12 months. Follow up ranged from 6 months to 36 months (median 13 months).

The donor site for all the flaps, except one, was the lateral aspect of the big toe. The exception was the flap used to cover the 5th metatarsal plantar defect where the flap was taken from the lateral aspect of the 4th toe. The dimensions of the defects after excision ranged between 1 x 1 sq cm to 3.5 x 3 sq cms. The dimensions of the flaps ranged between 1.5 x 1.5 sq cms to 3.5 x 3.5 sq cms.

All the cases did well with no recurrence of ulcers at last follow up.

Complications seen in the immediate post operative period included loss of skin graft over the secondary defect in four cases and wound dehiscence in four cases. In three cases the skin graft was reapplied and in one case the secondary

defect healed by secondary intention. In those cases with wound dehiscence, all the flaps were re-sutured and in one of these cases, extensor tenotomy was also needed to be done to facilitate flap closure as the un-opposed action of the extensor caused the toe to cock-up and prevent plantar wound apposition. In the late post operative period, complications were seen in two cases. One case had developed a callous at one edge of the flap two years after the procedure. This was managed by asking the patient to soak her feet in water every day and scrape the callous. The other was a sinus of the edge of the flap over the 5th metatarsophalangeal joint with dislocation of the joint. This was managed non-operatively by immobilisation.

DISCUSSION

Many flaps have been described in the management of plantar ulcers over the metatarsophalangeal joints. Fritschi¹, and later Pring and Casabianca³ have suggested excision of the metatarsophalangeal joint through a dorsal incision

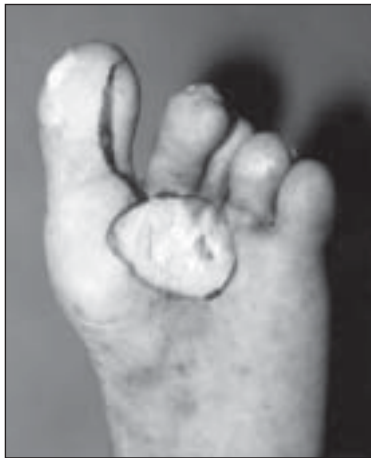


Figure 5: Ulcer beneath 2nd, 3rd and 4th metatarsal heads with planned excision and flap

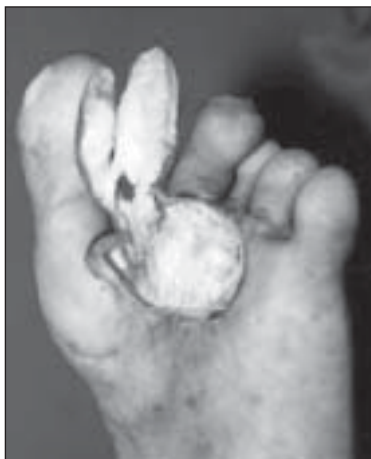

Figure 6: Defect after excision and flap raised

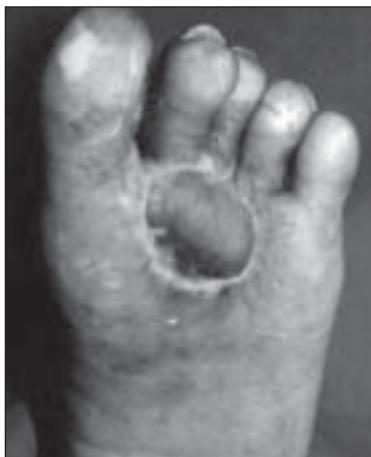

Figure 7: Flap healed and covering defect

in cases where the metatarsophalangeal joint has been involved through the ulcer. They have advocated debriding the plantar wound and closing it by sutures, leaving a dorsal drain. We have extensively used this procedure where there is co-existing septic arthritis and / or disintegration of the joint. If the plantar ulcer or sinus does not involve the joint,

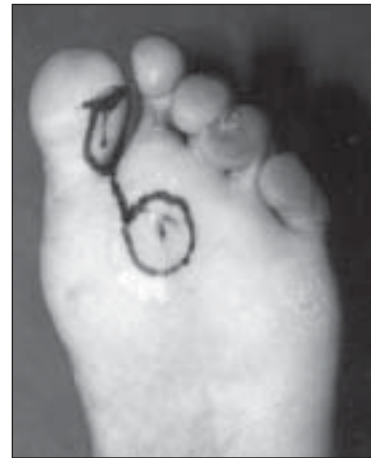


Figure 8: Plantar sinus beneath 2nd metatarsal region with planned incisions for excision and flap

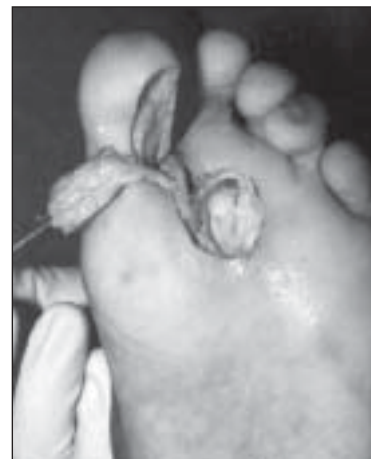

Figure 9: Sinus excised and flap raised

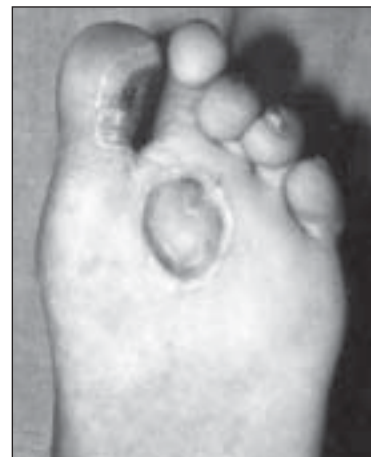


Figure 10: Flap healed covering the defect

we have tried to cover the defect with the toe web flap⁴. Curtin⁵ has described a transposition flap from the plantar midfoot, based laterally. This tended to scar the foot extensively and left an area of the instep with a secondary defect needing a skin graft. Emmett⁶ has described a filleted toe flap for this purpose. An entire toe is sacrificed in this

procedure with the resultant cosmetic defect. Reiffel⁷ has described a versatile plantar artery skin fascia flap, which moves to cover defects of the forefoot and is based on the lateral plantar artery. This involves extensive dissection of the sole, leads to a large area of scarring and may be useful for large defects. Martin et al⁸ described a medial plantar flap with a lateral plantar pedicle to cover large defects of the forefoot. The dissection required is meticulous and extensive leaving an equally extensive scarred area and a skin graft over the instep. But we think that though there is a place for such a flap, small defects as those we have encountered, can be dealt with by smaller flaps.

Dong et al⁴ first described the first toe web flap to cover defects over the 1st and 2nd metatarsophalangeal joints. They used only the big toe as the donor site and covered defects confined to the 1st and 2nd metatarsal region. Gravem⁹ has also described a similar flap from a toe adjacent to the ulcer and has called it the 'toe island flap (Digital Artery Island flap)'

In this series we have used the flaps to cover defects over any of the metatarsophalangeal joints on the plantar aspect, based on the plantar metatarsal artery and the digital artery, not only of the first toe web but also of the 4th toe web. The secondary defects are not over the sole but over the lateral aspect of the donor toe. The extent of scarring of the sole is restricted to the area of the defect and the incision to the toe web space. In those cases where the secondary defect skin graft did not take, healing was by secondary intention with no discernable disadvantage.

CONCLUSION

Forefoot plantar ulceration over the metatarsophalangeal joints is a common problem in leprosy. This is compounded by the scarring over the same bony prominence when the wound heals. Shearing forces and direct pressure tend to

cause recurrence of ulceration at these sites adding to the tissue destruction. Soft tissue coverage of these areas helps to alleviate this problem. The toe web flap based on the plantar metatarsal artery and the digital artery provides just such soft tissue coverage. It also spreads the pressure and reduces shearing stresses. It thus helps in preventing recurrence and further damage to the forefoot. It also produces minimal donor site morbidity. It is also a durable flap. Its main disadvantage is that it cannot be used to cover defects larger than 3.5 cms in diameter.

REFERENCES

1. Fritschi EP. Ulcers of the foot and their sequelae. *In: Surgical Reconstruction and Rehabilitation in Leprosy*; 2nd edn. New Delhi: The Leprosy Mission; 1984;pp 182-226.
2. Cross H. Foot Orthotic Therapy. *In: Schwarz R, Brandsma W, editors. Surgical Reconstruction and Rehabilitation in Leprosy and other Neuropathies.* Kathmandu: Ekta Books Distributors Pvt Ltd; 2004;pp 237-48.
3. Pring DJ, Casabianca N. Dorsal incision the treatment of complicated forefoot plantar ulcers in the anaesthetic foot. *Lepr India* 1983;55:49-59.
4. Dong L, Li.F, Jiang J, Zhang G. Techniques for covering soft tissue defects resulting from plantar ulcers in leprosy: Part II. First toe web and dorsal foot flaps. *Indian J Lepr* 1999;71:297-309.
5. Curtin JW. Transposition and Rotation skin flaps of the sole of the foot. *In: Strauch B, Vasconez LO, Hall-Findlay EJ. Editors. Grabbs encyclopedia of flaps Vol III. 2nd edn.* Philadelphia: Lippincott-Raven; 1998. pp 1815-9.
6. Emmett AJJ. Filleted Toe Flap. *In: Strauch B, Vasconez LO, and Hall-Findlay EJ. Editors. Grabbs encyclopedia of flaps Vol III. 2nd edn.* Philadelphia: Lippincott-Raven; 1998. pp1833-5.
7. Reiffel RS. Plantar Artery-Skin-Fascia Flap. *In: Strauch B, Vasconez LO, Hall-Findlay EJ. Editors. Grabbs encyclopedia of flaps Vol III. 2nd edn.* Philadelphia: Lippincott-Raven; 1998. pp 1843-7.
8. Martin D, Gorowitz B, Peres JM, Baudet J. Medial Plantar Flap. *In: Strauch B, Vasconez LO, Hall-Findlay EJ. Editors. Grabbs encyclopedia of flaps Vol III. 2nd edn.* Philadelphia: Lippincott-Raven; 1998. pp 1848-50.
9. Gravem PE. Role of Flaps and Skin Grafts in the Management of Neuropathic Plantar Ulcers. *In: Schwarz R, Brandsma W, editors. Surgical Reconstruction and Rehabilitation in Leprosy and other Neuropathies.* Kathmandu: Ekta Books Distributors Pvt Ltd. 2004. pp 227-36.