

Short Communication

The Frequency and Characteristics of Mesiodens in a Turkish Patient Population

Fatih Kazanci^a
 Mevlut Celikoglu^b
 Ozkan Miloglu^c
 Hanifi Yildirim^d
 Ismail Ceylan^d

ABSTRACT

Objectives: The aim of this study was to investigate the frequency and characteristics of mesiodens among a group of orthodontic patients in Turkey.

Methods: A retrospective study was performed using panoramic radiographs of 3,351 patients ranging in age from 8 to 16 subjected to dental treatment in the Department of Oral and Maxillofacial Radiology and Department of Orthodontics (Erzurum, Turkey) between 1996 and 2008. All medical and demographic data (age and sex) were obtained from the files. Descriptive characteristics of mesiodentes, including number, shape, position, complication caused by mesiodens and treatment were recorded. The Chi-squared test was used.

Results: Results show that the frequency of mesiodens was 0.3% with the ratio of boys (6 cases) to girls (4 cases) being 1.5:1 and this was not statistically significant ($P > .05$). Of the 10 children, 8 (80.0%) had 1 mesiodens and 2 (20.0%) had 2 mesiodentes bilaterally to midline. Of the 12 mesiodentes, 8 (66.7%) were fully impacted, 7 (58.3%) in a vertical position and 9 (75.0%) conical shape. The most common complication caused by mesiodens was delayed eruption of the permanent incisors in 4 cases (40.0%).

Conclusions: The frequency of mesiodens in Turkish orthodontic patients was found to be 0.3% and more frequently in males with the ratio being approximately 1.5:1. Most of the mesiodentes were in conical shape (75.0%). Sixty-seven percent of the cases were fully impacted. (Eur J Dent 2011;5:361-365)

Key words: Mesiodens; Prevalence; Turkish population.

- ^a Department of Orthodontics, Faculty of Dentistry, Yuzuncuyil University, Van, Turkey.
 - ^b Department of Orthodontics, Faculty of Dentistry, Karadeniz Technical University, Trabzon, Turkey.
 - ^c Department of Oral Diagnosis and Radiology, Faculty of Dentistry, Ataturk University, Erzurum, Turkey.
 - ^d Department of Orthodontics, Faculty of Dentistry, Ataturk University, Erzurum, Turkey.
- Corresponding author: Fatih Kazanci
 Yuzuncuyil Universitesi, Dishekimligi Fakultesi,
 Ortodonti Anabilim Dalı, Van, Turkey.
 E-mail: dtkazanci@yahoo.com

INTRODUCTION

A mesiodens is a supernumerary tooth located in the maxillary central incisor region; the overall frequency of mesiodentes is between 0.15% and 1.9%.¹⁻³ Mesiodentes appear with a higher frequency in man than in women with a 2:1 ratio.⁴ These teeth are frequently impacted with a solitary location between the 2 central incisors or as unilateral teeth. Bilateral mesiodentes occur in 13% of all cases.¹

Mesiodentes are frequently associated with various craniofacial anomalies including cleft lip and palate, Gardner's syndrome, Down syndrome and cleidocranial dysostosis.⁵

Conventional radiological explorations have been used in order to pinpoint its position and plan its treatment and surgical removal (periapical and occlusal radiographs). But in some cases, they do not provide all the information needed in order to situate them three-dimensionally in relation to the adjacent structures. Computed tomography and cone-beam computed tomography can be used to make decisions about therapeutic options.⁶

There are two subclasses in the classification of mesiodens, according to their shape and size. The first group is eumorphic teeth, resembling the central incisors with normal shape and size. The second group includes the dysmorphic teeth with variable size and shape and can be further subdivided into conical, tuberculate, molariform and infundibular teeth.⁷

Mesiodentes can delay or prevent eruption of central incisors and cause ectopic eruption, displacement or rotation of a central incisor and labially displace incisors.^{3,8} Less common complications involving the permanent incisors include dilaceration of the developing roots, root resorption and loss of tooth vitality. Complications involving the mesiodens itself include eruption of the mesiodens in to the nasal cavity; development of a dentigerous cyst has been reported in 4% to 9% of cases.⁹⁻¹³

The aim of this study was to determine the frequency and radiological features of mesiodens among a group of orthodontic patients in Turkey.

MATERIAL AND METHODS

We designed a descriptive study composed of 6,154 panoramic radiographs of patients who presented to our Oral and Maxillofacial Radiology and Orthodontic Services of Dentistry Faculty, Ataturk University, between January 1996 and January 2008. None of these patients had any further symptoms, in particular any symptoms suggestive of a syndromic background e.g. ectodermal dysplasia. The presence of an unerupted supernumerary tooth, or tooth bud between the two central incisors, or of unilateral or bilateral teeth in the midline of the maxilla, was noted as mesiodens on radiographs.^{4,7}

All radiographs were performed using an orthopantomography device (Planmeca Proline CC 2002, 60-80 kVp, 8-10 mA, 12.8 second exposure time, Helsinki, Finland) by an X-ray technician who had a minimum working experience of 5 years as of 1996. Radiographs were taken using 6-inch green-sensitive panoramic film (Medical, Konica Co., Japan) and an appropriate cassette-intensifying screen (15x30 cm, Panoramic X-Ray Film Cassette, Planmeca, Finland-Lanex Screen, Kodak Eastman Co., USA). During filming, exposure adjustments were made in accordance with each individual and the films were developed using an automatic film-processing machine (Velopex, Extra-X, England).

To minimize variability in the present study, examinations were carried out jointly by the first and second authors of the article (2 academic from the Department of Orthodontics) over approximately 2 months. Throughout the study, in case of disagreement between the first 2 authors as to the outcome of an examination, the third author (from the Department of Oral Diagnosis and Radiology) was consulted. Cases of mesiodens were found in patients for who complete documentation, including radiographs and photographs. In addition to gender and age, the following information about the mesiodens was recorded: 1) number; 2) shape; 3) position; 4) complications caused by mesiodens; 5) treatment.

The variables were analyzed using the Statistical Package for Social Sciences (SPSS 11.5; Chicago, IL, USA) Program. The frequencies of anomalies which are detected are calculated with respect to sexes, number, shape, position, complications caused by mesiodens and treatment.

The Pearson chi-squared test was used to determine potential differences in the distribution of dental anomalies when stratified by sex. A P value of <.05 was considered statistically significant.

RESULTS

Frequency, gender and age distribution

Between June 2003 and July 2008, 12 cases of mesiodens were diagnosed in 10 patients ranging in age from 8 to 16 years. The frequency of mesiodens was 0.3% with the ratio of boys (6 cases) to girls (4 cases) being 1.5:1 and mesiodens was observed mostly between 8 and 9 years of age (Table 1).

Number of mesiodens

Among the 10 children examined, 8 (80.0%) had 1 mesiodens and 2 (20.0%) had 2 mesiodens bilateral to the midline.

Shape of mesiodens

Among the 12 mesiodentes, the conical shape was the most common with 9 cases (75.0%), followed by canine-like teeth in 2 cases (16.7%) and incisor-like tooth in 1 case (8.3%) (Table 2).

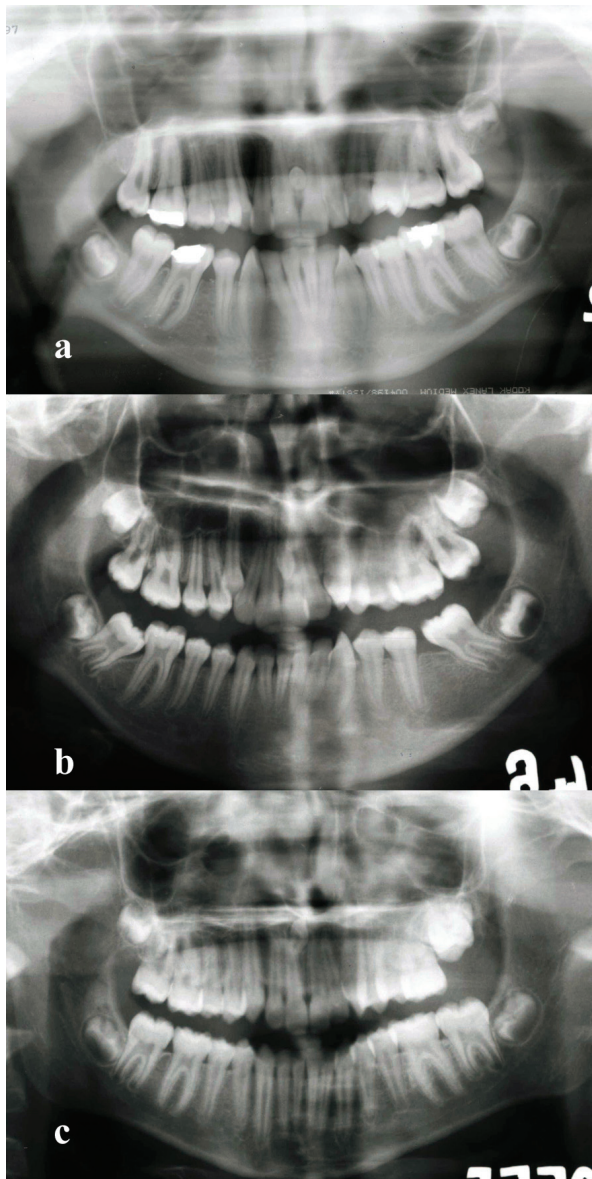


Figure 1. The position of mesiodens. a. Horizontal b. Vertical c. Inverted

Position of mesiodens

Of the 12 mesiodentes, 8 (66.7%) were fully impacted, 1 (8.3%) was partially erupted and 3 (25.0%) were fully erupted. Most of them were found in a vertical position (58.3%), followed by an inverted position (33.3%) and a horizontal position (8.3%) (Table 2 and Figures 1a,1b and 1c).

Complications caused by mesiodens

The main complications were delayed eruption of the permanent incisors (41.7%), maxillary midline diastema (33.3%), inclination or rotation of erupted permanent incisors (8.3%). In 2 cases (16.7%), there were no complications caused by mesiodens (Table 3).

Treatment of mesiodens

Of the 12 mesiodentes, 10 (83.3%) were surgically removed instantaneously and 2 (16.7%) were followed up with radiographs until their orthodontic treatment completed (Table 3).

DISCUSSION

Many studies of frequency of mesiodens have been published up to now.¹⁴⁻¹⁷ The frequency of mesiodens has been estimated to be 0.45% in Caucasians, 0.4% in Finnish, 1.43% in Norwegians and 2.2% in Hispanic populations.¹⁴⁻¹⁶ Additionally, Gündüz et al¹⁷ have reported that the frequency of mesiodens in a group of Turkish children was 0.3%. In this study we found the frequency of mesiodens to be 0.3%.

Mesiodens occurs more frequently in boys than in girls, with the ratio being approximately 2:1.¹⁸⁻²¹ In this study, a male: female ratio of 1.5:1 for the frequency of mesiodens was found, in agreement with previous studies.^{17-19,21}

In this study, we investigated the presence of mesiodens in children aged between 8 and 16 years. This means that our study involved only mixed or permanent dentition, in contrast to other studies, where the subjects also included much younger individuals.^{17,22,23} Of our 12 mesiodentes, 6 (50.0%) were found at age 8-9 years. This is in

Table 1. The frequency of mesiodens according to gender.

Gender	n	Mesiodens	Prevalence	χ^2	P Value
Female	2043	4	0.20	1.85	0.15*
Male	1308	6	0.46		

* Fisher's exact test.

line with Gündüz et al¹⁷ who reported that 47.0% of cases were found at age 6-9 years.

In our study, the number of mesiodens was one in 8 cases (80.0%) and two in 2 cases (20.0%). This is similar with many studies^{17,18,22,24} which reported one mesiodens in 76.8%, 75.0%, 72.0% and 73.0% of their cases, respectively.

The shape of mesiodens can vary from a simple conical form to a larger, more complicated crown shape with a number of tubercles.^{18-22,24} Many studies^{17-21,25} show that the most common shape of mesiodens is conical. In our study we found 8 (66.7%) conical mesiodentes and this is corresponding well with earlier reports.^{18-21,26}

Most of the mesiodentes are impacted.^{17,27} In this study, we found that impacted mesiodens comprised 66.7% which is lower to that reported in other studies.^{17,25,27} The most common position of mesiodens found is vertical position and this is in agreement with previous studies.^{21,26}

The clinical complications of mesiodens include delayed eruption of permanent incisors, midline diastema, axial rotation or inclination of erupted permanent incisors, resorption of adjacent teeth or mesiodens, root anomaly, cyst formation, intraoral infection, and mesiodens pulpitis.^{18,21,25} In this study the complications we found were delayed eruption of the permanent incisors, maxillary midline diastema and inclination or rotation of erupted permanent incisors. The most common complication was delayed eruption of the permanent teeth (41.7%) and this percentage was

higher than in previous studies.^{14,25} There were no root anomaly, cyst formation and intraoral infection in any cases in contrast to other studies where cyst formation was found 37% and 30% of their cases, respectively.^{3,24}

There can be confusion about whether and when mesiodentes should be surgically removed, or whether they should be retained and followed up radiologically.¹⁷ When mesiodentes have been impacted for a long period, they have a high risk of forming dentigerous cysts.²⁴ Therefore, immediate surgical removal was indicated in 10 (83.3%) of the cases that had associated complications. The other 2 (16.7%) mesiodentes were followed up radiologically until the treatment completed and then they were removed.

Approximately 6 months after extraction of a mesiodens, clinical and radiographic reassessment recommended to determine if the permanent tooth has erupted.¹⁹ If a tooth does not erupt within 6 to 12 months after extraction of the mesiodens, surgical exposure and orthodontic eruption of the permanent incisors are recommended.¹⁹ In this study, there were 4 cases with delayed eruption of the permanent incisors. Of the impacted teeth, 3 permanent incisors (75.0%) started to erupt spontaneously within 6 months. The other 1 impacted permanent incisor (25.0%) did not erupt and orthodontic treatment was required. The frequency of spontan eruption of permanent incisor after the extraction of mesiodens coincide with the earlier studies.^{11,28}

Table 2. The shape and position of mesiodens.

		n	%
Shape	Conical	9	75.0
	Canine-like	2	16.7
	Incisor-like	1	8.3
Position	Vertical	7	58.3
	Inverted	4	33.3
	Horizontal	1	8.4

Table 3. Complication and treatment of mesiodens.

		n	%
Complications	Delayed eruption of the permanent incisors	5	41.7
	Midline diastema	4	33.3
	Axial rotation or inclination of permanent incisors	1	8.3
	None (Asymptomatic)	2	16.7
Treatment	Surgically removed instantaneously	10	83.3
	Followed up with radiographs until their orthodontic treatment completed.	2	16.7

CONCLUSIONS

The frequency of mesiodens in Turkish orthodontic patients was found to be 0.3% and more frequently in males with the ratio being approximately 1.5:1. Most of the mesiodentes were in conical shape (75.0%). Sixty-seven percent of the cases were fully impacted.

REFERENCES

1. Sedano HO, Gorlin RJ. Familial occurrence of mesiodens. *Oral Surg Oral Med Oral Pathol* 1969;27:360-361.
2. Sykaras SN. Mesiodens in primary and permanent dentitions. Report of a case. *Oral Surg Oral Med Oral Pathol* 1975;39:870-874.
3. Primosch RE. Anterior supernumerary teeth-assessment and surgical intervention in children. *Pediatr Dent* 1981;3:204-215.
4. Stellzig A, Basdra EK, Komposch G. Mesiodentes: incidence, morphology, etiology. *Fortschr Kieferorthop J Orofac Orthop* 1997;58:144-153.
5. Gorlin RJ, CM, Hennekam RC. Syndromes of the head and neck. 4th ed. Oxford University Press; 2001.
6. Mason C, Azam N, Holt RD, Rule DC. A retrospective study of unerupted maxillary incisors associated with supernumerary teeth. *Br J Oral Maxillofac Surg* 2000;38:62-65.
7. van Buggenhout G, Bailleul-Forestier I. Mesiodens. *Eur J Med Genet* 2008;51:178-181.
8. Gardiner J. Supernumerary teeth. *Dent Pract Dent Rec* 1961;12:63-73.
9. Brook AH. A unifying aetiological explanation for anomalies of human tooth number and size. *Arch Oral Biol* 1984;29:373-378.
10. Thawley KL, LaFerriere KA. Supernumerary nasal tooth. *Laryngoscope* 1977;87:1770-1773.
11. Di Biase DD. The effects of variations in tooth morphology and position on eruption. *Dent Pract Dent Rec* 1971;22:95-108.
12. Atasu M, Orguneser A. Inverted impaction of a mesiodens: a case report. *J Clin Pediatr Dent* 1999;23:143-145.
13. Lustmann J, Bodner L. Dentigerous cysts associated with supernumerary teeth. *Int J Oral Maxillofac Surg* 1988;17:100-102.
14. Hurlen B, Humerfelt D. Characteristics of premaxillary hyperdontia. A radiographic study. *Acta Odontol Scand* 1985;43:75-81.
15. Buenviaje TM, Rapp R. Dental anomalies in children: a clinical and radiographic survey. *ASDC J Dent Child* 1984;51:42-46.
16. Järvinen S, Lehtinen L. Supernumerary and congenitally missing primary teeth in Finnish children. An epidemiologic study. *Acta Odontol Scand* 1981;39:83-86.
17. Gündüz K, Celenk P, Zengin Z, Sümer P. Mesiodens: A radiographic study in children. *J Oral Sci* 2008;50:287-291.
18. Kim SG, Lee SH. Mesiodens: a clinical and radiographic study. *J Dent Child* 2003;70:58-60.
19. Russell KA, Folwarczna MA. Mesiodens – diagnosis and management of a common supernumerary tooth. *J Can Dent Assoc* 2003;69:362-366.
20. Zhu JF, Marcushamer M, King DL, Henry RJ. Supernumerary and congenitally absent teeth: a literature review. *J Clin Pediatr Dent* 1996;20:87-95.
21. Tyrologou S, Koch G, Kurok J. Location, complications and treatment of mesiodentes – a retrospective study in children. *Swed Dent J* 2005;29:1-9.
22. Huang WH, Tsai TP, Su HL. Mesiodens in the primary dentition stage: a radiographic study. *ASDC J Dent Child* 1992;59:186-189.
23. Ersin NK, Candan U, Alpoz AR, Akay C. Mesiodens in primary, mixed and permanent dentitions: a clinical and radiographic study. *J Clin Pediatr Dent* 2004;28:295-298.
24. Asaumi JI, Shibata Y, Yanagi Y, Hisatomi M, Matsuzaki H, Konouchi H, Kishi K. Radiographic examination of mesiodens and their associated complications. *Dentomaxillofac Radiol* 2004;33:125-127.
25. von Arx T. Anterior maxillary supernumerary teeth: A clinical and radiographic study. *Aust Dent J* 1992;37:189-195.
26. Roychoudhury A, Gupta Y, Parkash H. Mesiodens: A retrospective study of fifth teeth. *J Indian Soc Pedod Prev Dent* 2000;18:144-146.
27. Seddon RP, Johnstone SC, Smith PB. Mesiodentes in twins: a case report and a review of the literature. *Int J Paediatr Dent* 1997;7:177-184.
28. Howard RD. The unerupted incisor. A study of the postoperative eruptive history of incisors delayed in their eruption by supernumerary teeth. *Dent Pract Dent Rec* 1967;17:332-341.