

Gingival Changes in Wistar Rats after Oral Treatment with 4-Nitroquinoline 1-Oxide

Daniel Araki Ribeiro^a,
Daisy Maria Fávero Salvadori^b

ABSTRACT

Objectives: 4-nitroquinoline 1-oxide (4NQO)-induced rat tongue carcinogenesis is a useful model for studying oral squamous cell carcinoma. However, gingival changes following 4NQO administration via drinking water are absent in the literature. The aim of this study was to investigate gingival changes concomitant to tongue carcinogenesis induced by 4NQO by means of morphological analysis.

Methods: Male Wistar rats were distributed into 3 groups of 10 animals each and treated with 50 ppm 4NQO solution by drinking water for 4, 12 or 20 weeks. Thirty animals were used as negative control.

Results: Regarding tongue mucosa, the primary histopathological change i.e., hyperplasia and dysplasia was evidenced after 12 weeks treatment with 4NQO. At 20 weeks, squamous cell carcinoma was found in the majority of animals. Gingival squamous hyperplasia was induced by 4NQO after 20-weeks of treatment. Dysplastic changes appeared in some animals (two cases) as well.

Conclusions: Taken together, our results support the notion that 4NQO is more effective in rat tongue mucosa than gingival tissue. Probably, this discrepancy depends strongly on route of administration and the susceptibility with respect to animals species. Certainly, such data will contribute when using this experimental test-system for understanding oral cancer pathogenesis. (Eur J Dent 2007;1:152-157)

Keywords: Oral cancer; 4-nitroquinoline 1-oxide; Rat; Gingiva.

INTRODUCTION

Oral cancer is a common neoplasm worldwide, particularly in developing countries such as India, Vietnam and Brazil, where it constitutes up to 25% of all types of cancer.¹ Despite of the sophisticated surgical and radiotherapeutic modalities, the patient survival has not improved significantly during the last decades.² Tobacco and alcohol consump-

tion are the most significant exogenous factors involved in tumorigenesis.³

The most used animal models in oral cancer research are the hamster buccal pouch by fat-soluble 7,12 dimethylbenzanthracene (DMBA), and the rat tongue by water-soluble 4-nitroquinoline 1-oxide (4NQO).⁴ Considering that one of the most important routes of oral carcinogens is through liquid containing water-soluble carcinogens, 4NQO is well suited in examining the role of xenobiotics in experimental oral carcinogenesis.⁵ Based on the multi-step process of carcinogenesis characterized by initiation, promotion and tumor progression, chronic administration of 4NQO in drinking water simulates rat tongue carcinogenesis like human counterpart.⁶⁻¹⁰

- ^a Department of Health Sciences, Federal University of Sao Paulo, UNIFESP, SP, Brazil;
- ^b Department of Pathology, Botucatu Medical School, Sao Paulo State University, UNESP, SP, Brazil
- Corresponding Author: Daniel Araki Ribeiro, DDS, PhD Departamento de Ciências da Saúde Av. Ana Costa, 95 Vila Mathias Santos – SP, 11060-001, Brazil
Phone : 55 13 32222048
Fax : 55 13 32222048 e-mail: daribeiro@unifesp.br

Moreover, oral administration of 4NQO produces tumor in other tissues of oral cavity as well as aerodigestive tract.¹¹ For example, some researchers have described changes induced by 4NQO intake in minor salivary glands¹⁰ and esophageal mucosa.¹¹ However, to our knowledge, there are no studies reporting gingival changes during tongue carcinogenesis induced by 4NQO incorporated into drinking water so far. As a result of limited evidence, this study was aimed to look at putative changes on gingival tissue concomitant to tongue carcinogenesis following systemic exposure to 4NQO. Certainly, such data will contribute to a better understanding of this medium-term oral carcinogenesis assay currently used for studying oral cancer pathogenesis.

MATERIAL AND METHODS

Animals and experimental design

A total of 60 male Wistar rats (8 weeks old) weighting approximately 250 g, were obtained from Centro de Bioterismo (CEMIB), Universidade Estadual de Campinas, SP, Brazil. They were maintained under controlled conditions of temperature ($24 \pm 2^\circ\text{C}$), light-dark periods of 12 hours, and with free access to water and commercial diet (Nuvital PR, Brazil). They were treated with 50 ppm 4NQO (Sigma, St. Louis, MO, USA) solution by drinking water for 4, 12 and 20 weeks. Thirty animals were used as negative control. At the end of the experimental period, the rats were sacrificed by 0.4% sodium pentobarbital (1mL/kg body wt, i.p.). The final body weight and weight gain were recorded. The tongues and mandibles were longitudinally cut into halves for histopathological examinations. For this, the mandibles were decalcified in a 5% of nitric acid solution (Merck, Darmstadt, Germany) for 5 days. After fixation and/or decalcification, all of the tissues were trimmed, dehydrated, cleared,

embedded in paraffin, sectioned into 5 μm thick section, stained with hematoxylin and eosin (H.E.) All experimental protocols were approved by the Animal Committee the Botucatu Medical School, UNESP, Brazil.

Histopathological analysis

Histopathological evaluation was performed under light microscope. Analyzes of the tongue and mandible sections in the molar tooth areas were graded as normal, hyperplasia, dysplasia and carcinoma by Kramer et al.¹²

Statistical analysis

Results from the final body weight and weight gain were analyzed by one way ANOVA, followed by Tukey's test. The level of significance was set at 5%.

RESULTS

Quantitative results

Final body weight and weight gain during the experimental period are presented in Table 1. Excluding 12 weeks treated group for final body weight, all groups showed statistically decreases ($P < .05$) either to final body weight or to weight gain when compared to control group.

Morphological results

The dorsal surface of the rats' tongue treated with 4NQO became white with a rough appearance after 12 weeks-treatment only. As time progressed, ulcers were found in the same region in the majority of animals. No apparent abnormal clinical signs were noticed to gingival tissue in all periods evaluated.

Regarding subjective microscopic analysis, no histopathological changes in tongue epithelia were observed in the control group (Figure 1a) nor

Table 1. Mean \pm Standard deviation of final body weight and weight gain of rats in the 4-nitroquinoline 1-oxide (4NQO)^a model for oral carcinogenesis.

Dose (ppm)	4 weeks		12 weeks		20 weeks	
	Final body weight	Weight gain	Final body weight	Weight gain	Final body weight	Weight gain
0	341.56 \pm 27.4	45.16 \pm 3.12	396.31 \pm 54.59	99.91 \pm 10.57	462.3 \pm 23.46	165.9 \pm 18.57
50	273.52 \pm 26.5*	6.66 \pm 1.04*	314.78 \pm 34.34	34.6 \pm 5.87*	377.2 \pm 60.13*	97.2 \pm 20.48*

*: $P < .05$ when compared to control group (zero).

^a4NQO – 50 ppm by drinking water

after 4th week treatment with 4NQO. The primary histopathological change, i.e., hyperplasia and hyperkeratosis with the spinous cell layer gradually thickened was evidenced after 12-weeks-treatment (Figure 1b). In this period, epithelial dysplasia was also found in mild and moderate forms (Figure 1c). At 20 weeks, moderate and/or severe oral dysplasia (Figure 1c) and squamous cell carcinoma in the tongue (Figure 1d) were found; being that in the majority of animals consisted of squamous cell carcinoma. The histopathological grade of the carcinomas was usually squamous cell carcinoma of a well-differentiated type. The tumors spread into the submucosa and underlying muscle layer, forming small nests with typical keratin pearl formation. In advanced cases, severe atypia was frequently found. The histopathological findings are summarized in the Table 2.

Finally, no significant changes were observed until 12-weeks of treatment with 4NQO in the gingival mucosa (Figure 2a). However, cases showing the presence of coarse food particles upon gingival mucosa producing inflammation in the periodontal tissue adjacent the molar tooth were noted sporadically in control and experimental animals (Figure 2b). No significant differences in the incidences of gingivitis occurred between control and experimental groups (data not shown). Gingival squamous hyperplasia induced by 4NQO

after 20-weeks of treatment constituted a focal lesion that manifested itself in the stratified squamous epithelium of oral mucosa adjacent to molar tooth. It consisted of varying degrees of thickening of the epithelium showing hyperkeratosis, often with the formation of epithelial rete pegs that extended into the underlying connective tissue (Figure 2c). Endophytic proliferation of tissue gingival squamous hyperplasia occurred most commonly rather than exophytic projections in the stratified squamous epithelium. The proliferative cells producing keratin displayed prominent intercellular bridges and resembled normal stratified squamous epithelium. In this group, dysplastic changes appeared in some animals (two cases) as well. The dysplastic cells contained large nuclei with clear nucleoli, eosinophilic cytoplasm, mitotic figures, and coexistent dyskeratotic, suggesting cellular atypia (Figure 2d). All findings are summarized in Table 3.

DISCUSSION

The aim of chemical carcinogenesis models is to provide further understanding concerning to the multi-step process of carcinogenesis in order to investigate hazard risk caused by environmental agents as well as to develop strategies to earlier diagnostic and/or cancer prevention. Several medium-term duration assay systems for oral carci-

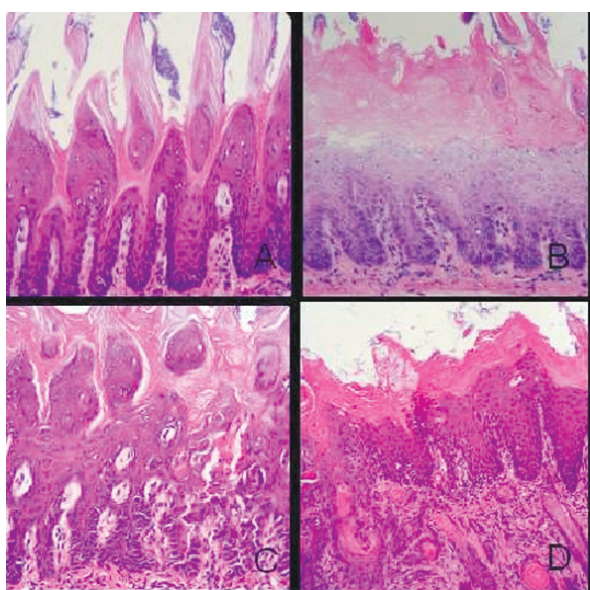


Figure 1. Photomicrographies showing the multi-step process of rat tongue carcinogenesis. (A) no histopathological change (control); (B) hyperplasia and hyperkeratosis; (C) epithelial dysplasia; (D) squamous cell carcinoma of well-differentiated type. (Hematoxylin and Eosin stain; X 100 magnification).

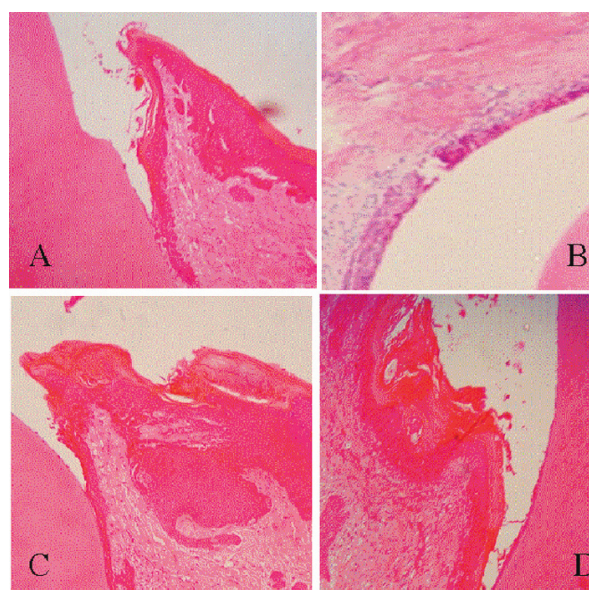


Figure 2. Photomicrographies of gingival tissue from control group and that treated with 4NQO. (A) control group, (B) control group presenting inflammation (C) hyperplasia and (C) dysplasia. (Hematoxylin and Eosin stain; X 100 magnification).

nogenesis offer particular promise. One of these models is DMBA-induced carcinoma produced in the hamster cheek pouch. Because of its peculiar anatomic site and histology, some authors have questioned the suitability of the hamster cheek pouch for studies related to oral tumors.¹³ In this regard, the Wistar rat is a good alternative because it is ease of handling and availability. Furthermore, 4NQO-induced rat tongue tumors are more realistic since reveal histological and biochemical characteristics similar to the human tumors.⁶⁻¹⁰ Such results obtained from this present investigation, using 4NQO as carcinogen inducers, demonstrated histopathological changes in tongue mucosa along a time-course experiment from normal epithelium, hyperplasia and hyperkeratosis, pre-malignant dysplasia, and carcinoma in situ to invasive squamous cell carcinoma.^{14,15}

Accumulating evidence suggests that diagnosis of human gingival squamous cell carcinoma is prone to delay because it is rare, and thus unexpected, and because it may be mistaken clinically for gingival or periodontal infection.¹⁶ Gingival carcinoma usually occurs in the lower jaw in posterior sites with pain, swelling and loosening of adjacent teeth being common clinical signs.¹⁶ For this reason, gingival lesions were investigated herein within the areas of the lower molar-tooth ligament (gingival sulcus). In the rat, the gingiva

consists of a keratinized stratified squamous epithelium, connective tissue with fibroblasts, and the extracellular matrix, composed chiefly of collagen fibers and ground substance containing sulfated glycosaminoglycans.¹⁷⁻¹⁹ The gingival epithelium in the molar-tooth area is classified as gingival oral epithelium, sulcular epithelium and junctional epithelium, which appears non-keratinized and forms the floor of the gingival sulcus. Gingival epithelium manifests a higher proliferative capacity and higher rate of absorption of drugs and chemicals than the skin.^{18,20} Mitotic activity appears greatest at the dento-gingival junction of incisors, especially within the junctional epithelium.^{21,22} It is important to stress that configuration of gingival crevice of molar in rat is different from it of human. Therefore, any extrapolation with respect to gingival carcinogenesis in rodents should be interpreted cautiously.

Taking into consideration that 4NQO requires metabolic activation to be converted to the ultimate carcinogen, 4-acetoxyaminoquinoline 1-oxide, which reacts with DNA and causes genetic damage through formation of alkali labile sites and single strand breaks, absorption of this compound and subsequent conversion by cytochrome P450 proteins to xenobiotics metabolites can occur in gingival epithelia.²³ To the best of our knowledge, there are no studies that investigated

Table 2. Incidence of histopathological lesions in tongue of rats in the 4-nitroquinoline 1-oxide (4NQO)^a model for oral carcinogenesis.

Groups (week)	No. of animals	Lesions			
		Normal	Hyperplasia	Dysplasia	Carcinoma
0 (Control)	10	10	0	0	0
4	10	10	0	0	0
12	10	0	7	3	0
20	10	0	0	3	7

^a4NQO – 50 ppm by drinking water

Table 3. Histopathological pattern of gingiva following 4-nitroquinoline 1-oxide^a administration.

Groups (week)	No. of animals	Lesions			
		Normal	Hyperplasia	Dysplasia	Carcinoma
0 (Control)	10	10	0	0	0
4	10	10	0	0	0
12	10	10	0	0	0
20	10	3	5	2	0

^a4NQO – 50 ppm by drinking water

metabolization of 4NQO on gingival tissue. This requires further study. Thus far, the junctional epithelium of molar-tooth, with high proliferative and metabolic activity, may change pathologically and constitute the earliest gingival change induced by 4NQO. Our results demonstrated that 4NQO was able to induce gingival changes as depicted by squamous gingival hyperplasia after 20 weeks following chronicle administration. Additionally, some animals pointed out squamous epithelium displaying cellular atypia characterized by abnormally differentiated squamous layers usually accompanied by thickening of the epithelium. This lesion was categorized as epithelial dysplasia having the potential to progress to squamous cell tumours in oral cavity.⁹ Taken as a whole, we assumed, therefore, that 4NQO was able to induce rat gingival changes following tongue carcinogenesis. Nevertheless, gingival carcinomas were not found in this setting. It is important to stress that the development of tongue carcinoma following 4NQO intake was localized mainly to the dorsum of the tongue. When animals were consuming the carcinogen in drinking water, the 4NQO solution might have had intimate contact with the mucosa of the dorsum of the tongue, where it could have had a direct carcinogenic effect. This may explain the effectiveness in the tongue mucosa in this tumor producing test system. Conversely, it is conceivable that exposure to 4NQO for a longer period of time may have eventually induced squamous cell carcinomas. Considering the end-point adopted of this study (20 weeks), a strong decrease in weight gain was noticed in the experimental group being animals deteriorated with subsequent cachexia. In this sense, we postulated that longer experimental design is not feasible for studying rat gingival carcinomas.

CONCLUSIONS

Taken together, our results support the notion that 4NQO is more effective in rat tongue mucosa than gingival tissue. Probably, this discrepancy depends strongly on route of administration and the susceptibility with respect to animals species. Certainly, such data will contribute when using this experimental test-system for understanding oral cancer pathogenesis. Applicability to clinical practice for persons at high risk of oral cancer, such as in smokers or in alcoholism, as well as

patients diagnosed with oral dysplasia or carcinoma, however, remains to be developed.

ACKNOWLEDGMENTS

The authors are grateful to Paulo Cesar Cardoso and Maria Luiza Falaguera Ardanaz for their technical assistance. This work was supported by FAPESP (Fundação de Amparo à Pesquisa do Estado de São Paulo).

REFERENCES

1. Magrath I, Litvak J. Cancer in developing countries: opportunity and challenge. *J Natl Cancer Inst* 1993;85:862-874.
2. Xi S, Grandis JR. Gene therapy for the treatment of oral squamous cell carcinoma. *J Dent Res* 2003;82:11-16.
3. Hahn M, Hagedorn G, Kuhlisch E, Schackert HK, Edkelt U. Genetic polymorphisms of drug-metabolizing enzymes and susceptibility to oral cavity cancer. *Oral Oncol* 2002;38:486-490.
4. Kitakawa D, Cabral LAG, Marques ME, Salvadori DM, Ribeiro DA. Medium-term tongue carcinogenesis assays: a comparative study between 4-nitroquinoline 1-oxide [4NQO] induced rat and dimethylbenzanthracene [DMBA] induced hamster carcinogenesis. *J Exp Animal Sci* 2006;43:219-227.
5. Tanaka T, Kohno H, Sakata K, Yamada Y, Hirose Y, Sugie S, Mori H. Modifying effects of dietary capsaicin and rotenone on 4-nitroquinoline 1-oxide-induced rat tongue carcinogenesis. *Carcinogenesis* 2002;23:1361-1367.
6. Ohne M, Satoh T, Yamada S, Takai H. Experimental tongue carcinoma of rats induced by oral administration of 4-nitroquinoline 1-oxide [4NQO] in drinking water. *Oral Surg Oral Med Oral Pathol* 1985;59:600-607.
7. Nishimura A. Changes in Bcl-2 and Bax expression in rat tongue during 4-nitroquinoline 1-oxide-induced carcinogenesis. *J Dent Res* 1999;78:1264-1269.
8. Niwa S, Ueno S, Shirasu R. Alteration of pRB expression in the development of rat tongue carcinoma induced by 4-nitroquinoline 1-oxide. *Oral Oncol* 2001;37:579-585.
9. Okazaki Y, Tanaka Y, Tonogi M, Yamane G. Investigation of environmental factors for diagnosing malignant potential in oral epithelial dysplasia. *Oral Oncol* 2002;38:562-573.
10. Vered M, Daniel N, Hirshberg A, Dayan D. Histomorphologic and morphometric changes in minor salivary glands of the rat tongue during 4-nitroquinoline 1-oxide-induced carcinogenesis. *Oral Oncol* 2003;39:491-496.
11. Tang XH, Knudsen B, Benis D, Tickoo S, Gudas LJ. Oral cavity and esophageal carcinogenesis modeled in carcinogen-treated mice. *Clin Cancer Res* 2004;10:301-303.

12. Kramer IR, Lucas RB, Pindborg JJ. Definition of leukoplakia and related lesions: an aid to studies on oral precancer. *Oral Surg Oral Med Oral Pathol* 1978;46:518-539.
13. Nauta JM, Roodenberg JLN, Nikkels PGJ, Witjes MJH, Vermey A. Comparison of epithelial dysplasia – the 4NQO rat palate model and human oral mucosa. *Int J Oral Maxillofac Surg* 1995;24:53-58.
14. Ribeiro DA, Silva RN, Darros BR, Salvadori DM, Marques ME. Genomic instability in non-neoplastic oral mucosa cells can predict risk during 4-nitroquinoline 1-oxide induced rat tongue carcinogenesis. *Oral Oncol* 2004;40:910-915.
15. Ribeiro DA, Salvadori DM, Marques ME. Abnormal expression of bcl-2 and bax during the development of squamous cell carcinoma induced by 4-nitroquinoline 1-oxide. *Int J Exp Pathol* 2005;86:375-381.
16. Neville, Brad W.; Damm, Douglas D. *Patologia Oral & Maxilofacial*, Rio de Janeiro: Guanabara Koogan 2 Ed. 2004 [in Portuguese].
17. Brunet L, Miranda J, Farre M, Berini L, Mendieta C. Gingival enlargement induced by drugs. *Drug Saf* 1996;15:219-231.
18. Haschek WM, Rousseaux CG. Oral mucosa. In: *Fundamentals of Toxicology Pathology*. Academic Press, San Diego, 1998.
19. Ten Cate AR. *Oral Histology: development, structure and function*, 5th ed. Mosby-Year book Inc, St Louis, USA, 1998.
20. Shojaei AH. Buccal mucosa as a route for systemic drug delivery: a review. *J Pharm Pharmaceut Sci* 1998;1:15-30.
21. Shimono M, Ishikawa T, Enokiya YM, Muramatsu T, Matsuzaka K, Inoue T, Abiko Y, Yamaza T, Kido MA, Tanaka T, Hashimoto S. Biological characteristics of the junction epithelium. *J Electron Microsc* 2003;52:627-639.
22. Watanabe K, Petro BJ, Sevandal M, Anshuman S, Jovanovic A, Tyner AL. Histochemical examination of periodontal junctional epithelium in p21/p27 double knockout mice. *Eur J Oral Sci* 2004;112:253-258.
23. Vondracek M, Xi Z, Larsson P, Baker V, Mace K, Pfeifer A, Tjalve H, Donato MJ, Gomez-Lechon MJ, Grafstrom RC. Cytochrome P450 expression and related metabolism in human buccal mucosa. *Carcinogenesis* 2001;22:481-488.