Endoscopic Third Ventriculostomy in Cases of Hydrocephalus: An Institutional Experience

Prarthana Saxena[1] Sharad Pandey[1,2] Pankaj Kumar[1] Kaviraj Kausik[1] Shiv Lal Soni[3]

[1]Department of Neurosurgery, Post Graduate Institute of Medical Education and Research, Dr. Ram Manohar Lohia Hospital, New Delhi, India
[2]Department of Neurosurgery, Sir Sunder Lal Hospital, Institute of Medical Sciences, Banaras Hindu University, Varanasi, Uttar Pradesh, India
[3]Department of Anaesthesia and Intensive Care, Post Graduate Institute of Medical Education and Research, Chandigarh, Punjab, India

Address for correspondence Sharad Pandey, MS, MCh, Department of Neurosurgery, Post Graduate Institute of Medical Education and Research, Dr. Ram Manohar Lohia Hospital, New Delhi 110001, India (e-mail: drsharad23@yahoo.com).

Indian J Neurosurg 2019;8:151–154

Abstract

Background With the recent advances in optical and mechanical instrumentation, endoscopic third ventriculostomy (ETV) has emerged as the procedure of choice for the treatment of hydrocephalus in selected patients.

Objective: To study the role of ETV in therapeutic management of hydrocephalus in a tertiary care center.

Materials and Methods The present study was conducted in the Department of Neurosurgery at Dr. Ram Manohar Lohia Hospital. Endoscopic third ventriculostomy was performed as a therapeutic procedure in patients diagnosed with hydrocephalus requiring surgical intervention and admitted from June 2017 to July 2018. ETV success was defined by resolution or improvement in clinical symptoms and ETV failure was considered in patients whose symptoms either deteriorated or did not improve from the baseline and required ventriculoperitoneal shunt.

Results A total of 85 patients were included in this study who underwent the therapeutic ETV. In the present study, the overall ETV success rate was 75.2% (64/85). 86.7% cases of aqueductal stenosis, 74.4% cases of post meningitis (including tubercular meningitis) hydrocephalus, and 71% of posterior fossa tumors showed resolution or improvement in clinical symptoms.

Conclusion ETV is an effective treatment modality for obstructive hydrocephalus and with better results in post meningitis hydrocephalus and post tubercular meningitis hydrocephalus. However, more extensive studies dedicated to ETV with a larger sample size are required to further study its efficacy in various etiologies.

Keywords
- endoscopic third ventriculostomy
- hydrocephalus
- ETV success

Introduction

Hydrocephalus is accumulation of cerebrospinal fluid (CSF), which leads to increase in intracranial pressure. It can be either the noncommunicating type or the communicating type. Resistance to CSF flow proximal to the arachnoid granulations is seen in the noncommunicating type of hydrocephalus, which may be further classified as intraventricular or extraventricular. Communicating type of hydrocephalus occurs due to reduced CSF absorption at the arachnoid granulations. Based on the etiology, it may be further described as posthemorrhagic, postinfectious, posttraumatic, ex vacuo, tumor-related mass effect, and normal pressure hydrocephalus.

In early 1900s, the first neuroendoscopic technique used by Walter E. Dandy employed cystoscope to see the lateral ventricles.[1] In 1923, first successful endoscopic third ventriculostomy was conducted by Mixter.[2] Shunts were first

received
February 9, 2019
accepted after revision
July 8, 2019
published online
October 21, 2019

DOI https://doi.org/10.1055/s-0039-1697898
ISSN 2277-954X.

©2019 Neurological Surgeons' Society of India

License terms

developed by Nulsen and Spitz in 1951 and were the procedure of choice at that time.[3] Interestingly, endoscopic techniques were introduced prior to shunt surgeries but had a higher complication rate. There is no ideal shunt available till date which is free from any complications.[4]

With the recent advances in the optical and mechanical instrumentation, and availability of better neuroendoscopes made this diagnostic procedure (endoscopic third ventriculostomy [ETV]) more safe and procedure of choice.[2-4] However, most of the published studies on the application of ETV are from the developed countries with different spectrum of patients and prompt accessibility of health care as compared with developing countries such as India. Therefore, in this study we report experiences, patient selection, success rates, and complications of ETV in patients treated in a developing country such as India.

Materials and Methods

The present study was conducted in the Department of Neurosurgery at Dr. Ram Manohar Lohia Hospital, New Delhi. ETV was performed as a therapeutic procedure in patients admitted from June 2017 to July 2018 who were diagnosed with hydrocephalus and required surgical intervention. All patients admitted to our institution with diagnosis of hydrocephalus and indication of ETV were included in the study. Cases of posterior fossa bleed and intraventricular hemorrhage (IVH) were excluded from this study. Informed consent was taken from each patient to participate in this study and ethical approval was taken from hospital ethical committee.

Detailed history, physical examination, baseline investigations, CSF analysis (for postmeningitis hydrocephalus), and computed tomography (CT) scan of all patients were performed. The study excluded patients with Glasgow Coma Scale (GCS) less than 15, normal pressure hydrocephalus, recurrent hydrocephalus in whom a ventriculoperitoneal (VP) shunt had been placed previously, hydrocephalus due to subarachnoid hemorrhage, cisternal exudates, thick and opaque third ventricle floor, and acute meningitic phase on CSF analysis.

ETV success was defined by resolution or improvement in clinical symptoms and ETV failure was considered in patients whose symptoms either deteriorated or did not improve from the baseline and required subsequent VP shunt.

ETV was done in all cases included in the study. Operative procedure undertaken included proper positioning, which was supine with the head flexed. Burr hole was made on right Kocher's point. A 0- degree endoscope (diameter 4 mm) was then passed through the Foramen of Monro (i.e., at the site of confluence of thalamostriate vein, septal vein, and choroid plexus). Fogarty catheter was used to bluntly fenestrate the floor of the third ventricle (between mammillary bodies and infundibular recess at the premammillary membrane). CSF flow causing pulsatile movement at the site of stoma in the floor of third ventricle indicated proper fenestration. Intraoperative bleeding was managed with warm fluid irrigation (►**Fig. 1**).

Postoperative management was done as per the individual case requirement and patients were discharged when clinically stable. Based on clinical parameters, outcomes (ETV success/failure) were assessed on follow-up of patients on the 10th day, and at 1 month and 3 months. ETV was considered successful if resolution or improvement in clinical symptoms such as headache and vomiting occurred. ETV was considered a failure in patients who reported no improvement and/or further deterioration in symptoms and required subsequent VP shunt.

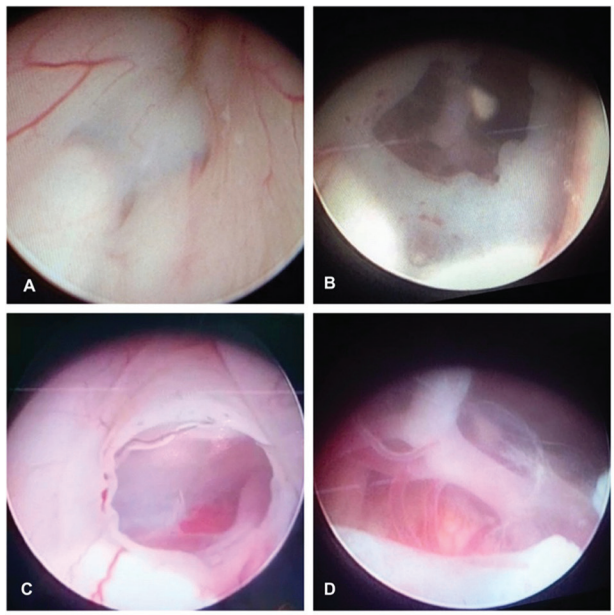

Fig. 1 Endoscopic view. (**A**) Third ventricle floor in a case of post TBM hydrocephalus. (**B**) Stoma created in premammillary membrane in post TBM hydrocephalus. Note the tubercles studded on ventricular walls. (**C**) Stoma created in premammillary membrane in a case of aqueductal stenosis. (**D**) Basilar artery visualized through third ventriculostomy.

Statistical Analysis

The statistical data were analyzed using the IBM SPSS software (Chicago, United States).

Results

Of the total 214 patients admitted with diagnosis of hydrocephalus, 85 patients underwent ETV and were thus included in this study. There were 44.7% (38/85) males and 55.2% (47/85) females in this study. The minimum age in the study was 4 months and the maximum age was 69 years. The mean age in the present study was 15.6 years.

In this study, hydrocephalus was due to tubercular meningitis in 41.2% (35/85) cases, aqueductal stenosis in 17.6% (15/85) cases, posterior fossa space occupying lesion (SOL) in 18.8% (16/85) cases, pineal region SOL in 9.4% (8/85) cases, post meningitis sequelae in 4.7% (4/85) cases, fourth ventricle outlet obstruction in 4.7% (4/85) cases, and third ventricle SOL in 3.5% (3/85) cases (►**Table 1**) (►**Fig. 2**).

In the present study, on follow-up, ETV was found to be successful in 75.2% (64/85) cases. The success rate was highest in cases with obstructive hydrocephalus secondary to

Table 1 Causes of hydrocephalus in study patients

Causes of hydrocephalus	No. of patients	%
Aqueductal stenosis	15	17.6%
Posterior fossa SOL/ brain stem glioma	16	18.8%
Third ventricular SOL	3	3.5%
Pineal region SOL	8	9.4%
Post meningitis	4	4.7%
Post TBM	35	41.2%
Others	4	4.7%

Abbreviations: SOL, space occupying lesion; TBM, tubercular meningitis.

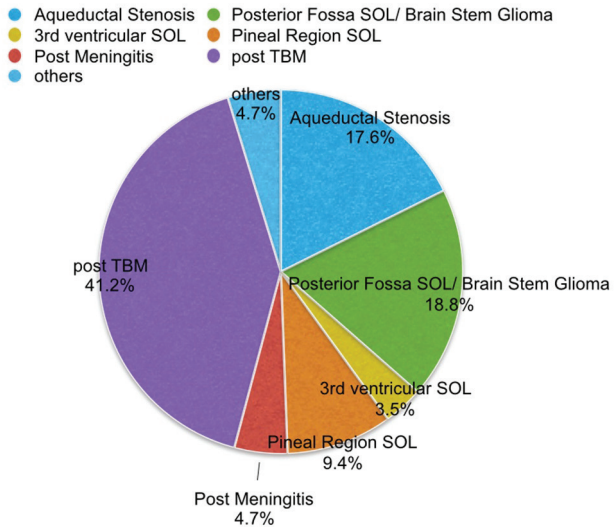

Fig. 2 Pie diagram showing distribution of causative pathologies in the study patients.

aqueductal stenosis (86.7%) followed by post meningitis/TBM (Tubercular Meningitis) hydrocephalus (74.4%) and the least in cases of posterior fossa tumors (71.0%) (►**Fig. 3**).

ETV failure was documented in 21(24.7%) patients who then underwent VP insertion procedure for hydrocephalus (►**Table 2**). Intraoperative bleeding occurred in one case which was controlled by abundant warm irrigation and the procedure was not aborted. In the present study, the mortality rate was nil.

Discussion

At present, the procedure of choice for the treatment of obstructive hydrocephalus is ETV. In cases with ETV failure or lack of ETV facility VP shunt insertion remains the therapeutic procedure of significance. ETV became a preferred procedure due to lesser complications and no requirement of insertion and placing a foreign object for CSF diversion.[5] Post ETV, resolution of clinical signs and symptoms obviates the requirement of another procedure (either repeat ETV or CSF shunting). Reduction in the size of ventricles post ETV is not an important factor in assessing ETV success.[6,7]

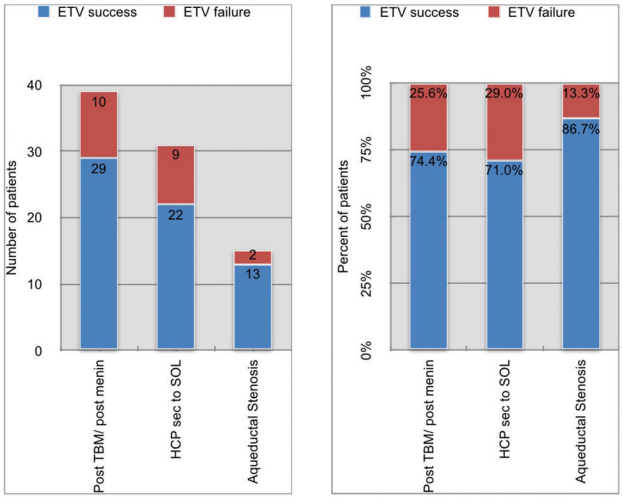

Fig. 3 Bar diagram showing number and percentage of cases of ETV success and failure in major categories of causes for hydrocephalus.

Table 2 Endoscopic third ventriculostomy (ETV) success rates in major categories of hydrocephalus

Causes of hydrocephalus	ETV success	ETV failure	ETV success rate
Post TBM/post meningitis	29	10	74.4%
HCP secondary to SOL	22	9	71.0%
Aqueductal stenosis	13	2	86.7%

Abbreviations: ETV, endoscopic third ventriculostomy; HCP, hydrocephalus; SOL, space occupying lesion; TBM, tubercular meningitis.

Various studies conducted till date reported a wide range of success rates for ETV.[5,8-11] Hopf et al found that ETV reported impressive results in cases with aqueductal stenosis (uncommunicated obstructive hydrocephalus) and in space-occupying lesions. Our study also provided better results with success rate of more than 70% in patients with aqueductal stenosis, posterior fossa tumors, and pineal region tumors. Hopf et al also mentioned that more than 60% of the cases with infective and intraventricular hemorrhage etiology of hydrocephalus responded to ETV. One step further, in the same study, they proposed that shunt failure cases with obstructive hydrocephalus can also be proven to be good candidates for endoscopic third ventriculostomy.[10]

In the present study, three most common causes in decreasing order were post TBM hydrocephalus (45%), aqueductal stenosis (17.5%), and posterior fossa SOL (12.5%). On the contrary, Bouras et al found tumors (37%), aqueductal stenosis (25.9%), and meningomyelocele Chiari II (6.1%) the top three causes in the etiology of hydrocephalus in their study.[12] Another study by Feng et al also reported different trends in etiology of hydrocephalus.[13] The etiology of obstructive hydrocephalus in the present study did not match with previous studies as the prevalence of infectious diseases (post meningitis and post tubercular meningitis) is still quite high in India.

Various studies have reported ETV success rates from 60 to 91.5%.[12,14-17] Mohanty et al reported 86% success of ETV and highlighted the intraoperative opportunity to take biopsy in case of intracranial space-occupying lesions.[17]

On first follow-up after a shorter duration, Kwiek et al reported 96.6% success rate while considering clinical criteria and 90% by radiological criteria.[18] Bouras et al found lesser success rates than Kwiek et al on follow-up done at longer duration by both clinical criteria (83.3%) and by radiological criteria (70%).[19] The overall success rate in our study was 75.3%. However, the success rate was different in various etiologies. Yadav et al mentioned that the importance of preoperative case selection based on etiology of hydrocephalus increased the success rate of ETV and previous shunt surgery and complex hydrocephalus increased the chances of failure of ETV.[15]

In contrast to the previous studies, our study had a large percentage of patients with post meningitis hydrocephalus and post tubercular meningitis hydrocephalus. This was due to high incidence of meningitis and tuberculosis in India. In this study, the success rate of endoscopic third ventriculostomy was 71.4%. Our study showed slightly higher success rate in treatment of patients with post meningitis hydrocephalus and post tubercular meningitis hydrocephalus with ETV compared with another study by Yadav et al where success rate of ETV was 58%.[20]

One of the possible intraoperative complications of ETV includes bleeding which may be due to small cortical vessels injury, thalamostriate and septal vein trauma while inserting the endoscope through the foramen of Monro, or small vessels rupturing during stoma formation during the procedure.[13,20-22] We also witnessed a single case of intraoperative bleeding while stoma formation due to rupture of small vessels which was managed well by warm irrigation.

Conclusion

Endoscopic procedures, though introduced prior to shunt surgeries, had a higher complication and were less preferred earlier. However, with the advancing technologies, the situation has reversed. ETV has regained its importance due to better success rates and lesser complications than shunt surgeries. ETV is an effective treatment modality for obstructive hydrocephalus and with better results in post meningitis hydrocephalus and post tubercular meningitis hydrocephalus. However, more extensive studies dedicated to ETV with a larger sample size are required to further study its efficacy in various etiologies.

Conflict of Interest

None declared.

References

1 Dandy WE. Cerebral ventriculoscopy. Bull Johns Hopkins Hosp 1922;33:189–190
2 Idowu O, Doherty A, Tiamiyu O. Initial experience with endoscopic third ventriculostomy in Nigeria, West Africa. Childs Nerv Syst 2008;24(2):253–255, discussion 257
3 Hellwig D, Grotenhuis JA, Tirakotai W, et al. Endoscopic third ventriculostomy for obstructive hydrocephalus. Neurosurg Rev 2005;28(1):1–34, discussion 35–38
4 Drake JM, Kulkarni AV, Kestle J. Endoscopic third ventriculostomy versus ventriculoperitoneal shunt in pediatric patients: a decision analysis. Childs Nerv Syst 2009;25(4):467–472
5 Yadav YR, Parihar V, Pande S, Namdev H, Agarwal M. Endoscopic third ventriculostomy. J Neurosci Rural Pract 2012;3(2):163–173
6 Fukuhara T, Vorster SJ, Luciano MG. Risk factors for failure of endoscopic third ventriculostomy for obstructive hydrocephalus. Neurosurgery 2000;46(5):1100–1109, discussion 1109–1111
7 Sivakumar W, Drake JM, Cambrin JR, The Role of Third Ventriculostomy in Adults and Children: A Critical Review. Youmans & Winn Neurological Surgery. 7th ed. Philadelphia, PA: Elsevier; 2017 297–303
8 Brockmeyer D, Abtin K, Carey L, Walker ML. Endoscopic third ventriculostomy: an outcome analysis. Pediatr Neurosurg 1998;28(5):236–240
9 Hoppe-Hirsch E, Laroussinie F, Brunet L, et al. Late outcome of the surgical treatment of hydrocephalus. Childs Nerv Syst 1998;14(3):97–99
10 Hopf NJ, Grunert P, Fries G, Resch KD, Perneczky A. Endoscopic third ventriculostomy: outcome analysis of 100 consecutive procedures. Neurosurgery 1999;44(4):795–804, discussion 804–806
11 Brohi SR, Brohi AR, Sidiqui MA, Mughal SA, Saeed S. Outcome of endoscopic third ventriculostomy in hydrocephalus. J Surg Pak Int 2010;15(1):25–28
12 Bouras T, Sgouros S. Complications of endoscopic third ventriculostomy: a systematic review. Acta Neurochir Suppl (Wien) 2012;113:149–153
13 Feng H, Huang G, Liao X, et al. Endoscopic third ventriculostomy in the management of obstructive hydrocephalus: an outcome analysis. J Neurosurg 2004;100(4):626–633
14 Gangemi M, Mascari C, Maiuri F, Godano U, Donati P, Longatti PL. Long-term outcome of endoscopic third ventriculostomy in obstructive hydrocephalus. Minim Invasive Neurosurg 2007;50(5):265–269
15 Yadav YR, Mukerji G, Parihar V, Sinha M, Pandey S. Complex hydrocephalus (combination of communicating and obstructive type): an important cause of failed endoscopic third ventriculostomy. BMC Res 2009;2:137
16 Choi JU, Kim DS, Kim SH. Endoscopic surgery for obstructive hydrocephalus. Yonsei Med J 1999;40(6):600–607
17 Mohanty A, Santosh V, Devi BI, Satish S, Biswas A. Efficacy of simultaneous single-trajectory endoscopic tumor biopsy and endoscopic cerebrospinal fluid diversion procedures in intra- and paraventricular tumors. Neurosurg Focus 2011;30(4):E4
18 Kwiek SJ, Mandera M, Baowski P, et al. Endoscopic third ventriculostomy for hydrocephalus: early and late efficacy in relation to aetiology. Acta Neurochir (Wien) 2003;145(3):181–184
19 Bouras T, Sgouros S. Complications of endoscopic third ventriculostomy. World Neurosurg 2013;79(2, Suppl):22.e9–22.e12
20 Yadav YR, Parihar V, Agrawal M, Bhatele PR. Endoscopic third ventriculostomy in tubercular meningitis with hydrocephalus. Neurol India 2011;59(6):855–860
21 Husain M, Jha D, Vatsal DK, et al. Neuro-endoscopic surgery—experience and outcome analysis of 102 consecutive procedures in a busy neurosurgical centre of India. Acta Neurochir (Wien) 2003;145(5):369–375, discussion 375–376
22 Schroeder HW, Niendorf WR, Gaab MR. Complications of endoscopic third ventriculostomy. J Neurosurg 2002;96(6):1032–1040