

Extrafollicular Adenomatoid Odontogenic Tumor of the Mandible: Report of a Case

Nergiz Yilmaz^a
 Aydan Acikgoz^b
 Nukhet Celebi^a
 A. Zeynep Zengin^b
 Omer Gunhan^c

ABSTRACT

The purpose of this study was to report an extrafollicular adenomatoid odontogenic tumor in the mandibular anterior region in a patient. A 15 year-old female with a painless swelling in the mandibular anterior region was referred to our clinic. Fine needle aspiration yielded no fluid. Periapical, panoramic and computer tomography scans showed circumscribed radiolucent area with fine calcifications. The lesion was totally enucleated and the teeth 31, 32 were removed. The rarity of adenomatoid odontogenic tumor may be associated with its slowly growing pattern and symptomless behavior. Therefore, it should be distinguished from more common lesions of odontogenic origin in routine dental examinations. (Eur J Dent 2009;3:71-74)

Key words: Odontogenic; Tumor; Extrafollicular.

INTRODUCTION

Adenomatoid odontogenic tumor (AOT) is an uncommon, benign and slow growing tumor which is usually located in the anterior region of the maxilla without pain,^{1,2} and represents 3% of all odontogenic tumors.³ It often causes expansion of surrounding bone and displacement of adjacent

teeth.⁴ However, the slow growing nature of the lesion may cause the patients tolerate the swelling for years until it produces an obvious deformity.⁵ The tumor is usually associated with unerupted teeth, frequently canines or lateral incisors.⁶ In this report of a case, we presented an AOT causing jaw swelling in the mandibular anterior region.

CASE REPORT

A 15-year-old female was referred to the Department of Oral Diagnosis and Radiology, Faculty of Dentistry, University of Ondokuz Mayis by her dental practitioner with a diagnosis of a painless swelling in the mandibular anterior region. The patient had no systemic diseases nor used any medication. There was no history of trauma, pain, discharge or any other symptoms

^a Ondokuz Mayıs University, Faculty of Dentistry, Department of Oral and Maxillofacial Surgery, Samsun, Turkey.

^b Ondokuz Mayıs University, Faculty of Dentistry, Department of Oral Diagnosis and Radiology, Samsun, Turkey.

^c Gulhane Military Medical School, Department of Pathology, Ankara, Turkey.

■ Corresponding author: Dt. Nukhet Celebi
 19 Mayıs Üniversitesi, Dis Hekimligi Fakultesi,
 Agiz Dis, Cene Hastaliklari ve Cerrahisi
 Kurupelit, Samsun, Turkey.
 E-mail: nukh@hotmail.com

related to the lesion. In the clinical examination of the head and neck, chronic lymphadenopathy was found on the right and left submandibular lymph nodes. Facial asymmetry or swelling was not observed. Intraorally, the patient presented a painless, slowly increasing swelling in the mandibular anterior region. A mild labiolingual expansion was seen on the mandibular anterior alveolus in relation to teeth 32 to 41. The tooth 32 was not responsive to electrometric pulp testing. The swelling had well defined margins with normal overlying mucosa. The swelling was bony hard and non-tender on palpation. Fine needle aspiration yielded no fluid. Periapical and panoramic radiographs showed circumscribed radiolucent area with fine calcifications involving the teeth 32 to 41 (Figure 1). No root resorption but the displacement of these teeth was seen. Occlusal radiograph presented a moderate labiolingual expansion, and a thinned cortical layer. Computed Tomography (CT) scans demonstrated the radiolucent lesion with a radiopaque foci, and loss of cortical bone (Figure 2). The possibilities of ameloblastoma and calcifying odontogenic tumor were considered preoperatively. The lesion was totally enucleated and the teeth 31,32 were removed. The surrounding bone was polished with a diamond burr. Because of the exposition of the root of

the tooth 41, the apical one third was resected after endodontic treatment, intraoperatively. Gross examination of the specimen showed a single pink-white soft tissue measuring 2x1.5 cm (Figure 3). Microscopy revealed a well-defined cystic tumor encapsulated with a thick, regular fibrous connective tissue (Figure 4A). The tumor consisted of ameloblast-like epithelial cells forming ductus-like structures. Eosinophilic droplets and irregular displaced odontogenic calcification areas were seen amongst the epithelial cells (Figure 4B). The final diagnosis of AOT was obtained. Healing was uneventful 6 months after the surgery (Figure 5).

DISCUSSION

The AOT is an uncommon cause of jaw swelling.⁷ There is a slightly female over male incidence, an almost 2:1,⁸ and appears most often in the second decade of life.^{9,10} The sex and the age of the patient we described in this report was consisted with the literature. The lesions are typically asymptomatic, but may cause cortical expansion and displacement of the adjacent teeth,¹¹ as in the case reported here. The origin of the AOT is controversial.^{12,13} Because of its predilection for tooth-bearing bone, it is thought to arise from odontogenic epithelium.⁴

The tumor has three clinicopathologic variants,

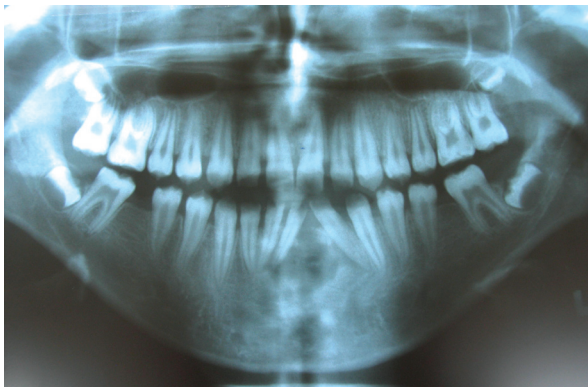


Figure 1. Pre-operative panoramic view.

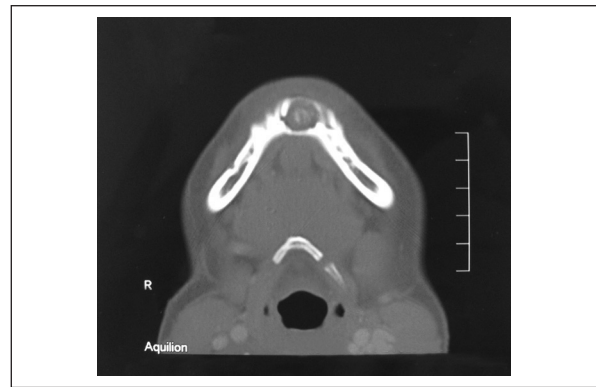


Figure 2. CT scan presents the calcifications.

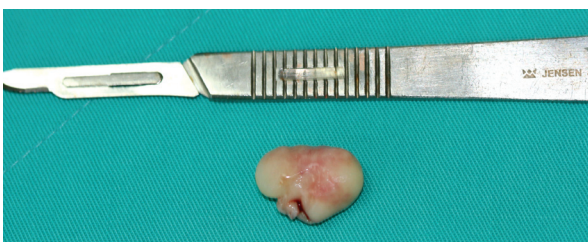

Figure 3. The tumour was totally enucleated.

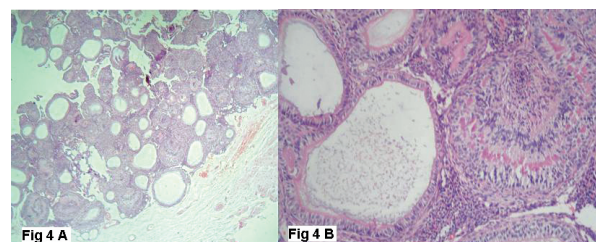


Figure 4. Microscopy demonstrating features typical of AOT. Tuumor with fibrous connective tissue capsule (A). Ductus-like structures and calcification areas (B).

namely intraosseous follicular, intraosseous extrafollicular, and peripheral. The follicular type (in 73% of all AOT cases) is associated with an unerupted tooth whereas extrafollicular type (24%) has no relation with an impacted tooth¹⁴ as in the case we presented here, and the peripheral variant (3%) is attached to the gingival structures. Follicular and extrafollicular types are over two times more located in the maxilla than in the mandible,¹⁵ and most of the tumors involve anterior aspect of the jaws.^{2,16} In our case, the tumor was an extrafollicular intraosseous type, and also found in the anterior region of the mandible.

Although larger lesions reported in the literature,¹⁷ the tumors are usually in the dimensions of 1.5 to 3 cm.⁶ Radiographically, they usually appear unilocular,^{6,17} may contain fine calcifications,² and irregular root resorption is rare.⁶ This appearance must be differentiated from various types of disease, such as calcifying odontogenic tumor or cysts. The differential diagnosis can also be made with ameloblastoma, ameloblastic fibroma and ameloblastic fibroodontoma.⁷ The patient we describe in this report presented no root resorption, but displacement of the adjacent teeth, and also the tumor was not associated with an impacted tooth. Radiographically, it was easily differentiated from dentigerous cyst, which usually occurs as a pericoronal radiolucency.

The histological findings for AOT are remarkably similar in the literature.^{4,9,11} The histological features of the tumor were described as a tumor of odontogenic epithelium with duct like structures and with varying degree of inductive changes in the connective tissue. The tumor may be partly cystic and in some cases the solid lesion may be present only as masses in

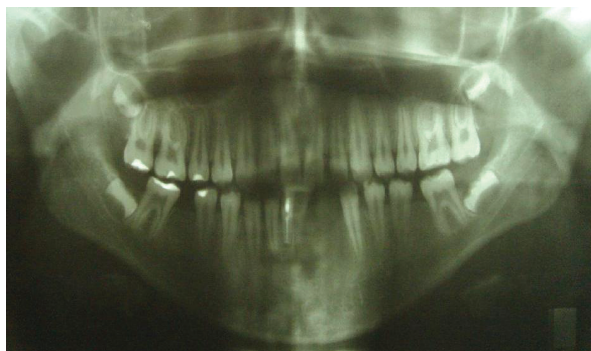

Figure 5. Post-operative 6th month panoramic view.

the wall of a large cyst.¹⁸ The tumor may contain pools of amyloid-like material and globular masses of calcified material.¹⁹ Our case was consisted with these common features reported in the literature.

The tumor is well encapsulated and show an identical benign behavior.¹⁵ Therefore, conservative surgical enucleation produces excellent outcome without recurrence.²⁰ Our patient has been under follow-up for 6 months.

CONCLUSIONS

Because of being the extrafollicular variant of AOT, and with respect to the localization of the lesion in the mandible, our case is a rare case of AOTs. Additionally, it supports the above mentioned general description of AOT in the previous studies. We conclude that the rarity of AOT may be associated with its slowly growing pattern and symptomless behavior. Therefore, it should be distinguished from more common lesions of odontogenic origin in routine dental examinations.

REFERENCES

1. Philipsen HP, Reichart PA, Zhang KH, Nikai H, Yu QX. Adenomatoid odontogenic tumor: biologic profile based on 499 cases. *J Oral Pathol Med* 1991;20:149-158.
2. Toida M, Hyodo I, Okuda T, Tatematsu N. Adenomatoid odontogenic tumor: report of two cases and survey of 126 cases in Japan. *J Oral Maxillofac Surg* 1990;48:404-408.
3. White SC, Pharaoh MJ. Oral Radiology. Principles and Interpretation. 5th ed, St. Louis, Mosby, 2004, p.431-433.
4. Bravo M, White D, Miles L, Cotton R. Adenomatoid odontogenic tumor mimicking a dentigerous cyst. *Int J Pediatr Otorhinolaryngol* 2005;69:1685-1688.
5. Olgac V, Koseoglu BG, Kasapoglu C. Adenomatoid odontogenic tumor: a report of an unusual maxillary lesion. *Quintessence Int* 2003;34:686-688.
6. Dayi E, Gurbuz G, Bilge OM, Ciftcioglu MA. Adenomatoid odontogenic tumour (adenoameloblastoma). Case report and review of the literature. *Aust Dent J* 1997;42:315-318.
7. Nigam S, Gupta SK, Chaturvedi KU. Adenomatoid odontogenic tumor - a rare cause of jaw swelling. *Braz Dent J* 2005;16:251-253.
8. Ajagbe HA, Daramola JO, Junaid TA, Ajagbe AO. Adenomatoid odontogenic tumor in a black African population: report of thirteen cases. *J Oral Maxillofac Surg* 1985;43:683-687.

9. Handschel JG, Depprich RA, Zimmermann AC, Braunstein S, Kübler NR. Adenomatoid odontogenic tumor of the mandible: review of the literature and report of a rare case. *Head Face Med* 2005;24:3.
10. Vera-Sempere FJ, Artes-Martínez MJ, Vera-Sirera B, Bonet-Marco J. Follicular adenomatoid odontogenic tumor: Immunohistochemical study. *Med Oral Patol Oral Cir Bucal* 2006;11:E305-308.
11. Batra P, Prasad S, Parkash H. Adenomatoid odontogenic tumour: review and case report. *J Can Dent Assoc* 2005;71:250-253.
12. Giansanti JS, Someren A, Waldron CA. Odontogenic adenomatoid tumor [adenoameloblastoma]. Survey of 3 cases. *Oral Surg Oral Med Oral Pathol* 1970;30:69-88.
13. Odontogenic cyst giving rise to an adenomatoid odontogenic tumor: report of a case with peculiar features. Tajima Y, Sakamoto E, Yamamoto Y. *J Oral Maxillofac Surg* 1992;50:190-193.
14. Philipsen HP, Srisuwan T, Reichart PA. Adenomatoid odontogenic tumor mimicking a periapical (radicular) cyst: a case report. *Oral Surg Oral Med Oral Pathol Oral Radiol Endod* 2002;94:246-248.
15. Philipsen HP, Reichart PA. Adenomatoid odontogenic tumour: facts and figures. *Oral Oncol* 1998;35:125-131.
16. Swasdison S, Dhanuthai K, Jankittivong A, Philipsen HP. Adenomatoid odontogenic tumors: an analysis of 67 cases in a Thai population. *Oral Surg Oral Med Oral Pathol Oral Radiol Endod* 2008;105:210-215.
17. Larsson A, Swartz K, Heikinheimo K. A case of multiple AOT-like jawbone lesions in a young patient--a new odontogenic entity? *J Oral Pathol Med* 2003;32:55-62.
18. Kramer IR, Pindborg JJ, Shear M. WHO International histological classification of tumours. Histological typing of odontogenic tumours. 2nd ed. Berlin, Springer Verlag, 1992
19. Takeda Y, Kudo K. Adenomatoid odontogenic tumor associated with calcifying epithelial odontogenic tumor. *Int J Oral Maxillofac Surg* 1986;15:469-473.
20. Motamedi MH, Shafeie HA, Azizi T. Salvage of an impacted canine associated with an adenomatoid odontogenic tumour: a case report. *Br Dent J* 2005;199:89-90.