


# Functional and Radiological Outcomes of the Surgical Treatment of Acute Acromioclavicular Dislocation with Anchors Associated with Clavicle and Scapula Fixation\*

## *Resultados funcionais e radiológicos do tratamento cirúrgico da luxação acromioclavicular aguda com âncoras e fixação clavículo-escapular*

Adriano Fernando Mendes Júnior<sup>1</sup>  José da Mota Neto<sup>1</sup> Darlan Malba Dias<sup>2</sup>  
Leandro Furtado de Simoni<sup>3</sup> Elmano de Araújo Loures<sup>1</sup> Pedro José Labronici<sup>4</sup>

<sup>1</sup> Department of Orthopedics and Traumatology, Hospital Universitário, Universidade Federal de Juiz de Fora, Juiz de Fora, MG, Brazil

<sup>2</sup> Orthopedics and Traumatology Service, Hospital Santa Luzia, Brasília, DF, Brazil

<sup>3</sup> Hospital Maternidade Therezinha de Jesus, Juiz de Fora, MG, Brazil

<sup>4</sup> Department of Surgery, Universidade Federal Fluminense (UFF), Niterói, RJ, Brazil

Address for correspondence Adriano Fernando Mendes Júnior, MD, MSc, Rua Sampaio 468, apto. 1.402, Juiz de Fora, MG, 36010-360, Brasil (e-mail: adrianofmj@yahoo.com.br).

Rev Bras Ortop 2019;54:649–656.

### Abstract

**Objective** To evaluate the clinical, radiological and functional results of the surgical treatment of acute acromioclavicular dislocation using a coracoclavicular fixation technique (syndesmopexy) with two metallic anchors, temporary clavicle and scapula fixation, and transfer of the coracoacromial ligament.

**Methods** Longitudinal observational study of 30 patients with diagnoses of acute acromioclavicular dislocation, who were submitted to surgical treatment with a minimum follow-up of six months, and who were evaluated clinically, radiologically, and by the University of California at Los Angeles (UCLA), the Disabilities of the Arm, Shoulder and Hand (DASH) and the Constant-Murley functional scores.

**Results** The mean values of the scores were: UCLA = 32; DASH = 11.21; and Constant-Murley = 86.93, with satisfactory results higher than 80%. The unsatisfactory results were associated with acromioclavicular pain on palpation, positive subacromial impingement tests, and older age group, presenting statistical significance ( $p < 0.05$ ). Radiologically, higher values on account of the coracoclavicular distance ratio from the operated shoulder compared to the normal shoulder were related to worse outcomes, but with no statistically significant difference. No associations were found between the results of the functional scores and the variables degree of the injury, coracoacromial ligament transfer, clinical impression of loss of reduction and scapulothoracic dyskinesia.

### Keywords

- ▶ acromioclavicular joint
- ▶ treatment outcome
- ▶ suture anchors

\* Study developed at Hospital Universitário, Universidade Federal de Juiz de Fora, Juiz de Fora, MG, Brazil

## Resumo

### Palavras-chave

- ▶ articulação acromioclavicular
- ▶ resultado do tratamento
- ▶ âncoras de sutura

**Conclusion** The technique used provides an efficient fixation, with a high level of satisfaction according to the UCLA, Constant-Murley and DASH scores; moreover, it has a low complication rate, despite the high rate of residual radiological acromioclavicular subluxation.

**Objetivo** Avaliar os resultados clínicos, radiológicos, e funcionais do tratamento cirúrgico da luxação acromioclavicular aguda, utilizando a técnica de sindesmopexia coracoclavicular com duas âncoras metálicas, fixação temporária clavículo-escapular, e transferência do ligamento coracoacromial.

**Métodos** Estudo observacional longitudinal com trinta pacientes com diagnóstico de luxação acromioclavicular aguda submetidos à cirurgia, com seguimento mínimo de seis meses, avaliados clínica, radiograficamente, e pelos escores de University of California at Los Angeles (UCLA), Disabilities of the Arm, Shoulder and Hand (DASH) e Constant-Murley.

**Resultados** Os valores médios dos escores foram: UCLA = 32; DASH = 11,21; e Constant-Murley = 86,93, com resultados satisfatórios acima de 80%. Os resultados insatisfatórios foram relacionados à dor acromioclavicular, a testes de impacto subacromial positivos, e aos pacientes de faixa etária mais elevada ( $p < 0,05$ ). Radiologicamente, valores maiores em razão da distância coracoclavicular do ombro operado, comparado com o ombro normal, foram relacionados a piores resultados, embora sem significância estatística. Não foi observada associação entre os resultados dos escores funcionais e as variáveis grau da lesão, transferência do ligamento coracoacromial, impressão clínica de perda de redução, e discinesia escapulo-torácica.

**Conclusão** A técnica utilizada propicia uma fixação eficiente, com alto índice de satisfação segundo os escores de UCLA, Constant-Murley e DASH. Observou-se baixo índice de complicações apesar da frequência elevada de subluxação acromioclavicular radiológica residual.

## Introduction

Acromioclavicular dislocation (ACD) is a frequent lesion, which usually occurs after a fall to the ground, with direct trauma to the shoulder, and the arm in adduction.<sup>1</sup> It accounts for 9 to 12% of shoulder girdle injuries, and is more frequent in young adults, athletes, and five times more common in men than in women.<sup>1,2</sup> Most lesions of the acromioclavicular (AC) complex are incomplete, mainly affecting the AC ligaments.<sup>1</sup> In cases of trauma of greater intensity of this complex, injuries also occur in the coracoclavicular (CC) ligaments and deltotrapezoidal fascia, which are stabilizers of the AC joint (ACJ).<sup>2</sup>

Acromioclavicular lesions were originally described by Tossy et al<sup>2</sup> as grades I, II and III, and were subsequently modified by Rockwood and Williams,<sup>3</sup> who described grades IV, V and VI. This classification presents good reproducibility among orthopedists,<sup>3</sup> and it is also used to guide the indication of clinical or surgical treatment. According to Rockwood and Williams,<sup>3</sup> surgical treatment is recommended for grades IV, V and VI, and for some cases of grade III. The conservative treatment is indicated for cases of grades I and II. There is controversy about the optimal treatment of ACD, especially regarding cases of grade III.<sup>4</sup> Surgical treatment options include fixation of the ACJ with wires or a plate, whether or

not associated with coracoacromial (CA) ligament transfer, CA fixation with a CC screw or CC anchors, temporary fixation with Kirschner wires, and ligament reconstruction.<sup>3-5</sup>

There is no consensus regarding the treatment of this lesion.<sup>5</sup> The techniques that bring the clavicle closer to the coracoid process (syndesmopexy) have shifted from the use of subcoracoid screws or ties to the use of anchors and materials such as Endobutton (Smith & Nephew, London, United Kingdom), which can be made by open, minimally-invasive or arthroscopic methods. The technique of the surgical treatment of acute ACD with CC stabilization using two anchors has the advantage of mimicking the anatomical origin of the CC ligaments and their insertions in the clavicle;<sup>6</sup> another advantage is the use of an implant that is accessible to Brazilian orthopedists.

The aim of the present study is to evaluate the clinical, radiological and functional results of the surgical treatment of acute ACD using the technique of CC syndesmopexy with two metallic anchors and temporary clavicle and scapula fixation.

## Materials and Methods

The present study, was approved by the Ethics in Research Committee of our institution (CAAE 58252216.0.0000.5133), and all selected individuals agreed to participate by signing the informed consent form. This is an observational longitudinal

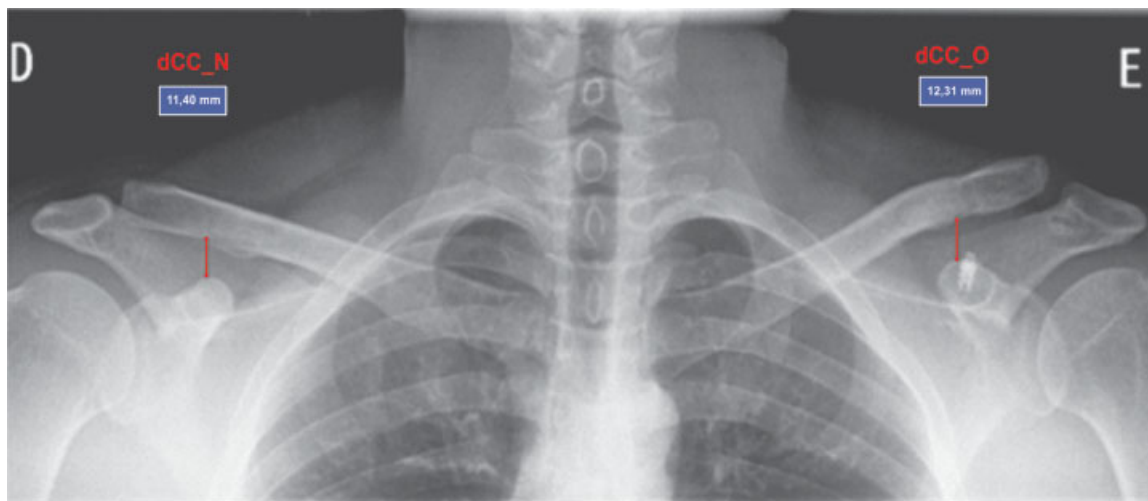
study of patients with acute ACD surgically treated by three surgeons participating in the study, using the technique of CC syndesmopexy with two metallic anchors and temporary clavicle and scapula fixation in tertiary hospitals in the period from January 2011 to March 2016. The sample studied was comprised of 41 individuals submitted to surgery for the treatment of acute ACD of grades III, IV and V according to the classification by Rockwood and Williams.<sup>3</sup> The inclusion criteria were: age > 18 years, surgery performed 6 months or more before the date of the assessment, and surgical treatment of acute ACD by the aforementioned technique considering, for temporal effect, the period of up to 3 weeks as acute ACD.<sup>7</sup> The exclusion criteria were: history of previous ACD in the same limb, previous surgery on the same shoulder, and inability to answer the functional assessment questionnaires or to attend the outpatient reevaluation. Out of the 41 patients, 1 was in a coma due to complications unrelated to the surgical procedure; 4 refused to participate in the study; 2 did not fit the criteria for the treatment of acute ACD; and 4 were not found for evaluation. The final sample consisted of 30 participants whose medical records were analyzed, and the patients were submitted to functional and radiological evaluations.

The primary outcome of the study was the UCLA functional score,<sup>8</sup> followed by the DASH<sup>9</sup> and Constant-Murley<sup>10</sup> scores, and the results found were classified as satisfactory or unsatisfactory.<sup>8,11</sup> The secondary outcomes evaluated were: CA ligament transfer in the procedure; complications arising from surgery; mean age of the patients; clinical examination data (clinical impression of loss of ACD reduction, scapulothoracic dyskinesia [STD], AC pain on palpation, subacromial and AC impingement maneuvers, such as the Neer, Hawkins-Kenedy, Yokun and cross body adduction tests);<sup>12</sup> and radiological evaluation (loss of reduction, AC degeneration).

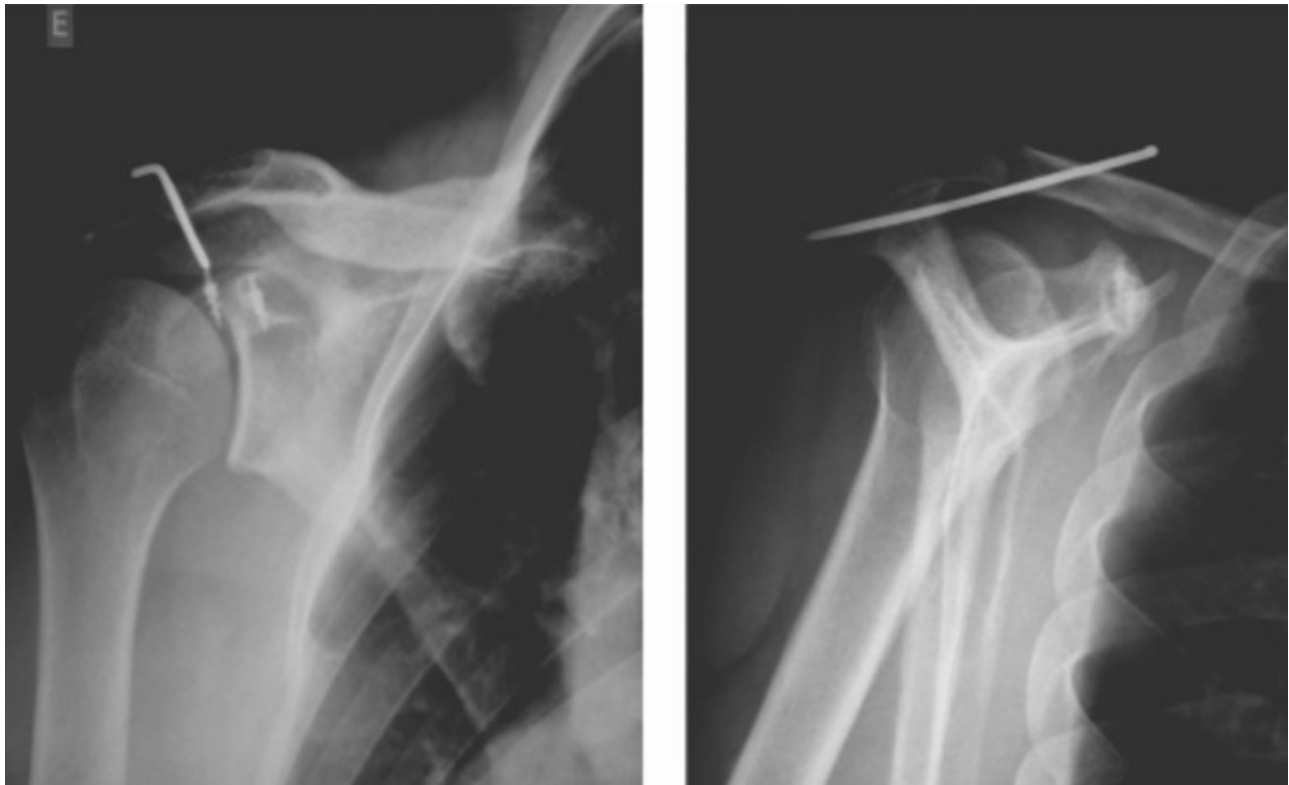The diagnosis of ACD, as well as the classification by Rockwood and Williams,<sup>3</sup> was radiographically performed in the anteroposterior (AP) and Zanca incidences for the clavicle and shoulder axillary profile.<sup>13</sup> The radiological evaluation also used a ratio as a comparative measure of the CC distance (CCd) of the operated and normal sides

(CCd\_O/N), in the radiograph of the clavicle in the AP and Zanca incidences, dividing the value of the CCd of the operated side (CCd\_O) by the one of the normal side (CCd\_N), as demonstrated in ►Figure 1. We also adopted the radiological criteria according to Rush et al<sup>14</sup> for the assessment of the postoperative AC reduction, considering loss of postoperative reduction an increase in CCd\_O/N  $\geq 2$ , and residual subluxation as CCd\_O/N between 1 and 2.

The procedure was performed with the patient in the beach chair position, under brachial plexus block and general anesthesia. A saber-type incision was made in the AP direction, starting 1 cm medial to the acromioclavicular joint, from the posterior edge of the clavicle up to 1 cm superior to the upper edge of the coracoid process. When intact, the deltotrachezoidal fascia was incised parallel to its fibers. In some patients, at the surgeon's discretion, the CA ligament was identified, which was dissected until its acromial origin, and then sectioned and repaired for transfer to the lateral third of the clavicle in transosseous fixation. Through dissection, the base of the coracoid process was exposed, enabling the insertion of two 4-mm metallic anchors, each with 1 or 2 non-absorbable suture threads, adapted according to the technique of Dal Molin et al.<sup>6</sup> The sutures were inserted into 2 holes made in the clavicle with a 2.0-mm drill to reproduce the anatomical insertion of the coracoclavicular ligaments: a posteromedial orifice for the conoid ligament and, 1 cm laterally, an anterolateral orifice of the same size, for the trapezoid, at a distance of 1 cm from the ACJ. Prior to the CC approach with the anchor sutures, the ACJ was anatomically reduced: while the assistant performed the retracting scapula stabilization maneuver and the clavicle reduction, the surgeon performed clavicle-spinal fixation by directing a 2.5-mm Kirschner wire from the anterior superior edge of the lateral third of the clavicle to the base of the scapular spine, according to the technique described by Carrera et al<sup>15</sup> (►Figure 2). The anchor sutures previously inserted into the holes in the collarbone were tied, and the CA ligament, when transferred, was tensioned. The deltotrachezoidal fascia was carefully sutured, the Kirschner wire was



**Fig. 1** Calculation of the coracoclavicular distance of the operated and normal sides (CCd\_O/N: 12.31/11.40 = 1.07). Patient with 7% of residual subluxation



**Fig. 2** Postoperative anteroposterior (AP) radiograph of the shoulder and profile of the scapula in the postoperative period, showing the anchors in the coracoid process and the temporary fixation Kirschner wire between the clavicle and the scapular spine.

buried under the fascia, and the final closure by layers was performed.

Postoperatively, the limb was immobilized in an abduction sling for 6 weeks. The patient was instructed to immediately begin elbow flexion/extension exercises and gentle medial and lateral shoulder rotation. Shoulder elevation  $> 45$  degrees was discouraged to prevent the clavicular and scapular Kirschner wire from breaking, migrating or having its insertion loosened. After six weeks, the Kirschner wire was removed in the operating room under local anesthesia and sedation, and the patient was allowed to perform all shoulder movements and begin physical therapy rehabilitation. Return to contact sports was allowed after three months of surgery.

The statistical analysis, with quantitative variables, was described by mean and standard deviation, and the qualitative variables, by absolute frequency and percentages. To test for differences between the groups with respect to the quantitative variables, the Mann-Whitney U test was used. The effect size was evaluated by Cohen  $d^{16}$ , using the weighted standard deviation and adopting the following classification for interpretation: small = 0.20–0.49; moderate = 0.50–0.79; high  $\geq 0.80$ .<sup>16</sup> To test for differences between proportions, the Fisher exact test was used. In this case, the effect size was evaluated by Cramér V, adopting the following classification for interpretation: small = 0.10–0.29; moderate = 0.30–0.49; high  $\geq 0.50$ .<sup>16</sup> All analyses were performed using the International Business Machines Statistical Package for the Social Sciences (IBM SPSS, IBM Corp., Armonk, NY, US) software, version 24.0. The level of statistical significance was established as  $p < 0.05$ . To calculate the sample size,

when necessary, we used the G\*Power 3.1 (Universität Düsseldorf, Düsseldorf, North Rhine-Westphalia, Germany) software.<sup>17</sup>

## Results

Thirty individuals met the inclusion criteria, most of them male ( $n = 28$ ; 93.3%). The median follow-up was of 18 months (7 to 40 months), the average age of the patients was 40 years ( $\pm 12.7$ ; 20 to 71 years), and 28 of them were right-handed (93.3%). The dominant limb was affected in 15 patients (50%). The average time to surgery was of 6 days ( $\pm 6.4$ ). The most common causes were fall to the ground ( $n = 9$ ), fall from a bicycle ( $n = 9$ ) and fall from a motorcycle ( $n = 8$ ). According to the classification of Rockwood and Williams,<sup>3</sup> the patients were classified as grade III ( $n = 16$ ), grade IV ( $n = 3$ ) and grade V ( $n = 11$ ). The CA ligament transfer was performed in 17 patients (56.7%). A total of 5 cases (16.6%) developed acute postoperative complications: 1 case of prominent Kirschner wire, which caused discomfort in the posterior shoulder region; 1 case of Kirschner wire exteriorization in the sixth postoperative week, both resolved by wire removal in the sixth week after surgery; 2 cases of surgical wound infection treated with oral antibiotics for 10 days; and 1 case of deep infection requiring surgical lavage and debridement, followed by intravenous antibiotics for 2 weeks.

In the clinical evaluation, 6 patients (20.0%) presented AC pain on palpation, and 10 patients (30.0%) presented STD. Positive subacromial impingement tests were observed in 6 patients (20%), and the clinical impression of loss of reduction after surgery, assessed by the observer, was perceived in

9 patients (30%). The spontaneous satisfaction rate with the treatment was of 96.87%.

In the functional evaluation, the final mean values (standard deviation) of the functional scores were: UCLA = 32 (±6.33); DASH = 11.21 (±20.18); and Constant-Murley = 86.93 (±20.34). In the classification of the score results as satisfactory or not, we found that 86.7% of the sample had satisfactory UCLA (> 27) scores; 83.3% had satisfactory DASH (<20) scores; and 80.0% had satisfactory Constant-Murley (> 79) scores.

At the radiological evaluation, AC degeneration was observed in 4 patients (13.3%). According to criteria of Rush et al,<sup>14</sup> 2 cases (6.6%) showed loss of reduction in the AP incidence, and 4 cases (13.3%), in the Zanca incidence. Residual subluxations were observed in 24 patients (80%) in the AP incidence, and in 20 patients (67%) in the Zanca incidence. Only 4 patients (13%) in the AP incidence and 6 patients (20%) in the Zanca incidence kept the reduction on the opposite side.

The comparison of the clinical characteristics and the UCLA, DASH and Constant-Murley scores is presented in **Table 1**. The patients with unsatisfactory functional results were found to have AC pain on palpation, positive subacromial impingement tests, and higher mean age when compared to the patients with satisfactory functional results. Patients aged > 50 years presented worse functional results. For these variables, the relationships and differences observed were of high magnitude ( $d > 0.80$ ;  $V > 0.50$ ). The degree of AC dislocation and STD are not associated with the functional results evaluated by the UCLA, DASH e Constant-Murley scores ( $p > 0,05$ ).

Radiologically, we observed that AC degeneration was more frequent in patients with unsatisfactory results evaluated by the UCLA, although this result was within the significance threshold ( $p = 0.07$ ). Considering the 15% prevalence of unsatisfactory UCLA results, a sample size of 45 patients is estimated

in order to be able to find a statistically significant association between the AC degeneration observed on radiography and the functional outcome assessed by the UCLA.<sup>17</sup>

The measure of the CCd\_O/N in the AP and Zanca radiological incidences was correlated with the clinical data and functional scores. We found that patients with unsatisfactory results in the functional scores presented higher values of the CCd\_O/N, but this was not statistically significant ( $p > 0.05$ ); however, the effect size observed in the DASH and Constant-Murley scores for the association of the CCd\_O/N in the Zanca incidence was of moderate magnitude ( $d = 0.66$  e  $d = 0.56$  respectively). As a sample calculation, considering the proportion of 17% of patients with unsatisfactory functional results, 204 patients would be needed (30 patients with unsatisfactory results) in order to be able to observe a statistical significance between the increase in the CCd\_O/N and worse results in the functional questionnaires.<sup>17</sup>

No statistically significant difference was observed in the dCC\_O/N in the AP and Zanca incidences in relation to the degree of the lesion ( $p > 0.05$ ), to the CA ligament transfer ( $p > 0.05$ ), and to the clinical impression of loss of reduction ( $p > 0.05$ ). To evaluate the relationship between the amount of radiological subluxation and the clinical/functional aspects, we adopted the cut-off point of 1.5 in the dCC\_O/N. There was no statistically significant association with the functional scores. (**Table 2**;  $p > 0.05$ ).

Finally, CA ligament transfer during surgery showed no difference in the functional scores, and was not related to the clinical impression of loss of reduction or to the dCC\_O/N in the AP and Zanca incidences.

### Discussion

The goal of acute ACD treatment is to achieve a reduction that enables soft tissue healing and recovery of previous joint

**Table 1** Association between the clinical evaluation and the UCLA, DASH and Constant-Murley functional scores

Variables/ Categories	UCLA			DASH			Constant-Murley		
	S (n = 26)	U (n = 4)	p-value	S (n = 25)	U (n = 5)	p-value	S (n = 24)	U (n = 6)	p-value
<i>ACD grade</i>									
III (n = 16)	87.50%	12.50%	1	81.30%	18.80%	1	81.20%	18.80%	1
IV and V (n = 14)	85.70%	14.30%		85.70%	14.30%		78.60%	21.40%	
<i>AC pain</i>									
No (n = 24)	100.00%	0.00%	0.001*	95.80%	4.20%	0.003*	91.70%	8.30%	0.007*
Yes (n = 6)	33.30%	66.70%		33.30%	66.70%		33.30%	66.70%	
<i>Impingement tests</i>									
No (n = 24)	100.00%	0.00%	0.001*	100.00%	0.00%	< 0.001*	95.80%	4.20%	< 0.001*
Yes (n = 6)	33.30%	66.70%		16.70%	83.30%		16.70%	83.30%	
<i>Age (years; mean ± standard deviation)</i>	38.2 ± 11.7	56.7 ± 3.2	0.005*	38.0 ± 11.9	54.0 ± 6.7	0.006*	37.4 ± 11.7	53.8 ± 6.0	0.002*

Abbreviations: AC, acromioclavicular; ACD, acromioclavicular dislocation; DASH, Disabilities of the Arm, Shoulder and Hand; S, satisfactory; U: unsatisfactory; UCLA, University of California at Los Angeles .

Notes: Percentages: relative to the lines; p-value: Fisher exact test and Mann-Whitney U test; \*significant difference,  $p < 0.05$ ; #significance threshold.

**Table 2** Relationship of the mean values of the functional scores and CCd\_O/N on the AP and Zanca radiographs

Variable	n	DASH	p-value	Constant-Murley	p-value	UCLA	p-value
CCd_O/N AP			0.92		0.41		0.84
< 1.5	23	11.9 ± 21.1 <sup>a</sup>		87.8 ± 19.7 <sup>a</sup>		32.0 ± 6.1 <sup>a</sup>	
≥ 1.5	7	8.9 ± 18.0 <sup>a</sup>		84.0 ± 23.7 <sup>a</sup>		31.8 ± 7.4 <sup>a</sup>	
CCd_O/N Zanca			0.22		0.19		0.61
< 1.5	18	9.3 ± 19.9 <sup>a</sup>		89.7 ± 18.5 <sup>a</sup>		32.7 ± 4.8 <sup>a</sup>	
≥ 1.5	12	14.1 ± 21.1 <sup>a</sup>		82.8 ± 23.0 <sup>a</sup>		30.9 ± 8.2 <sup>a</sup>	

Abbreviations: AP, anteroposterior; DASH, Disabilities of the Arm, Shoulder and Hand; CCd\_O/N, coracoclavicular distance of the operated and normal sides; UCLA, University of California at Los Angeles.

Notes: <sup>a</sup>Mean ± standard deviation; \*p-value calculated by the Mann-Whitney test.

function; however, the numerous procedures described in the literature show the lack of consensus regarding the ideal method.<sup>18</sup> The mean values of the functional scores were: UCLA = 32 (±6.33); DASH = 11.21 (±20.18); and Constant-Murley = 86.93 (±20.34), with overall satisfaction of 96.87% (all but 1 patient in the sample). Algarín et al<sup>19</sup> evaluated 42 patients treated with a minimally-invasive technique, and obtained 86% of satisfactory results according to the UCLA score.

There are several surgical options for the treatment of ACD, and they are didactically divided as flexible CC fixation techniques (such as CC ties or anchor fixation) or rigid CC fixation techniques (such as CC screws or hook plates). The so-called flexible options are considered more biological because they provide the movement of the clavicle in relation to the acromion, and do not require the removal of the implants. The CC fixation with screw generates excessive stiffness in the ACJ, which may lead to implant breakage, acromial or clavicular osteolysis, loss of reduction, and need for a new procedure for removal.<sup>5</sup> The use of the hook plate has a high rate of complications, including acromial osteolysis or fracture, subacromial bursitis, and osteoarthritis.<sup>20,21</sup> According to Koukakis et al,<sup>20</sup> the removal of the implant transfers the responsibility for maintaining the reduction only to scar tissue, favoring recurrence.

Even the so-called flexible options are not risk-free. According to Baker et al,<sup>22</sup> high-strength wire subcoracoid cerclage can cause local bone erosion and maintain the anterior clavicle subluxation, which has been shown to cause pain, arthritis and decreased strength. Fixation of the clavicle to the coracoid process with suture anchors and the use of a temporary metal pin between the clavicle and the scapular spine presents an alternative to avoid complications and simplify temporary fixation.<sup>15</sup> In the patients of the present study, CC anchors were used as the main procedure, and temporary clavicle and scapula fixation, as an auxiliary method. According to Tamaoki et al,<sup>23</sup> in a cross-sectional study with Brazilian orthopedic surgeons regarding the treatment of ACD, in surgical cases of grade III, 63% of the respondents use CC fixation in their patients, while 51% prefer the AC transarticular fixation technique.

Clavicle fixation in the scapular spine was performed sparing the ACJ from further aggression and aiming to

avoid complications such as residual pain in the AC. Eskola et al,<sup>24</sup> in a randomized trial about the surgical treatment of ACD comparing CC fixation with screw and AC transarticular metallic wire, showed better results with the use of transarticular metallic wire. However, the technique is associated with a high rate of complications, including infection, loss of reduction, development of AC osteoarthritis, and breakage and migration of the metallic wire. This study shows benefits of the temporary fixation between the clavicle and scapular spine, as it prevents the loosening of the anchor sutures in the first weeks after surgery, enabling a better soft tissue healing and aiding in maintaining dislocation reduction after the removal of the Kirschner wire.

The best treatment method for grade-III injuries is uncertain.<sup>25</sup> Some authors describe similar results regarding the surgical and non-surgical treatments in cases of grade III,<sup>18</sup> while others found unsatisfactory results with the non-surgical treatment, such as residual pain and decreased shoulder muscular strength in up to 50% of cases, favoring the surgical management as a choice in these cases.<sup>26</sup> According to Rasmont et al,<sup>27</sup> conservative treatment is the first choice for these lesions. In the sample studied, the percentage of satisfaction of grade-III patients was of 100%, and in the functional evaluation, the satisfactory results were of 87.5% in the UCLA; of 81.3% in the DASH, and of 81.2% in the Constant-Murley score, considering patients with grade-III ACD. These results demonstrate that this method is a good option for this group of patients, with high satisfaction rates at the end of the follow-up.

Although the literature shows good functional results with the use of metallic anchors in the coracoid as a method of treatment of acute ACD,<sup>15,18,19</sup> different results were found according to the age of the patients. In the sample of the present study, there was a statistically significant difference, with worse functional results in the UCLA ( $p = 0.005$ ), DASH ( $p = 0.006$ ) and Constant-Murley ( $p = 0.002$ ) scores in patients with mean ages of 56.7 (±3.2), 54.0 (±6.7), 53.8 (±6.0) years respectively, suggesting that the treatment of acute ACD by this method in patients of this age group should be reviewed. Additional studies are needed to elucidate the relationship among the unsatisfactory functional outcomes in older patients.

An auxiliary procedure, CA ligament transfer, works, in principle, as an organic reinforcement for AC stabilization. According to Johansen et al,<sup>5</sup> the use of the CA ligament has biomechanical limitations if employed alone in the treatment of AC instability, and it must be used simultaneously with CC ligament reconstructions. However, no statistically significant differences were found regarding the functional results between the groups that performed or not the adjuvant CA ligament transfer.

The observer's description of loss of reduction after surgery or residual subluxations on the radiological examination is frequent. According to the literature, the evidence of recurrent deformity ranges from 8 to 18%.<sup>28-30</sup> In the technique of anchor reconstruction, according to Breslow et al,<sup>31</sup> one of the reasons for the loss of reduction is the inaccurate insertion of the anchors in the coracoid. In the present study, recurrence was observed in 2 patients (6.6%) on the AP radiograph. Carrera et al<sup>15</sup> described 3 cases of relapse in 21 patients evaluated. Some studies show that loss of reduction, with consequent residual subluxation of the ACJ, does not affect the final clinical outcome of the treatment.<sup>4,32,33</sup> Cavinatto et al<sup>4</sup> reported a high rate of loss of initial reduction after arthroscopic CC fixation with anchors, with a satisfactory outcome. Lädermann et al,<sup>34</sup> in a clinical, radiological and isokinetic study with 37 patients undergoing CC cerclage and AC stabilization with non-absorbable sutures for the treatment of ACDs, found loss of reduction in 7 (18.9%) patients, and that was related to the less satisfactory results. In the present sample, we observed that 30% of the patients had the clinical impression of loss of reduction, and 80% of residual subluxations were observed on the AP radiograph, but most patients had satisfactory functional scores.

The standardization of radiographic evaluation criteria for postoperative outcomes is necessary. Figueiredo et al<sup>35</sup> described the loss of AC reduction of 19% on panoramic shoulder radiographs. In the present study, we used the relative measurement of the CCd\_O/N in order to measure in a more reliable manner the loss of reduction and to evaluate the possible relationships between the residual measurement and the unsatisfactory functional results. Although patients with unsatisfactory results in the functional scores presented higher values in the CCd\_O/N, there was no statistical significance ( $p > 0.05$ ). As both incidences (AP and Zanca) presented some correlation with the subluxation results in the value of the dCC\_O/N, the authors recommend any of the incidences for postoperative radiological follow-up.

A positive aspect of the study is the use of 3 scores (UCLA, DASH and Constant-Murley) in the evaluation of functional results, all with satisfactory results in more than 80% of the sample. Another positive aspect is the standardization of the CCd\_O/N as a proposal for postoperative follow-up. Finally, the similarity of the results (clinical, radiological and functional) of the groups (with or without CA ligament transfer), casts doubt over the need for this adjuvant transfer. The main weakness was the sample size, which was too small in order for us to observe a statistical significance between the increase in the CCd\_O/N and worse results in the functional scores.

## Conclusion

The technique of surgical treatment of acute ACD for Rockwood and Williams<sup>3</sup> grades III, IV and V with CC syndesmo-pexy using two metallic anchors and temporary clavicle and scapula fixation provides efficient fixation with excellent results, according to the UCLA, DASH and Constant-Murley scores, despite the high residual radiological subluxation index found. No statistically significant differences were found between the groups that did and did not undergo adjunct CA ligament transfer during surgery. The unsatisfactory results were associated with individuals older than 50 years of age.

## Conflicts of Interest

The authors have none to declare.

## References

- 1 Court-Brown C, Heckman J, McQueen M, Tornetta P III, Ricci W, McKee M, Eds. Rockwood and Green's fractures in adults. 7th ed. Philadelphia: Wolters Kluwer Health; 2010
- 2 Tossy JD, Mead NC, Sigmund HM. Acromioclavicular separations: useful and practical classification for treatment. *Clin Orthop Relat Res* 1963;28(28):111-119
- 3 Rockwood C, Williams G. Disorders of the acromioclavicular joint. In: Rockwood C, Matsen F, editors. 2nd ed. Philadelphia: Saunders; 1998:483-553
- 4 Cavinatto L, Iwashita R, Ferreira Neto A, et al. Arthroscopic treatment of acute acromioclavicular joint dislocation using suture anchors. *Acta Ortop Bras* 2011;19(03):141-144
- 5 Johansen JA, Grutter PW, McFarland EG, Petersen SA. Acromioclavicular joint injuries: indications for treatment and treatment options. *J Shoulder Elbow Surg* 2011;20(2, Suppl):S70-S82
- 6 Dal Molin D, Ribeiro F, Brasil Filho R, et al. Via de acesso cirúrgico posterossuperior para o tratamento das luxações acromioclaviculares: resultados de 84 casos operados. *Rev Bras Ortop* 2012;47(05):563-567
- 7 Flint JH, Wade AM, Giuliani J, Rue JP. Defining the terms acute and chronic in orthopaedic sports injuries: a systematic review. *Am J Sports Med* 2014;42(01):235-241
- 8 Oku E, Andrade A, Stadiniky S, Carrera E, Tellini G. Tradução e Adaptação Cultural do Modified-University of California at Los Angeles Shoulder Rating Scale para a Língua Portuguesa. *Rev Bras Reumatol* 2006;46(04):246-252
- 9 Orfale AG, Araújo PM, Ferraz MB, Natour J. Translation into Brazilian Portuguese, cultural adaptation and evaluation of the reliability of the Disabilities of the Arm, Shoulder and Hand Questionnaire. *Braz J Med Biol Res* 2005;38(02):293-302
- 10 Constant CR, Murley AH. A clinical method of functional assessment of the shoulder. *Clin Orthop Relat Res* 1987;(214):160-164
- 11 Chaitanya P, Naveen P. Clinico-radiological validation of the DASH questionnaire in patients operated for fracture of shaft of humerus -. *Int J Res Med Sci*. 2015;3(01):287-290
- 12 Leite N, Faloppa F. Propedêutica ortopédica e traumatológica. Porto Alegre: Artmed; 2013
- 13 Doneux P, Checchia S, Miyazaki A. Padronização do estudo radiográfico da cintura escapular. *Revista Bras Ortop*. 1998;33(11): 883-888
- 14 Rush LN, Lake N, Stiefel EC, et al. Comparison of Short-term Complications Between 2 Methods of Coracoclavicular Ligament Reconstruction: A Multicenter Study. *Orthop J Sports Med* 2016;4(07):2325967116658419. Doi: 10.1177/2325967116658419
- 15 Carrera E, Pierami R, Sugawara M, Nicolao F, Netto N, Matsumoto M. Evaluation of the surgical treatment of acromioclavicular joint

- dislocation with a new option for temporary fixation of the acromioclavicular joint. *Tech Shoulder Elbow Surg* 2013;14(04):99–103
- 16 Cohen J. A power primer. *Psychol Bull* 1992;112(01):155–159
  - 17 Faul F, Erdfelder E, Lang AG, Buchner A. G\*Power 3: a flexible statistical power analysis program for the social, behavioral, and biomedical sciences. *Behav Res Methods* 2007;39(02):175–191
  - 18 Bâthlis H, Tingart M, Bouillon B, Tiling T. [Conservative or surgical therapy of acromioclavicular joint injury—what is reliable? A systematic analysis of the literature using “evidence-based medicine” criteria]. *Chirurg* 2000;71(09):1082–1089
  - 19 Algarín JR, Salcedo JD, Rodríguez JO, Bello AG, Sancho FB. [Grade III acromioclavicular dislocation treated with a minimally invasive approach]. *Acta Ortop Mex* 2010;24(05):317–323
  - 20 Koukakis A, Manouras A, Apostolou CD, et al. Results using the AO hook plate for dislocations of the acromioclavicular joint. *Expert Rev Med Devices* 2008;5(05):567–572
  - 21 Tiren D, van Bommel AJ, Swank DJ, van der Linden FM. Hook plate fixation of acute displaced lateral clavicle fractures: mid-term results and a brief literature overview. *J Orthop Surg Res* 2012;7:2. Doi: 10.1186/1749-799X-7-2
  - 22 Baker JE, Nicandri GT, Young DC, Owen JR, Wayne JS. A cadaveric study examining acromioclavicular joint congruity after different methods of coracoclavicular loop repair. *J Shoulder Elbow Surg* 2003;12(06):595–598
  - 23 Tamaoki M, Cocco L, Pereira H, et al. Estudo transversal sobre o tratamento das lesões acromioclaviculares agudas. *Acta Ortop Bras* 2009;17(05):300–304
  - 24 Eskola A, Vainionpää S, Korkkala O, Rokkanen P. Acute complete acromioclavicular dislocation. A prospective randomized trial of fixation with smooth or threaded Kirschner wires or cortical screw. *Ann Chir Gynaecol* 1987;76(06):323–326
  - 25 Smith TO, Chester R, Pearse EO, Hing CB. Operative versus non-operative management following Rockwood grade III acromioclavicular separation: a meta-analysis of the current evidence base. *J Orthop Traumatol* 2011;12(01):19–27
  - 26 Leidel BA, Braunstein V, Kirchoff C, Pilotto S, Mutschler W, Biberthaler P. Consistency of long-term outcome of acute Rockwood grade III acromioclavicular joint separations after K-wire transfixation. *J Trauma* 2009;66(06):1666–1671
  - 27 Rasmont Q, Delloye C, Bigare E, Van Isacker T. Is conservative treatment still defensible in grade III acromioclavicular dislocation? Are there predictive factors of poor outcome?. *Acta Orthop Belg* 2015;81(01):107–114
  - 28 Guy DK, Wirth MA, Griffin JL, Rockwood CA Jr. Reconstruction of chronic and complete dislocations of the acromioclavicular joint. *Clin Orthop Relat Res* 1998;(347):138–149
  - 29 Weaver JK, Dunn HK. Treatment of acromioclavicular injuries, especially complete acromioclavicular separation. *J Bone Joint Surg Am* 1972;54(06):1187–1194
  - 30 Pavlik A, Csépai D, Hidas P. Surgical treatment of chronic acromioclavicular joint dislocation by modified Weaver-Dunn procedure. *Knee Surg Sports Traumatol Arthrosc* 2001;9(05):307–312
  - 31 Breslow MJ, Jazrawi LM, Bernstein AD, Kummer FJ, Rokito AS. Treatment of acromioclavicular joint separation: suture or suture anchors? *J Shoulder Elbow Surg* 2002;11(03):225–229
  - 32 Fraser-Moodie JA, Shortt NL, Robinson CM. Injuries to the acromioclavicular joint. *J Bone Joint Surg Br* 2008;90(06):697–707
  - 33 Simovitch R, Sanders B, Ozbaydar M, Lavery K, Warner JJ. Acromioclavicular joint injuries: diagnosis and management. *J Am Acad Orthop Surg* 2009;17(04):207–219
  - 34 Lädermann A, Grosclaude M, Lübbecke A, et al. Acromioclavicular and coracoclavicular cerclage reconstruction for acute acromioclavicular joint dislocations. *J Shoulder Elbow Surg* 2011;20(03):401–408
  - 35 Figueiredo E, Terra B, Marczyk C, et al. Avaliação do tratamento cirúrgico da luxação acromioclavicular grau III pela técnica de Weaver-Dunn modificada associada ao amarrilho coracoclavicular em atletas [acesso em 2018 jan. 25]. *RBM Rev Bras Med*. 2011;68(3, n.esp). Disponível em: [http://www.moreirajr.com.br/revistas.asp?fase=r003&id\\_materia=4595](http://www.moreirajr.com.br/revistas.asp?fase=r003&id_materia=4595)