

# Pulmonary Thrombosis: A Clinical Pathological Entity Distinct from Pulmonary Embolism?

Francesco Marongiu, MD<sup>1</sup> Antonella Mameli, MD<sup>1</sup> Elvira Grandone, MD<sup>2,3</sup> Doris Barcellona, MD<sup>1</sup>

<sup>1</sup>Department of Medical Science and Public Health, University of Cagliari, Cagliari, Italy

<sup>2</sup>Atherosclerosis and Thrombosis Unit, IRCCS Ospedale Casa Sollievo della Sofferenza, Foggia, Italy

<sup>3</sup>Department of Obstetrics and Gynecology, First Moscow State Medical University, Moscow, Russia

Address for correspondence Francesco Marongiu, MD, Department of Medical Science and Public Health, Cittadella Universitaria, University of Cagliari, Monserrato 09042, Cagliari, Italy (e-mail: francescomarongiu@me.com).

Semin Thromb Hemost 2019;45:778–783.

## Abstract

Since Virchow's autopsy studies in the mid-1800s, it has generally been believed that pulmonary embolism (PE) originated from the embolization of fibrin fragments from a deep venous thrombosis (DVT). However, a DVT is often not found in patients with PE (up to 50% of cases). Could fibrin form in the pulmonary vessels without coming from the periphery? In this review, the authors will try to support the hypothesis that a pulmonary thrombosis (PT) may develop. They will do so through different clinical models related to some pathological conditions such as pneumonia, chronic obstructive pulmonary disease (COPD), and asthma, all of which show a close relationship between local inflammation and activation of blood coagulation, two defensive systems that may lead to fibrin deposition in the lungs, thus recognizing the possibility that PT may be a newly recognized entity. An increased risk for PE has been demonstrated in these conditions. Sickle cell disease and assisted reproductive technologies are other very different conditions in which an increased risk for PE has been found. Gaucher's disease is a rare hereditary condition in which the hemostatic system could have a role in the pathogenesis of pulmonary hypertension, which complicates the course of the disease. In particular, the increased risk for PT, common to all these conditions, deserves attention when a patient presents with sudden dyspnea, an unexpected COPD exacerbation, or severe sudden asthmatic dyspnea. As a consequence, prediction scores for venous thromboembolism could be revised.

## Keywords

- ▶ pulmonary embolism
- ▶ pulmonary thrombosis
- ▶ pneumonia
- ▶ chronic obstructive pulmonary disease
- ▶ asthma
- ▶ sickle cell disease
- ▶ Gaucher's disease

## Introduction

Since Virchow's autopsy studies in the mid-1800s, it has generally been believed that pulmonary embolism (PE) originated from the embolization of fibrin fragments from a deep venous thrombosis (DVT). However, a DVT is often not found in patients with PE (up to 50% of cases).<sup>1,2</sup> Why is the discussion always around "pulmonary embolism" and never "pulmonary thrombosis" (PT)? Could fibrin form in the pulmonary vessels without coming from the periphery? If it is true that a fragment of fibrin, that is, an embolus, originating from a DVT can travel to one or more pulmonary

vessels, then it could also be true that fibrin is deposited locally. In this review, we will try to support the hypothesis that a PT may develop. We will do this through different models related to some pathological conditions.

## Pneumonia

In the Multiple Environmental and Genetic Assessment (MEGA) study,<sup>3</sup> a population-based case-control study, a total of 4,281 patients who suffered from PE and/or DVT and 5,665 controls were recruited. Patients and control subjects reported a history of pneumonia in the year before

published online  
September 19, 2019

Issue Theme Recent Advances in  
Thrombosis and Hemostasis—Part V;  
Guest Editor: Sam Schulman, MD, PhD.

Copyright © 2019 by Thieme Medical  
Publishers, Inc., 333 Seventh Avenue,  
New York, NY 10001, USA.  
Tel: +1(212) 584-4662.

DOI <https://doi.org/10.1055/s-0039-1696942>.  
ISSN 0094-6176.

the thrombotic event in 307 and 87 cases, respectively. The risk for PE alone was 8.1 (95% confidence interval [CI]: 6.2–10.6), whereas that of DVT alone was 3 (95% CI: 2.2–4.0). However, pneumonia was self-reported, and the exact temporal relationship between pneumonia and the venous thromboembolism (VTE) event was impossible to establish. The only data available were from the year before the VTE episodes. Despite these limitations, this study clearly states that the risk for diagnosis of PE is increased in patients who suffered from pneumonia in comparison with that of DVT only because there must be a detection bias. Interestingly, patients with factor V Leiden and pneumonia had a high overall risk for VTE (odds ratio [OR]: 17.8; 95% CI: 5.5–57.7), not so different from that found in patients who were carriers of the prothrombin mutation G20210A (OR: 20.7; 95% CI: 2.7–155.9), even though the number of patients and controls with these characteristics was very small as the wide width of CI reveals. The interpretation of these data goes toward the fact that inflammation produces cytokines, which, in turn, can activate blood coagulation.<sup>4</sup> In particular, interleukin 6 and tumor necrosis factor can elicit the activation of blood coagulation through tissue factor, which is the trigger of the coagulation cascade.<sup>5</sup> Moreover, these cytokines decrease the fibrinolytic potential by inhibiting plasminogen activators thus producing a local hypercoagulable state.<sup>6</sup> It is worth noting that both a bacterial infection and a viral infection may have a role in this pathway. It has been demonstrated that both *Klebsiella pneumoniae* and *Streptococcus pneumoniae* can induce local activation of coagulation and fibrin deposition in the lungs.<sup>7</sup> On the other hand, it is also known that thrombin inhibits the growth of *Klebsiella pneumoniae* cooperating with neutrophils and platelets.<sup>8</sup> Therefore, the role of blood coagulation is essential in the host defensive system, further emphasizing the extensive and close cross-talk between coagulation and inflammation. The origin of both coagulation and immune system is ancestral since during infections, the activation of blood coagulation assists in counteracting bacterial and virus infections in close cooperation with the immune system. The two systems, blood coagulation and immune, can therefore limit bacteria and virus dissemination by forming a fibrin network able to kill pathogens and inducing tissue repair. However, an excessive blood coagulation response is dangerous since it can lead to local thrombosis in the lungs.<sup>9</sup>

## Chronic Obstructive Pulmonary Disease

Inflammation in chronic obstructive pulmonary disease (COPD) plays a pivotal role in both airflow limitation and exacerbation not limited to the lungs but potentially having a systemic impact.<sup>10</sup> In the exacerbation of COPD, neutrophil/lymphocyte ratio index has been strongly associated with the exacerbation, thus further confirming a pathophysiological role of these cells as a marker of disease activity.<sup>11</sup> These findings underline and remind that neutrophils are involved in the course of the disease, especially during an exacerbation. Neutrophils are part of the innate immune system in that their mission is to kill bacteria by

engulfing or by delivering histones, proteolytic enzymes, and DNA, thus producing neutrophil extracellular traps (NETs).<sup>12</sup> Even, if on one hand NETs are essential as an ancestral defensive system, they may, on the other hand, induce damage to the lungs when the response to the pathogens is too intense, including microcirculation disturbance, degradation and death of the endothelial cells, and obstruction of the airways with consequent impairment of lung function.<sup>13</sup> In particular, NETs can activate blood coagulation and platelets.<sup>14</sup> The negatively charged surface of NETs can activate factor XII, that is, the intrinsic pathway of coagulation, whereas the tissue factor in NETs promotes a complex with factor VII, thus activating the extrinsic pathway of coagulation. Moreover, histones activate platelets through cooperation with von Willebrand factor on one hand, and inhibiting thrombomodulin on the other, thus favoring thrombosis. All these pathophysiological mechanisms can explain, at least in part, the findings of Schneider et al in their nested case-control study<sup>15</sup> involving 35,772 patients with a first-time COPD diagnosis and the same number of controls without COPD. In their study, the OR for PE was significantly increased among those with COPD (2.51; 95% CI: 1.62–3.87), whereas that for DVT was not significant. Interestingly, the OR for PE increased with the severity of COPD (up to OR: 7.47; 95% CI: 2.35–23.7 in severe COPD). These findings confirm other reports on the association of PE during exacerbation of COPD. In a French study, the prevalence of symptomatic PE was found to be 25% in patients with unexplained exacerbation of the disease,<sup>16</sup> whereas Sidney et al<sup>17</sup> reported a 2.74-fold (95% CI: 1.99–3.76) increased relative risk of hospitalization due to PE among COPD patients in comparison to controls.

## Asthma

Asthma is a disease characterized by bronchial hyperresponsiveness and chronic airway inflammation with consequent signs of acute airflow obstruction. The main clinical features of the disease are dyspnea and coughing in a context of allergic inflammation driven by mast cells, eosinophils, and type 2 T helper lymphocytes in the bronchial walls and mucus hypersecretion.<sup>18</sup> As per other chronic inflammatory diseases such as inflammatory bowel disease, rheumatoid arthritis, diabetes mellitus, and COPD, a hypercoagulable state and reduced fibrinolytic activity have been found in asthma, in particular in airways. A leak of clotting factors from the vasculature together with the expression of tissue factor by alveolar epithelium, macrophages, and eosinophils can activate coagulation cascade. The inhibition of fibrinolysis by an enhanced production of PAI-1 (plasminogen activator inhibitor-1) further strengthens fibrin deposition. Vascular inflammation has been shown in asthma and COPD,<sup>19</sup> thus suggesting that a cross-talk between airways and the vascular component is a realistic phenomenon. To answer the question of whether this hypercoagulable state in asthma could be translated into an increased risk for VTE, Majoor et al<sup>20</sup> investigated the incidence of DVT and PE in patients with severe and mild-to-moderate asthma. They studied 283 patients with severe asthma and 365 with mild-to-moderate disease. All venous thromboembolic events

reported by the patients were objectively confirmed. The incidence of PE in patients with severe asthma was 0.93 (95% CI: 0.42–1.44) per 1,000 person-years, whereas that of mild-to-moderate asthma was 0.33 (95% CI: 0.07–0.60). The incidence of PE in the general population was 0.18 (95% CI: 0.03–0.33) per 1,000 person-years. The hazard ratio for PE was higher in patients with severe asthma treated with corticosteroid (3.33; 95% CI: 1.16–9.93) in comparison with those with a mild-moderate disease (2.82; 95% CI: 1.09–7.30). Asthma was not associated with DVT. The authors interpreted the results of their study, indicating the local inflammatory condition as the main cause of the increased incidence of PE in asthma. In 2017, a case–control study from Sweden<sup>21</sup> used nationwide registries to identify a large number of patients with PE (114,366), DVT (76,494), or both PE and DVT (6,854). All these patients had a first diagnosis of VTE between 1981 and 2010. The ORs for PE (1.43), DVT (1.56), and combined PE and DVT (1.60) were quite similar, leading the authors to conclude that the inflammation seems to have both systemic and local prothrombotic roles in asthma. This study did not confirm the findings of Majoor et al,<sup>20</sup> but it has the important limitation that it was based only on administrative data coming from hospitalized patients. Furthermore, a distinction between severe and mild-to-moderate asthma was not made. This could therefore have decreased the OR estimates among the different categories of patients.

### Sickle Cell Disease

The sickling phenomenon in sickle cell disease (SCD), a severe condition characterized by the homozygous genotype of the allele HbS, induces an exposition of phosphatidylethanolamine and phosphatidylserine (PS) on the exterior of the red blood cells' membrane. PS has, in turn, a procoagulant activity since it offers a surface for the binding of coagulative factors.<sup>22,23</sup> Both a shortened clotting time and an increase of some markers of activation of blood coagulation (F 1 + 2 peptide, D-dimer and thrombin–antithrombin complexes) have been found in asymptomatic patients with sickle cell trait (SCT), that is, the heterozygous form of the disease.<sup>24</sup> Moreover, a significant association was found between PS-positive erythrocytes, and F 1 + 2 peptide, D-dimer, and plasmin-antiplasmin complexes, indicating the pivotal role of the abnormal erythrocytes in determining a hypercoagulable state with secondary fibrinolysis activation.<sup>25</sup> A cross-sectional study was performed in the United States using the National Hospital Discharge Survey database, which includes hospital data.<sup>26</sup> Patients aged < 40 years with SCD had more often a diagnosis of PE (0.44%) in comparison with African-Americans aged < 40 years without SCD (0.12%), but the prevalence of DVT was similar between patients with SCD (0.44%) and African-Americans without SCD (0.40%). In a case–control study with 515 hospitalized black patients and 555 black controls,<sup>27</sup> there was a 3.9-fold (95% CI: 2.2–6.9) increased risk of PE for SCT patients but not for DVT (1.1; 95% CI: 0.65–1.9). A recent systematic review<sup>28</sup> included 41 studies that supported a positive association between SCT and risk for PE but no association between SCT and DVT.

Another more recent systematic review<sup>29</sup> found that SCD patients had a significantly higher risk for VTE (pooled OR: 4.4; 95% CI: 2.6–7.5), DVT (OR: 1.1; 95% CI: 1.1–1.2), and PE (OR: 3.7; 95% CI: 3.6–3.8) as compared with controls. Compared with adults without SCT, SCT was associated with a higher risk of PE (pooled OR: 2.1; 95% CI: 1.2–3.8,  $p = 0.012$ ) but not of DVT (pooled OR: 1.2; 95% CI: 0.9–1.7).

### Gaucher's Disease

Gaucher's disease (GD) is a sphingolipidosis and was first described by Philippe Gaucher in 1882. GD (types 1–3) is a rare, autosomal, recessive genetic disease induced by mutations in the *GBA1* gene. The consequence is a decreased activity of the lysosomal enzyme glucocerebrosidase, which normally hydrolyzes glucosylceramide (GlcCer) into ceramide and glucose. GlcCer accumulates in macrophages, becoming Gaucher cells, which infiltrate the bone marrow, spleen, and liver.<sup>30</sup> However, lung involvement may be found at presentation with secondary pulmonary hypertension.<sup>31</sup> High-resolution computed tomography (HRCT) can show diffuse ground-glass opacification,<sup>32</sup> which indicates interstitial thickening or partial collapse of lung alveoli.<sup>33</sup> With the aim to correlate bone necrosis and pulmonary hypertension with the presence of a marker of fibrin dissolution, hypothesizing that these features of the disease could be related to microthrombosis, Sherif et al<sup>34</sup> measured D-dimer in a group of patients with GD (types 1 and 3). They found that D-dimer levels were significantly higher in all patients with GD in comparison with controls ( $p < 0.001$ ). In particular, patients with type 3 GD showed significantly higher D-dimer concentrations than those with type 1 ( $p < 0.001$ ). Pulmonary involvement was present in a significant proportion among type 3 GD patients ( $p < 0.05$ ), D-dimers were significantly higher in patients found to present with “ground glass” abnormalities on HRCT when compared with patients with normal radiological findings ( $p < 0.001$ ). The authors concluded that microthrombi may have a role in the pathogenesis of pulmonary hypertension in patients with GD, confirming what Shitrit et al had reported in a previous study<sup>35</sup> involving 118 patients with GD. In that study, a significant correlation was found between D-dimer, avascular necrosis, splenectomy, and pulmonary hypertension assessed by echocardiography if the tricuspid incompetence gradient was greater than 30 mm/Hg. The interpretation of these findings was again in favor of the role of microthrombi in the pathogenesis of the disease. How do we explain all these findings? We can hypothesize that Gaucher cells, that is, transformed macrophages, could induce continuous activation of blood coagulation by exposure of tissue factor on their membrane with secondary fibrinolysis. It is difficult not to consider a reactive response by cells that belong to the immune and scavenger systems devoted to eliminating sphingolipid accumulation, neoplastic cells, and bacteria.

### Assisted Reproductive Technologies

Venous thromboembolism may occur during or after assisted reproductive technologies (ARTs).<sup>36</sup> Recently, Grandone et al

reported data from the Registro Informatizado de Enfermedad TromboEmbolica (RIETE) registry up to October 2016.<sup>37</sup> A total of 41 (0.6%) out of 6,718 women with VTE suffered from an ART-related event. VTE was recorded in 20 successful and 21 unsuccessful ART cycles. Interestingly, multiple logistic regression revealed that isolated PE was significantly more frequent than DVT alone or with concomitant PE in unsuccessful IVF (in vitro fertilization) (OR: 4.13; 95% CI: 1.4–12.4), as well as contraceptive users (OR: 2.96; 95% CI: 1.95–4.5) and puerperium (OR: 1.96; 95% CI: 1.16–3.3). To explain these findings, the authors proposed the hypotheses that an inflammatory condition together with an increased fibrinogen concentration could be the basis predisposing to fibrin deposition in the lung circulation.

## Discussion

Taken together, the data reported earlier are in favor of the possibility that a PT could occur. In other words, two phenomena, DVT and PE, do not necessarily coincide, that is, they may not be the same disease in that they recognize different pathophysiology at least in some pathological conditions. A recent report of ours highlighted that the presence of DVT is paradoxically a protective factor against PE mortality.<sup>38</sup> In 2011, van Langevelde et al found that COPD, pneumonia, and SCD showed a higher risk of PE, without any impact on DVT.<sup>39</sup> These findings further suggest that PE and DVT may not always have the same etiology. On the other hand, patients with pneumonia or any respiratory disease may have dyspnea, pleuritic pain, and hemoptysis from those diseases. Thus, there could be a greater chance that they undergo a CT of the chest and a symptomatic or asymptomatic PE will be identified. Patients with just DVT may not be sent for a CT since a finding of an asymptomatic PE would not change the management. Compression ultrasound (CUS) has a very high sensitivity and specificity for the diagnosis of proximal DVT but is much less sensitive with regard to distal DVTs.<sup>40</sup> Stern et al detected an abdominal or pelvic thrombosis by magnetic resonance imaging (MRI), otherwise not detected by CUS, in 29% of patients with acute PE.<sup>41</sup> A method that is certainly more effective is that which uses an extension of the CT pulmonary angiography to the abdominal vessels and those of the lower limbs. In this way, it is possible to highlight around 10% of thrombosis above the inguinal ligament, but certainly this does not reach the percentage of around 50% of cases in which a DVT is not found in patients who have suffered from PE. However, this method is rarely used because CT requires radiographic contrast and is associated with high radiation exposure.<sup>42</sup> In 2013, van Langevelde et al<sup>43</sup> showed that DVT was not present in more than 50% of patients with PE confirmed by CT pulmonary angiography. This result was obtained using a total body magnetic resonance direct thrombus imaging (MRDTI) scan, which is a noninvasive technique that does not require gadolinium contrast and has a sensitivity of 98% and a specificity of 96%, quite similar to those of ultrasonography or venography in patients with DVT.<sup>44</sup> This method is able to show the thrombus since it is based on the transformation of hemo-

globin to methemoglobin, which gives a strong signal using a T1 sequence. The authors considered several options to explain their findings, such as a cardiac thrombus origin and embolization of the whole deep vein thrombus. However, in their case series, no patient had cardiac failure and only two people suffered from atrial fibrillation. A complete detachment of the whole thrombus at the time of scanning was not considered as a reliable option because it is not supported by autopsy studies, which showed that in 40% of PE cases a DVT was not found.<sup>45</sup> Again, the authors challenged the hypothesis of a local PT by logistic regression analysis, which showed no association between detection of a DVT and the number of days between diagnosis and MRDTI. The authors did so because they thought that a longer time between the diagnosis of PE and MRDTI scanning could be related to a lower chance to find a thrombus following the theory which states that a thrombus had been present but was completely dislodged to the pulmonary arteries at the time of scanning. Results of the logistic regression induced them to conclude that a local PT needed to be considered.

## Conclusion

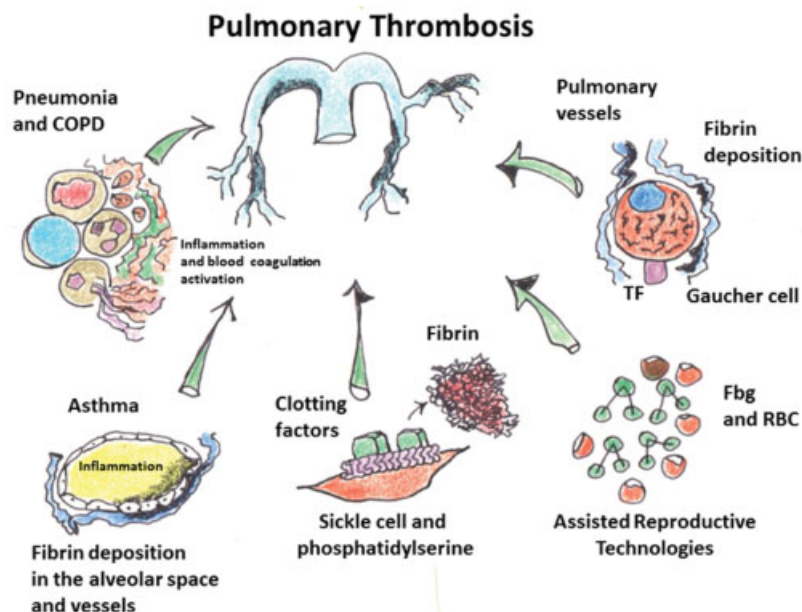
Inflammation and its combined role with that of innate immune and blood coagulation may well explain why the pulmonary vascular bed may be the site of fibrin deposition. Diseases such as those reported earlier, which recognize this pathophysiology, increase the risk of VTE and, in particular, of PT. This aspect, rarely considered in the literature, may have practical consequences since a patient with pneumonia, unexpected COPD exacerbation, or severe sudden asthmatic dyspnea should be considered with great attention: a diagnosis of PT could be missed. At the same time, these patients might not reach a sufficiently high prediction score for VTE<sup>46</sup> to start antithrombotic prophylaxis, but which would be of value in case of additional risk factors (being bedridden, obesity, hormone therapy, etc.). Prediction scores for VTE should therefore be revised. We believe that the same concept should be applied also to patients with rare diseases such as SCD or undergoing ART. Finally, GD may be a condition in which a dual source or single-proton emission CT could give important information on the lung perfusion,<sup>47</sup> with the aim of confirming or not the role of microthrombi in

**Table 1** Take home messages from this review

<p>Innate immune and blood coagulation activation could explain why thrombosis may occur in the lungs. Inflammation plays a central role. A diagnosis of pulmonary thrombosis could be missed in inflammatory pulmonary pathological conditions since a sufficiently high prediction score for VTE could not be reached. The same concept should be also applied to patients with rare diseases such as sickle cell disease or undergoing to assisted reproductive technologies. Future research could be important in Gaucher's disease, possibly discovering a role for an antithrombotic treatment.</p>
--

Abbreviation: VTE, venous thromboembolism.





**Fig. 1** Possible pathophysiological mechanisms underlying pulmonary thrombosis. These are in reference to the conditions detailed in the text. COPD, chronic obstructive pulmonary disease; Fbg, fibrinogen; RBC, red blood cells; TF, tissue factor.

the pathogenesis of pulmonary hypertension, perhaps opening a road toward antithrombotic treatment in addition to enzyme replacement therapy.

The key messages from this review are provided in ►Table 1, and ►Fig. 1 provides a schematic representation of the possible pathophysiological mechanisms underlying PT, with reference to the conditions detailed in the main text.

#### Conflict of Interest

None.

#### Acknowledgments

This review is dedicated to Prof. Mario Morpurgo, an Italian pneumologist, who devotes his life to the study of pulmonary embolism.

#### References

- Jiménez D, Aujesky D, Díaz G, et al; RIETE Investigators. Prognostic significance of deep vein thrombosis in patients presenting with acute symptomatic pulmonary embolism. *Am J Respir Crit Care Med* 2010;181(09):983–991
- Yamaki T, Nozaki M, Sakurai H, Takeuchi M, Soejima K, Kono T. Presence of lower limb deep vein thrombosis and prognosis in patients with symptomatic pulmonary embolism: preliminary report. *Eur J Vasc Endovasc Surg* 2009;37(02):225–231
- Ribeiro DD, Lijfering WM, Van Hylckama Vlieg A, Rosendaal FR, Cannegieter SC. Pneumonia and risk of venous thrombosis: results from the MEGA study. *J Thromb Haemost* 2012;10(06):1179–1182
- Hess R, Wujak L, Hesse C, et al. Coagulation factor XII regulates inflammatory responses in human lungs. *Thromb Haemost* 2017;117(10):1896–1907
- Levi M, Schultz MJ, Rijneveld AW, van der Poll T. Bronchoalveolar coagulation and fibrinolysis in endotoxemia and pneumonia. *Crit Care Med* 2003;31(4, Suppl):S238–S242
- Schultz MJ, Haitsma JJ, Zhang H, Slutsky AS. Pulmonary coagulopathy as a new target in therapeutic studies of acute lung injury or pneumonia—a review. *Crit Care Med* 2006;34(03):871–877
- Stroo I, Ding C, Novak A, et al. Inhibition of the extrinsic or intrinsic coagulation pathway during pneumonia-derived sepsis. *Am J Physiol Lung Cell Mol Physiol* 2018;315(05):L799–L809
- Claushuis TA, de Stoppelaar SF, Stroo I, et al. Thrombin contributes to protective immunity in pneumonia-derived sepsis via fibrin polymerization and platelet-neutrophil interactions. *J Thromb Haemost* 2017;15(04):744–757
- Antoniak S. The coagulation system in host defense. *Res Pract Thromb Haemost* 2018;2(03):549–557
- Wedzicha JA, Donaldson GC. Exacerbations of chronic obstructive pulmonary disease. *Respir Care* 2003;48(12):1204–1213, discussion 1213–1215
- Paliogiannis P, Fois AG, Sotgia S, et al. Neutrophil to lymphocyte ratio and clinical outcomes in COPD: recent evidence and future perspectives. *Eur Respir Rev* 2018;27(147):170113
- Brinkmann V, Reichard U, Goosmann C, et al. Neutrophil extracellular traps kill bacteria. *Science* 2004;303(5663):1532–1535
- Porto BN, Stein RT. Neutrophil extracellular traps in pulmonary diseases: too much of a good thing? *Front Immunol* 2016;7:311
- Kapoor S, Opneja A, Nayak L. The role of neutrophils in thrombosis. *Thromb Res* 2018;170:87–96
- Schneider C, Bothner U, Jick SS, Meier CR. Chronic obstructive pulmonary disease and the risk of cardiovascular diseases. *Eur J Epidemiol* 2010;25(04):253–260
- Tillie-Leblond I, Marquette CH, Perez T, et al. Pulmonary embolism in patients with unexplained exacerbation of chronic obstructive pulmonary disease: prevalence and risk factors. *Ann Intern Med* 2006;144(06):390–396
- Sidney S, Sorel M, Quesenberry CP Jr, DeLuise C, Lanes S, Eisner MD. COPD and incident cardiovascular disease hospitalizations and mortality: Kaiser Permanente Medical Care Program. *Chest* 2005;128(04):2068–2075
- Papi A, Brightling C, Pedersen SE, Reddel HK. Asthma. *Lancet* 2018;391(10122):783–800
- Wanner A, Mendes ES. Airway endothelial dysfunction in asthma and chronic obstructive pulmonary disease: a challenge for future research. *Am J Respir Crit Care Med* 2010;182(11):1344–1351
- Majoer CJ, Kamphuisen PW, Zwinderman AH, et al. Risk of deep vein thrombosis and pulmonary embolism in asthma. *Eur Respir J* 2013;42(03):655–661

- 21 Zöller B, Pirouzifard M, Memon AA, Sundquist J, Sundquist K. Risk of pulmonary embolism and deep venous thrombosis in patients with asthma: a nationwide case-control study from Sweden. *Eur Respir J* 2017;49(02):1601014
- 22 Franck PFH, Bevers EM, Lubin BH, et al. Uncoupling of the membrane skeleton from the lipid bilayer. The cause of accelerated phospholipid flip-flop leading to an enhanced procoagulant activity of sickled cells. *J Clin Invest* 1985;75(01):183–190
- 23 Chiu D, Lubin B, Roelofsen B, van Deenen LL. Sickled erythrocytes accelerate clotting in vitro: an effect of abnormal membrane lipid asymmetry. *Blood* 1981;58(02):398–401
- 24 Westerman MP, Green D, Gilman-Sachs A, et al. Coagulation changes in individuals with sickle cell trait. *Am J Hematol* 2002;69(02):89–94
- 25 Setty BN, Rao AK, Stuart MJ. Thrombophilia in sickle cell disease: the red cell connection. *Blood* 2001;98(12):3228–3233
- 26 Stein PD, Beemath A, Meyers FA, Skaf E, Olson RE. Deep venous thrombosis and pulmonary embolism in hospitalized patients with sickle cell disease. *Am J Med* 2006;119(10):897.e7–897.e11
- 27 Austin H, Key NS, Benson JM, et al. Sickle cell trait and the risk of venous thromboembolism among blacks. *Blood* 2007;110(03):908–912
- 28 Naik RP, Smith-Whitley K, Hassell KL, et al. Clinical outcomes associated with sickle cell trait: a systematic review. *Ann Intern Med* 2018;169(09):619–627
- 29 Noubiap JJ, Temgoua MN, Tankeu R, Tochie JN, Wonkam A, Bigna JJ. Sickle cell disease, sickle trait and the risk for venous thromboembolism: a systematic review and meta-analysis. *Thromb J* 2018;16:27
- 30 Stirnemann J, Belmatoug N, Camou F, et al. A review of Gaucher disease pathophysiology, clinical presentation and treatments. *Int J Mol Sci* 2017;18(02):E441
- 31 Jmoudiak M, Futerman AH. Gaucher disease: pathological mechanisms and modern management. *Br J Haematol* 2005;129(02):178–188
- 32 Lee S, Mark A, Huen K, et al. Gaucher disease with pulmonary involvement in a 6 years old girl: report of resolution of radiographic abnormalities on increasing dose of imiglucerase. *J Pediatr* 2001;139:862–864
- 33 Engeler CE, Tashjian JH, Trenkner SW, Walsh JW. Ground-glass opacity of the lung parenchyma: a guide to analysis with high-resolution CT. *AJR Am J Roentgenol* 1993;160(02):249–251
- 34 Sherif EM, Tantawy AA, Adly AA, Kader HA, Ismail EA. D-dimer assay in Egyptian patients with Gaucher disease: correlation with bone and lung involvement. *Blood Coagul Fibrinolysis* 2011;22(03):176–184
- 35 Shitrit D, Rudensky B, Zimran A, Elstein D. D-dimer assay in Gaucher disease: correlation with severity of bone and lung involvement. *Am J Hematol* 2003;73(04):236–239
- 36 Chan WS, Dixon ME. The “ART” of thromboembolism: a review of assisted reproductive technology and thromboembolic complications. *Thromb Res* 2008;121(06):713–726
- 37 Grandone E, Di Micco PP, Villani M, et al; RIETE Investigators. Venous thromboembolism in women undergoing assisted reproductive technologies: data from the RIETE Registry. *Thromb Haemost* 2018;118(11):1962–1968
- 38 Marni A, Palmas MA, Antonelli A, Contu P, Prandoni P, Marongiu F. A retrospective cohort study of patients with pulmonary embolism: the impact of comorbidities on patient’s outcome. *Eur Respir J* 2016;48(02):555–557
- 39 van Langevelde K, Flinterman LE, van Hylckama Vlieg A, Rosendaal FR, Cannegieter SC. Broadening the factor V Leiden paradox: pulmonary embolism and deep-vein thrombosis as 2 sides of the spectrum. *Blood* 2012;120(05):933–946
- 40 Lensing AW, Doris CI, McGrath FP, et al. A comparison of compression ultrasound with color Doppler ultrasound for the diagnosis of symptomless postoperative deep vein thrombosis. *Arch Intern Med* 1997;157(07):765–768
- 41 Stern JB, Abehsera M, Grenet D, et al. Detection of pelvic vein thrombosis by magnetic resonance angiography in patients with acute pulmonary embolism and normal lower limb compression ultrasonography. *Chest* 2002;122(01):115–121
- 42 Kearon C. Diagnosis of suspected venous thromboembolism. *Hematology (Am Soc Hematol Educ Program)* 2016;2016(01):397–403
- 43 van Langevelde K, Srámek A, Vincken PW, van Rooden JK, Rosendaal FR, Cannegieter SC. Finding the origin of pulmonary emboli with a total-body magnetic resonance direct thrombus imaging technique. *Haematologica* 2013;98(02):309–315
- 44 Kelly J, Hunt BJ, Moody A. Magnetic resonance direct thrombus imaging: a novel technique for imaging venous thromboemboli. *Thromb Haemost* 2003;89(05):773–782
- 45 Lindblad B, Sternby NH, Bergqvist D. Incidence of venous thromboembolism verified by necropsy over 30 years. *BMJ* 1991;302(6778):709–711
- 46 Gerotziafas GT, Papageorgiou L, Salta S, Nikolopoulou K, Elalamy I. Updated clinical models for VTE prediction in hospitalized medical patients. *Thromb Res* 2018;164(Suppl 1):S62–S69
- 47 Nakazawa T, Watanabe Y, Hori Y, et al. Lung perfused blood volume images with dual-energy computed tomography for chronic thromboembolic pulmonary hypertension: correlation to scintigraphy with single-photon emission computed tomography. *J Comput Assist Tomogr* 2011;35(05):590–595