Distal Metaphyseal Osteotomy Allows for Greater Ulnar Shortening Compared to Diaphyseal Osteotomy for Ulnar Impaction Syndrome: A Biomechanical Study

T. David Luo, MD[1] Michael De Gregorio, PhD[1] Andrey Zuskov, MD[1] Mario Khalil, BS[1]
Zhongyu Li, MD, PhD[1] Fiesky A. Nuñez Sr, MD[1] Fiesky A. Nuñez Jr, MD, PhD[1,2]

[1] Department of Orthopaedic Surgery, Wake Forest Baptist Medical Center, Winston Salem, North Carolina
[2] Bon Secours Orthopaedic, Greenville, South Carolina

Address for correspondence T. David Luo, MD, Department of Orthopaedic Surgery, Wake Forest Baptist Medical Center, Medical Center Boulevard, Winston-Salem, NC 27157 (e-mail: tluo@wakehealth.edu).

J Wrist Surg 2020;9:100–104.

Abstract

Purpose To compare the biomechanical characteristics between diaphyseal and metaphyseal ulnar-shortening osteotomy with respect to (1) maximal shortening achieved at each osteotomy site and (2) force required to achieve shortening at each site.

Methods Nine fresh frozen cadaveric upper extremities were affixed through the proximal ulna to a wooden surgical board. A metaphyseal 20-mm bone wedge was resected from the distal ulna and sequential shortening was performed. A load cell was attached to a distal post that was clamped to the surgical board and used to measure the force required for each sequential 5-mm of shortening until maximal shortening was achieved. The resected bone was reinserted, and plate fixation was used to restore normal anatomy. A 20-mm diaphyseal osteotomy was performed, and force measurements were recorded in the same manner with (1) interosseous membrane intact, (2) central band released, and (3) extensive interosseous membrane and muscular attachments released.

Results Metaphyseal osteotomy allowed greater maximal shortening than diaphyseal osteotomy with the interosseous membrane intact and with central band release but similar shortening when extensive interosseous membrane and muscle release was performed. Force at maximal shortening was similar between metaphyseal and diaphyseal osteotomy. Sequential soft tissue release at the diaphysis allowed for increased shortening with slightly decreased shortening force with sequential release.

Conclusion Metaphyseal ulnar osteotomy allows greater maximal shortening but requires similar force compared with diaphyseal osteotomy. Sequential release of the interosseous membrane permits increased shortening at the diaphysis but requires extensive soft tissue release.

Clinical Relevance Both sites of osteotomy can achieve sufficient shortening to decompress the ulnocarpal joint for most cases of ulnar impaction syndrome. The greater shortening from metaphyseal ulnar osteotomy may be reserved for severe cases of shortening, especially after distal radius malunion or in the setting of distal radius growth arrest in the pediatric population.

Level of Evidence This is a Level V, basic science study.

Keywords
- cadaver
- diaphyseal osteotomy
- metaphyseal osteotomy
- ulnar impaction syndrome
- ulnar-shortening osteotomy

received
March 30, 2019
accepted
July 15, 2019
published online
August 28, 2019

DOI https://doi.org/10.1055/s-0039-1695707.
ISSN 2163-3916.

Ulnar impaction syndrome is a well-known cause of ulnar sided wrist pain stemming from increased load on the ulnocarpal side of the wrist. Numerous techniques have been described to reduce load on the carpus, but ulnar-shortening osteotomy has long been considered the standard of care.[1–11] Small changes in ulnar variance create significant changes in force transmission through the ulnocarpal joint.[12]

Classically, diaphyseal osteotomy has demonstrated encouraging short- and midterm results[13–17] but several complications have been reported with this technique, including residual ulnar positive variance,[17] hardware prominence requiring removal,[18–21] delayed union or nonunion,[22–25] and complex regional pain syndrome.[25,26] More recently, distal metaphyseal ulnar-shortening osteotomy has been reported in several studies with promising results.[27–30] Metaphyseal cancellous bone has richer blood supply and is less resistant to osteotomy compared with diaphyseal bone. This results in less bone necrosis from heating, thereby reducing the risk of nonunion and the time to return to unrestricted motion.[29,31,32] Biomechanical studies have reported significant reduction of the load across the ulnocarpal joint following metaphyseal osteotomies.[33] Additionally, osteotomy at the distal metaphysis does not interfere with the distal interosseous membrane,[34] which facilitates bony reduction and may allow greater shortening than diaphyseal osteotomy.

The purpose of this cadaveric study was to compare the biomechanical characteristics between diaphyseal and metaphyseal ulnar-shortening osteotomy with respect to (1) the maximal shortening achieved at each osteotomy site and (2) the force required to achieve shortening at each site as an indirect measurement of soft tissue constraint. We hypothesized that metaphyseal ulnar-shortening osteotomy (MUSO) allows for greater shortening compared with diaphyseal ulnar-shortening osteotomy (DUSO) with less stress on the soft tissues.

Methods

Specimens

Ten fresh frozen cadaver upper extremities were procured from the Anatomy Gifts Registry (Hanover, MD). This was a sample of convenience. The arms were intact from the scapula through the fingertips. The specimens included six left arms and four right arms from five male and five female donors, with a mean age at time of death of 71 years (range, 61–81 years). There was no history of trauma or surgery to any of the specimens. Prior to the experiment, ulnar variance of each specimen was measured on a posteroanterior radiograph that was obtained in neutral forearm rotation, 90 degrees of elbow flexion, and with the wrist in neutral position with respect to flexion–extension and radioulnar deviation.

Experimental Design

The experimental setup in neutral forearm rotation is illustrated in ►**Fig. 1**. A longitudinal incision along the ulna was carried down from the middiaphysis to the tip of the ulnar styloid. The forearm was secured to a wooden board by drilling a 5.0-mm Schanz's pin through the proximal ulna and into the board. The Schanz pin served as the static post for force measurements. A 20-mm transverse section of bone was resected with an oscillating saw at the metaphysis 20-mm proximal to the distal radioulnar joint (DRUJ). A ruler was used to ensure accuracy of the length of resection. Controlled ulnar shortenings in increments of 5 mm were performed until maximal shortening was achieved. Precut 5-mm acrylic glass blocks were used to ensure accuracy and consistency of the shortening procedure, for example, three of the blocks were placed at the osteotomy site to replicate 5 mm of shortening; two blocks were used to replicate 10 mm of shortening, etc. A Futek load cell (model LSB200, Futek, Irvine, CA) was attached to a distal post that was clamped to the surgical board and used to measure the force required for each sequential 5-mm of shortening (maximal capacity of 100 lbs and mean error of $\pm$ 0.1% of rated output). Proximally, a screw connected to the load cell was clamped to the distal ulnar metaphysis via lobster claw forceps. One of the investigators held steady tension during the shortening procedure to allow for recording of the forces to take place across 5 seconds. Ten measurements per second were recorded automatically on LabVIEW (National Instruments, Austin, TX), and the average of these recordings over 5 seconds was used as a single-data point. After the measurements were completed at the metaphysis, a 3.5-mm plate and 3.5-mm cortical screws (LC-DCP, DePuy Synthes, Paoli, PA) were used to fix the resected bone at the transverse osteotomy site to restore the anatomic length of the forearm.

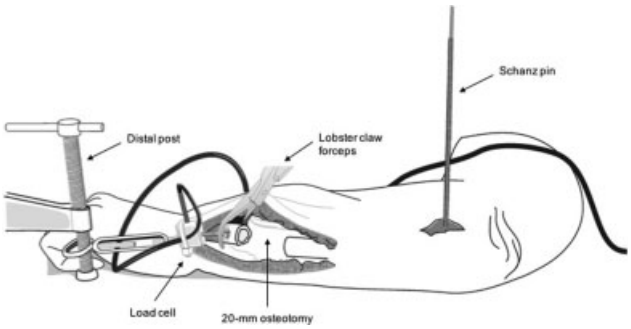

Fig. 1 Experimental setup: a longitudinal incision along the ulna was carried down from the middiaphysis to the tip of the ulnar styloid. The forearm was secured to a wooden board with a 5.0-mm Schanz's pin proximally, which served as the static post for force measurements. A 20-mm section of bone was resected at the metaphysis just proximal to the DRUJ. Proximally, a screw connected to the load cell was clamped to the distal ulnar metaphysis via lobster claw forceps. DRUJ, distal radioulnar joint.

A transverse diaphyseal osteotomy in the same fashion was then performed at a distance approximately 10-mm proximal to the proximal end of the metaphyseal osteotomy. This corresponded to a point proximal to the proximal attachment site of the distal interosseous membrane as described by Arimitsu et al.[34] Measurement procedures were repeated for incremental shortenings of 5 mm. Force measurements of the diaphyseal osteotomy were performed under three conditions as follows: (1) with the interosseous membrane (IOM) intact, (2) after transection of the central band of the IOM, and (3) after extensive release of the IOM and muscular attachments to the diaphysis.

Statistical Methods

A priori power calculation based on a clinically significant difference of 2 mm of shortening and a large effect size (Cohen's d of 0.8) determined that a sample size of 10 for each group yields power of 0.50 which is comparable to other experimental cadaveric studies with similar statistical measures.[35,36] Cadaveric studies control variables better than population studies and often do not require large sample sizes to achieve normal distribution and normal variance for acceptable statistical analysis. One-way analysis of variance (ANOVA) was used to compare differences in tensile force for each incremental shortening. Repeated measures ANOVA was used to evaluate the effect of sequential soft tissue release on the diaphyseal shortening. Data are presented as mean $\pm$ standard error of the mean. Post hoc analysis using Bonferroni's correction was used to determine differences between each group if initial ANOVA demonstrated statistical significance. Pearson's correlation coefficient was used to determine the relationship between preexperimental ulnar variance and maximal shortening achieved. Statistical significance was set at $p < 0.05$.

Results

Data from one cadaver was corrupted due to a software malfunction and was therefore excluded from analysis. In the remaining nine specimens, mean ulnar variance was -0.2 mm (range, -1.7 to 1.2 mm). Maximal shortening (mean, 9.1 ± 0.7 mm) was achieved with MUSO which was significantly greater compared with the amount of shortening achieved with DUSO with intact interosseous membrane (6.9 ± 0.3 mm, $p < 0.01$) and DUSO after central band release (7.4 ± 0.4 mm, $p < 0.05$). Similar amount of shortening was achieved between MUSO and DUSO after extensive interosseous membrane and muscle release was performed (9.1 ± 0.7 vs. 8.6 ± 0.4 mm, $p = 0.50$).

The force required for maximal shortening was lower for MUSO (6.1 ± 0.7 lbs.) compared with DUSO (6.9 ± 0.8 lbs.) but this was not statistically significant. For DUSO, incrementally less force to achieve maximal shortening was recorded after central band release (6.6 ± 0.4 lbs.) and after extensive soft tissue release (6.4 ± 0.9 lbs.); however, this difference was not statistically significant.

Discussion

The results of our study support our hypothesis that MUSO allows for greater amount of shortening in comparison to diaphyseal osteotomy with similar tensile force required for maximal shortening for the two techniques. Increased shortening with diaphyseal osteotomy was only achieved after substantial release of the soft tissue attachments to the ulna. These findings are consistent with the results by Arimitsu et al[34] who demonstrated the contribution of the distal interosseous membrane to DRUJ stability. They noted the greater longitudinal resistance to shortening when the osteotomy was performed proximal to ulnar attachment to the distal interosseous membrane which may lead to difficult healing of the osteotomy site. The authors posited that if the purpose of the shortening procedure were to improve DRUJ stability, the optimal osteotomy site should be 60-mm proximal to the ulnar styloid to preserve the soft tissues; while patients without DRUJ instability may benefit from distal metaphyseal osteotomy to facilitate union.[34]

Biomechanical studies have demonstrated that diaphyseal osteotomy increased DRUJ stability at the expense of increased DRUJ joint reaction force.[34,37,38] Nishiwaki et al[37] demonstrated that 3 to 6 mm of shortening led to increase tension of the triangular fibrocartilage complex and increased DRUJ stability, provided that the radioulnar ligament is at least partially intact. Recent studies have further sought to delineate the optimal site for ulnar-shortening osteotomy, with various studies, citing the distal 25% of the ulna as the recommended position.[2,3,34,39–41]

The rate of nonunion after ulnar-shortening osteotomy varies between 0 and 11% in the literature which is often attributed to inadequate bone-to-bone contact and is more problematic in the diaphysis.[28] Therefore, ulnar-shortening osteotomy performed through metaphyseal bone has gained popularity, with proponents postulating that the cancellous bone at the distal metaphysis has richer blood supply and facilitates reduction of the osteotomy site, allowing for better bone-to-bone contact and higher potential for successful healing of the osteotomy.[21,27,28,31] Various techniques for MUSO have been described.[8,21,27,31,42] In a biomechanical study of the closing wedge osteotomy technique at the distal ulnar metaphysis, Greenberg et al[33] demonstrated significant reductions in ulnar load in both static and dynamic phases of wrist motion without significant increases in transverse force across the DRUJ. The mean shortening achieved by the investigators was 2.8 mm in seven cadaver arms.[33]

There is a paucity of data on the long-term clinical effects of MUSO on DRUJ stability, but functional outcomes have appeared promising. Compared with a traditional diaphyseal technique fixed by plate and screws, Sennwald et al[21] noted nearly equivocal outcomes with respect to pain, satisfaction, wrist range of motion (ROM), and grip strength but greater shortening, earlier time to union, less implant-related pain, and lower rate of implant removal using an oblique metaphyseal osteotomy fixed by two lag screws. Recent studies have demonstrated improved QuickDASH (disabilities of the arm, shoulder, and hand) score, visual analog pain score, and wrist ROM after transverse osteotomy at the distal ulnar metaphysis using a low-profile 2.0-mm locking compression distal ulna plate for ulnocarpal abutment syndrome after failed conservative management.[28,43] A comparison of MUSO (14 patients) and DUSO (21 patients) demonstrated greater ulnar shortening (4.8 vs. 3.4 mm), shorter tourniquet time (46 vs. 72 minutes), and greater postoperative improvement in pain and functional (QuickDASH) scores for the MUSO group.[30] The difference in shortening, however, was attributed to the MUSO group requiring greater shortening rather than the technique itself. Our cadaveric results demonstrated that an additional 4 mm of shortening (for a maximal of approximately 9 mm) may be achieved with transverse metaphyseal shortening if warranted clinically; however, it must be cautioned that the additional shortening would result in fixation between the epiphyseal and diaphyseal bone which squanders the metaphyseal healing potential.

Shortenings of this magnitude are rarely needed in the setting of idiopathic ulnar impaction syndrome but may be needed after distal radius fracture malunion with severe shortening or in the setting of distal radius growth arrest in the pediatric population. For a more clinically significant scenario, we demonstrated slightly lower force transmission with metaphyseal compared with diaphyseal shortening. We cannot attest as to why greater shortening was achieved at the metaphysis without a concomitant increase in force. We postulate that this may be attributed to differences in modulus of elasticity between the soft tissues at the DRUJ and the wrist compared with soft tissues at the diaphysis. This slight increase in force required to achieve shortening at the diaphysis may also account for some of the differences in clinical results seen in recent studies comparing the two techniques.[21,30]

There are several limitations to this study. First, the mean ulnar variance of our specimens was approximately neutral, with ulnar negative variance in a few specimens. The intended purpose of the shortening procedure is to treat ulnar impaction syndrome typically associated with ulnar positive variance[44]; therefore, the amount of maximal shortening may be even greater if specimens with positive variance were selectively tested. Second, we focused specifically on amount of shortening and the forces on the soft tissue necessary to achieve the desired shortening; therefore, it is difficult to extrapolate the effect of maximal shortening on ulnar load and DRUJ stiffness, although prior studies suggest improved DRUJ stability after shortening.[34,37,38] Third, all testing was performed with the forearm in neutral rotation; therefore, we were unable to elucidate the effect of excessive shortening on soft tissue tension with pronosupination. Lastly, testing of the diaphyseal osteotomy was performed after fixation of the resected metaphyseal osteotomy. Motion at the fixed ulna may have affected the outcomes; however, our results were consistent with previous biomechanical studies that highlighted the importance of soft tissue constraint on ulnar shortening.[34,37,38]

This study adds to the existing literature on ulnar shortening by demonstrating that metaphyseal ulnar osteotomy allows greater maximal shortening but requires similar force compared with diaphyseal osteotomy. With respect to clinical application, both sites of osteotomy can achieve sufficient shortening to decompress the ulnocarpal joint for most cases of ulnar impaction syndrome. The greater shortening from metaphyseal ulnar osteotomy may be reserved for severe cases of shortening, especially after distal radius malunion or in the setting of distal radius growth arrest in the pediatric population. Sequential release of the interosseous membrane permits increased shortening at the diaphysis, but requires extensive soft tissue release, which may not be compatible with clinical application.

Note

The study was performed at Wake Forest Baptist Medical Center.

Funding

This study was funded by a grant from the American Foundation for Surgery of the Hand.

Conflict of Interest

F.A.N. Jr. reports grants from American Foundation for Surgery of the Hand, during the conduct of the study. All other authors report no relevant conflict of interests related with this article.

Acknowledgments

The authors thank the contributions to this study from Ms. Eileen Elsner for her illustration.

References

1 Rayhack JM, Gasser SI, Latta LL, Ouellette EA, Milne EL. Precision oblique osteotomy for shortening of the ulna. J Hand Surg Am 1993;18(05):908–918
2 Chun S, Palmer AK. The ulnar impaction syndrome: follow-up of ulnar shortening osteotomy. J Hand Surg Am 1993;18(01):46–53
3 Chen NC, Wolfe SW. Ulna shortening osteotomy using a compression device. J Hand Surg Am 2003;28(01):88–93
4 Kitzinger HB, Karle B, Löw S, Krimmer H. Ulnar shortening osteotomy with a premounted sliding-hole plate. Ann Plast Surg 2007;58(06):636–639
5 Lauder AJ, Luria S, Trumble TE. Oblique ulnar shortening osteotomy with a new plate and compression system. Tech Hand Up Extrem Surg 2007;11(01):66–73
6 Pouliot M, Yao J. Ulnar shortening osteotomy utilizing a TriMed ulnar osteotomy system. Tech Hand Up Extrem Surg 2014;18(02):72–76
7 Lautenbach M, Millrose M, Schmidt NS, Zach A, Eichenauer F, Eisenschenk A. Ulnocarpal impaction syndrome: treatment with a transverse ulnar shortening osteotomy from an ulnodorsal approach. Arch Orthop Trauma Surg 2014;134(06):881–885
8 Khouri JS, Hammert WC. Distal metaphyseal ulnar shortening osteotomy: technique, pearls, and outcomes. J Wrist Surg 2014;3(03):175–180
9 Clark SM, Geissler WB. Results of ulnar shortening osteotomy with a new plate compression system. Hand (N Y) 2012;7(03):281–285
10 Baek GH, Chung MS, Lee YH, Gong HS, Lee S, Kim HH. Ulnar shortening osteotomy in idiopathic ulnar impaction syndrome. Surgical technique. J Bone Joint Surg Am 2006;88(Suppl 1, Pt 2):212–220
11 Sraj SA, Budoff JE. Ulnar or radial shortening osteotomy with a single saw cut. J Hand Surg Am 2009;34(07):1248–1251
12 Werner FW, Palmer AK, Fortino MD, Short WH. Force transmission through the distal ulna: effect of ulnar variance, lunate fossa angulation, and radial and palmar tilt of the distal radius. J Hand Surg Am 1992;17(03):423–428
13 Tatebe M, Shinohara T, Okui N, Yamamoto M, Hirata H, Imaeda T. Clinical, radiographic, and arthroscopic outcomes after ulnar shortening osteotomy: a long-term follow-up study. J Hand Surg Am 2012;37(12):2468–2474
14 Fulton C, Grewal R, Faber KJ, Roth J, Gan BS. Outcome analysis of ulnar shortening osteotomy for ulnar impaction syndrome. Can J Plast Surg 2012;20(01):e1–e5
15 Lee JI, Suh DH, Byun JS, et al. Radiographic appearance and patient outcome after ulnar shortening osteotomy for idiopathic ulnar impaction syndrome. J Hand Surg Am 2012;37(05):975–981
16 Baek GH, Lee HJ, Gong HS, et al. Long-term outcomes of ulnar shortening osteotomy for idiopathic ulnar impaction syndrome: at least 5-years follow-up. Clin Orthop Surg 2011;3(04):295–301
17 Cha SM, Shin HD, Kim KC. Positive or negative ulnar variance after ulnar shortening for ulnar impaction syndrome: a retrospective study. Clin Orthop Surg 2012;4(03):216–220
18 Katz DI, Seiler JG III, Bond TC. The treatment of ulnar impaction syndrome: a systematic review of the literature. J Surg Orthop Adv 2010;19(04):218–222
19 Fufa DT, Carlson MG, Calfee RP, Sriram N, Gelberman RH, Weiland AJ. Mid-term results following ulna shortening osteotomy. HSS J 2014;10(01):13–17

20 Iwasaki N, Ishikawa J, Kato H, Minami M, Minami A. Factors affecting results of ulnar shortening for ulnar impaction syndrome. Clin Orthop Relat Res 2007;465(465):215–219
21 Sennwald G, Della Santa D, Beaulieu JY. A comparison of diaphyseal and metaphyseal techniques of ulna shortening. J Hand Surg Eur Vol 2013;38(05):542–549
22 Sachar K. Ulnar-sided wrist pain: evaluation and treatment of triangular fibrocartilage complex tears, ulnocarpal impaction syndrome, and lunotriquetral ligament tears. J Hand Surg Am 2008;33(09):1669–1679
23 Chen F, Osterman AL, Mahony K. Smoking and bony union after ulna-shortening osteotomy. Am J Orthop 2001;30(06): 486–489
24 Sunil TM, Wolff TW, Scheker LR, McCabe SJ, Gupta A. A comparative study of ulnar-shortening osteotomy by the freehand technique versus the Rayhack technique. J Hand Surg Am 2006;31 (02):252–257
25 Rajgopal R, Roth J, King G, Faber K, Grewal R. Outcomes and complications of ulnar shortening osteotomy: an institutional review. Hand (N Y) 2015;10(03):535–540
26 Doherty C, Gan BS, Grewal R. Ulnar shortening osteotomy for ulnar impaction syndrome. J Wrist Surg 2014;3(02):85–90
27 Hammert WC, Williams RB, Greenberg JA. Distal metaphyseal ulnar-shortening osteotomy: surgical technique. J Hand Surg Am 2012;37(05):1071–1077
28 Nunez FA Jr., Barnwell J, Li Z, Nunez FA Sr. Metaphyseal ulnar shortening osteotomy for the treatment of ulnocarpal abutment syndrome using distal ulna hook plate: case series. J Hand Surg Am 2012;37(08):1574–1579
29 Yin HW, Qiu YQ, Shen YD, Xu JG, Gu YD, Xu WD. Arthroscopic distal metaphyseal ulnar shortening osteotomy for ulnar impaction syndrome: a different technique. J Hand Surg Am 2013;38 (11):2257–2262
30 Marquez-Lara A, Nuñez FA Jr., Kiymaz T, Nuñez FA Sr, Li Z. Metaphyseal versus diaphyseal ulnar shortening osteotomy for treatment of ulnar impaction syndrome: a comparative study. J Hand Surg Am 2017;42(06):477.e1–477.e8
31 Slade JF III, Gillon TJ. Osteochondral shortening osteotomy for the treatment of ulnar impaction syndrome: a new technique. Tech Hand Up Extrem Surg 2007;11(01):74–82
32 Aronson J, Shen X. Experimental healing of distraction osteogenesis comparing metaphyseal with diaphyseal sites. Clin Orthop Relat Res 1994;(301):25–30
33 Greenberg JA, Werner FW, Smith JM. Biomechanical analysis of the distal metaphyseal ulnar shortening osteotomy. J Hand Surg Am 2013;38(10):1919–1924
34 Arimitsu S, Moritomo H, Kitamura T, et al. The stabilizing effect of the distal interosseous membrane on the distal radioulnar joint in an ulnar shortening procedure: a biomechanical study. J Bone Joint Surg Am 2011;93(21):2022–2030
35 Kociolek AM, Tat J, Keir PJ. Biomechanical risk factors and flexor tendon frictional work in the cadaveric carpal tunnel. J Biomech 2015;48(03):449–455
36 Xu NM, Brown PJ, Plate JF, et al. Fibrin glue augmentation for flexor tendon repair increases friction compared with epitendinous suture. J Hand Surg Am 2013;38(12):2329–2334
37 Nishiwaki M, Nakamura T, Nakao Y, Nagura T, Toyama Y. Ulnar shortening effect on distal radioulnar joint stability: a biomechanical study. J Hand Surg Am 2005;30(04):719–726
38 Canham CD, Schreck MJ, Maqsoodi N, Messing S, Olles M, Elfar JC. Distal radioulnar joint reaction force following ulnar shortening: diaphyseal osteotomy versus wafer resection. J Hand Surg Am 2015;40(11):2206–2212
39 Darrow JC Jr., Linscheid RL, Dobyns JH, Mann JM III, Wood MB, Beckenbaugh RD. Distal ulnar recession for disorders of the distal radioulnar joint. J Hand Surg Am 1985;10(04):482–491
40 Darlis NA, Ferraz IC, Kaufmann RW, Sotereanos DG. Step-cut distal ulnar-shortening osteotomy. J Hand Surg Am 2005;30(05):943–948
41 Luria S, Lauder AJ, Trumble TE. Comparison of ulnar-shortening osteotomy with a new Trimed dynamic compression system versus the Synthes dynamic compression system: clinical study. J Hand Surg Am 2008;33(09):1493–1497
42 Benis S, Goubau JF, Mermuys K, et al. The oblique metaphyseal shortening osteotomy of the distal ulna: surgical technique and results of ten patients. J Wrist Surg 2017;6(01):39–45
43 Nunez FA Jr., Li Z, Campbell D, Nunez FA Sr. Distal ulna hook plate: angular stable implant for fixation of distal ulna. J Wrist Surg 2013;2(01):87–92
44 Friedman SL, Palmer AK. The ulnar impaction syndrome. Hand Clin 1991;7(02):295–310