Published online: 2019-08-22

Spontaneous Recurrent Chronic Subdural Hematoma in a Young Woman

Ashis Patnaik[1] Arunav Sharma[1] Rabi Narayan Sahu[1] Sumit Bansal[1] Ranjan Jena[1]

[1]Department of Neurosurgery, All India Institute of Medical Sciences (AIIMS), Bhubaneswar, Odisha, India

Address for correspondence Ashis Patnaik, MBBS, MS, MCh, Department of Neurosurgery, All India Institute of Medical Sciences (AIIMS), Bhubaneswar 751019, Odisha, India (e-mail: drashispatnaik@gmail.com).

Indian J Neurosurg 2019;8:142–144

Spontaneous chronic subdural hematoma (CSH) is rare and is mostly seen in elderly persons. Only a few case reports have reported it in young individuals. We report an interesting rare case of spontaneous CSH in a young woman and the problems faced in its management. This case report also highlights the occasional but important role of magnetic resonance imaging (MRI) in managing multiseptated CSH.

A 23-year-old woman, laborer by profession, presented with complaints of headache for past 30 days with intermittent vomiting for past 5 days. The patient was fully conscious and oriented, with no neurologic deficits. Computed tomographic (CT) scan of the head showed left side frontoparietal iso- to hypodense collection in subdural location with mass effect and midline shift, suggestive of CSH (►**Fig. 1**). There was no history of any trauma to the head, bleeding disorder, or intake of any anticoagulants. There was history of right-sided CSH 6 years earlier, which was drained by a burr hole in another hospital. The patient was completely normal in intervening period. Her coagulation parameters were within normal range. The hematoma was drained by frontal and parietal double burr hole technique evacuating nearly 100 cc of motor oil colored fluid and clots. Her symptoms rapidly relieved, and she was discharged on postoperative day 3. Twenty days after discharge, she presented with similar symptoms of headache, vomiting, and a new-onset right-sided hemiparesis. CT scan showed a large subdural collection in left frontoparietal region (►**Fig. 2**). MRI of the brain showed presence of multiple septae within the hematoma that was not apparent in CT scan (►**Fig. 3**). A formal frontoparietal craniotomy was done with excision of capsule and evacuation of hematoma (►**Fig. 4**). Postoperative CT scan showed complete removal of the hematoma (►**Fig. 5**). On follow-up of the patient after 6 months, there were no fresh complaints and the CT scan was absolutely normal (►**Fig. 6**).

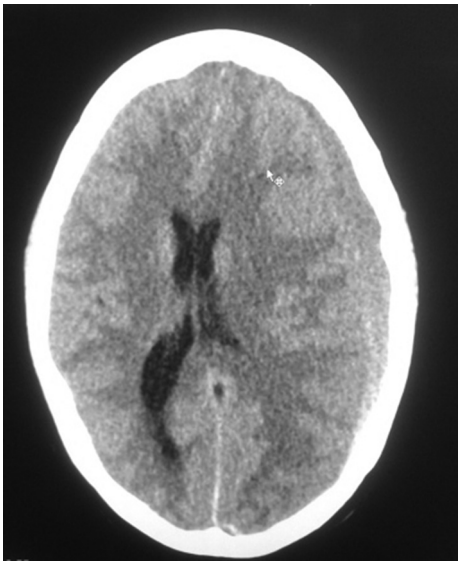

Fig. 1 Axial CT scan showing left-sided frontoparietal isodense collection with midline shift.

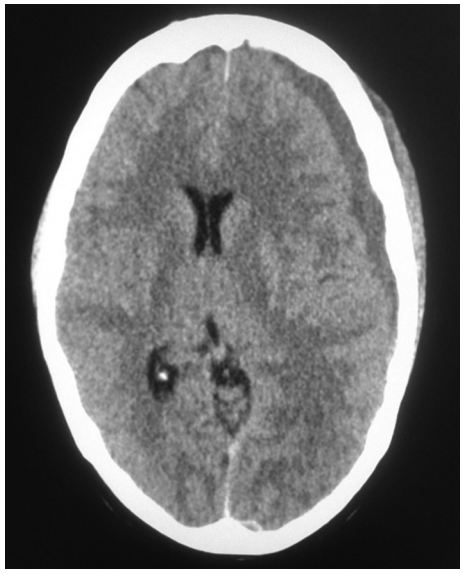

Fig. 2 Post 20 days of discharge, patient's CT scan showing hypodense collection in the same region with moderate mass effect and midline shift.

received
August 20, 2018
accepted
September 6, 2018
published online
August 22, 2019

DOI https://doi.org/10.1055/s-0039-1694852
ISSN 2277-954X.

©2019 Neurological Surgeons' Society of India

License terms

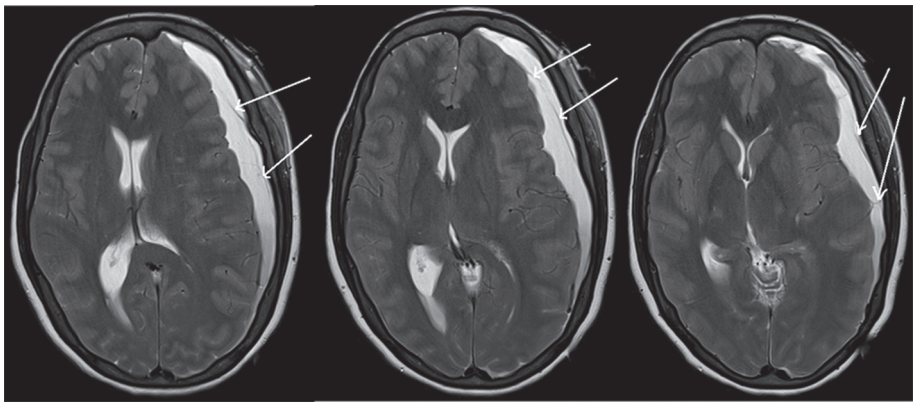

Fig. 3 T2-weighted MRI showing characteristic septae (white arrows) within the subdural collection.

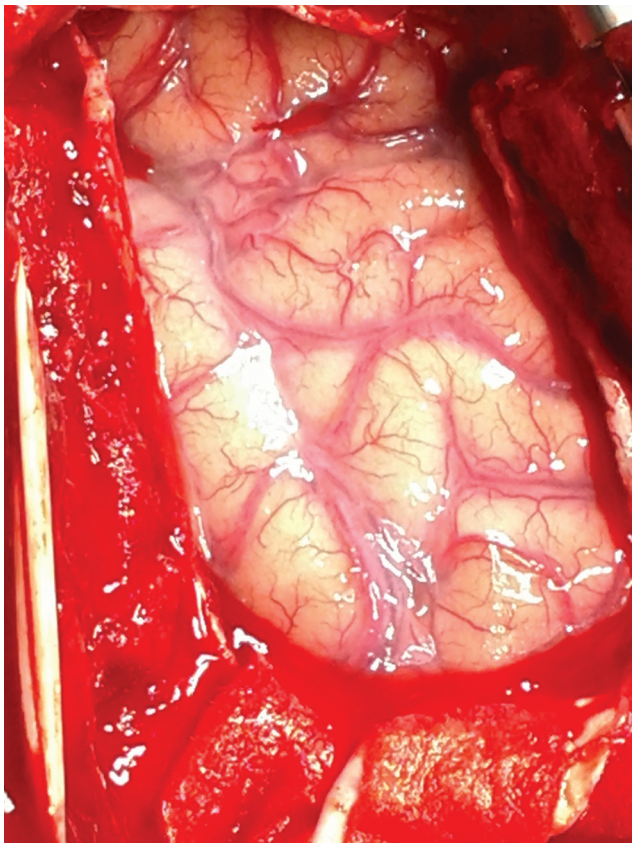

Fig. 4 Fully expanded, pulsatile brain after craniotomy and membranectomy.

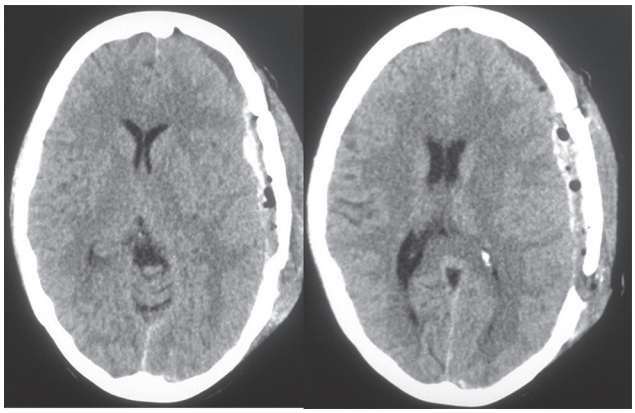

Fig. 5 Post second operation, CT scan showing complete removal of subdural hematoma.

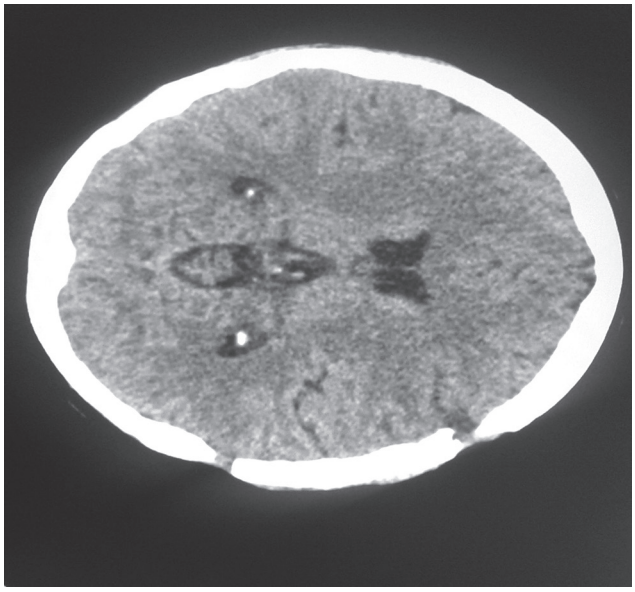

Fig. 6 CT scan after 8 months of operation.

Chronic subdural hematoma is basically a disease of the elderly, and most of them are caused by trivial trauma. Spontaneous onset CSH in young persons is very rare.[1-6] Because of its rarity in young population and the nonspecific nature of symptoms, CSH is often diagnosed late and sometimes undertreated and neglected. Even in young population group, trauma remains the most common cause of such hematoma; however, some other causes have been reported. Coagulopathy,[1] arteriovenous malformation, and aneurysm[7] have been reported to cause spontaneous CSH. Intracranial hypotension[8] and middle fossa arachnoid cyst[9] have also been implicated as the predisposing factors for CSH. This case did not have any coagulation abnormality or any vascular pathology. Aneurysms can cause acute subdural hematoma due to their previous arachnoid adhesions and subsequent rupture into the subdural space, which gradually converts into a chronic collection. Wang et al[6] reported an interesting case

of spontaneous CSH in a flute trainer, which they thought to be caused by increased intravenous pressure induced by repeated blowing of air (Valsalva's maneuver). Similar role of repeated Valsalva's maneuver in causing subdural hematoma has been reported by Brennan et al[10] in a marathon runner and Jacome and Yanez[11] in a heavyweight lifter. Intracranial hypotension secondary to systemic hypotension or exercise can cause spontaneous subdural hematoma.

The investigation of choice in subdural hematomas is CT scan. However, rarely, as in this case, the cause of recurrent subdural hematoma could only be elicited by MRI of the brain, which showed multiseptated nature of the collection. CT scan did not show any internal septae within the collection.

The exact cause of CSH could not be revealed in this case. Multiple factors such as intracranial hypotension and straining due to labor work (Valsalva's factor) could have played a role in pathogenesis of such rare hematoma. This case is also exclusive in that it stresses the rare but important role of MRI in knowing the internal architecture of hematoma, which plays an important role in further management. Overall, the CSH should be considered in the differential diagnosis of headache in young healthy persons without any history of trauma, as a rare but easily treatable cause.

Conflict of Interest

None.

References

1 Albanese A, Tuttolomondo A, Anile C, et al. Spontaneous chronic subdural hematomas in young adults with a deficiency in coagulation factor XIII. Report of three cases. J Neurosurg 2005;102(6):1130–1132

2 Arpino L, Gravina M, Basile D, Franco A. Spontaneous chronic subdural hematoma in a young adult. J Neurosurg Sci 2009;53(2):55–57

3 Bosma JJ, Miles JB, Shaw MD. Spontaneous chronic and subacute subdural haematoma in young adults. Acta Neurochir (Wien) 2000;142(11):1307–1310

4 De Carvalho D, Almenawer S, Lozej M, Noble H, Murty NK. Spontaneous chronic subdural hematoma in a 22-year-old healthy woman. World Neurosurg 2013;80(5):654.e9–654.e11

5 Hou K, Li CG, Zhang Y, Zhu BX. The surgical treatment of three young chronic subdural hematoma patients with different causes. J Korean Neurosurg Soc 2014;55(4):218–221

6 Wang HS, Kim SW, Kim SH. Spontaneous chronic subdural hematoma in an adolescent girl. J Korean Neurosurg Soc 2013;53(3):201–203

7 Kotwica Z, Polis L. The association of arteriovenous malformation, aneurysm and chronic subdural hematoma. Case report. Zentralbl Neurochir 1986;47(2):158–160

8 Mori K, Yamamoto T, Horinaka N, Maeda M. Arachnoid cyst is a risk factor for chronic subdural hematoma in juveniles: twelve cases of chronic subdural hematoma associated with arachnoid cyst. J Neurotrauma 2002;19(9):1017–1027

9 Umebayashi D, Takado M, Osaka Y, Nakahara Y, Tenjin H. [Two cases of spontaneous intracranial hypotension with bilateral chronic subdural hematomas] [in Japanese]. Brain Nerve 2011;63(2):171–175

10 Brennan PM, Fuller E, Shanmuganathan M, Keston P, Fouyas I. Spontaneous subdural haematoma in a healthy young male. BMJ Case Rep 2011;2011:xx

11 Jacome DE, Yanez GF. Subdural haematoma upon straining. J Neurol Neurosurg Psychiatry 1989;52(1):134