

# The Effect of Graft Positions on the Stability of Total Hip Arthroplasty with Different Types of Subtrochanteric Shortening\*

## *Efeito das posições dos enxertos na estabilidade da artroplastia total de quadril com diferentes tipos de encurtamento subtrocantérico*

Ethem Aytac Yazar<sup>1,2,3</sup> Ozgun Karakus<sup>1,2,3</sup>  Baransel Saygi<sup>1,2,3</sup>

<sup>1</sup> Department of Orthopedic Surgery, Fatih Sultan Mehmet Training and Research Hospital, Duzici City Hospital, Osmaniye, Turkey

<sup>2</sup> Department of Orthopedic Surgery, Fatih Sultan Mehmet Training and Research Hospital, Omer Halis Demir University Hospital, Nigde, Turkey

<sup>3</sup> Department of Orthopedic Surgery, Maltepe University and Fatih Sultan Mehmet Training and Research Hospital, Istanbul, Turkey

Address for correspondence Ozgun Karakus, MD, Alparslan Turkes st. Consept Nigde bloc no: A-24 Niðde, Turkey (e-mail: ozgunkarakus@hotmail.com).

Rev Bras Ortop 2019;54:465–470.

### Abstract

**Objective** The aim of the present study is to investigate the biomechanical stability of different subtrochanteric osteotomy types and graft positions in cases of dysplastic coxarthrosis that require total hip arthroplasty with shortening osteotomy, as well as to find out the most effective osteotomy type and graft position.

**Method** Femur sawbones were used to compare different types of femoral shortening osteotomy (transverse, oblique, and step-cut). Strut grafts, which were prepared at the side of the subtrochanteric shortening osteotomy, were fixed in different positions (anterolateral, mediolateral, and anteroposterior). The fixation of the strut grafts was performed using two steel cables (with 2.0 mm of thickness) with the same strength. The failure values of composite femurs were recorded for axial and rotational loadings.


**Results** Biomechanically, there were no statistically significant differences between the types of femoral subtrochanteric shortening osteotomy and the positions of the applied strut graft.

**Conclusion** No superiority was observed between the types of femoral subtrochanteric shortening osteotomy regarding stability. Additionally, against stress, similar results were obtained for different strut graft positions. In conclusion, we believe that using the method in which the surgeon is experienced and that is the easiest to apply would be the best choice.

### Keywords

- ▶ osteotomy
- ▶ bone transplantation
- ▶ coxarthrosis
- ▶ arthroplasty, replacement, hip
- ▶ hip dislocation

\* Study conducted at the Department of Orthopedic Surgery, Fatih Sultan Mehmet Training and Research Hospital, Omer Halis Demir University Hospital, Nigde, Turkey.

 Ozgun Karakus's ORCID is <https://orcid.org/0000-0002-7430-1768>.

**Resumo**

**Objetivo** O objetivo do presente estudo é investigar a estabilidade biomecânica de diferentes tipos de osteotomias subtrocantéricas e posições de enxertos em coxartroses displásicas que necessitam de artroplastia total de quadril com osteotomia de encurtamento, e determinar o tipo de osteotomia e a posição do enxerto que são mais eficazes.

**Método** Modelos de fêmur (*sawbones*) foram usados para comparar os tipos de osteotomia de encurtamento femoral (transversal, oblíqua e em degrau de escada [*step-cut*]). Os enxertos em haste, preparados do lado da osteotomia subtrocantérica, foram fixados em diferentes posições (ântero-lateral, medial-lateral e ântero-posterior). A fixação dos enxertos foi feita com dois cabos de aço (de 2,0 mm de largura) de mesma resistência. Os valores de falha dos fêmures compostos para cargas axiais e rotacionais foram registrados.

**Resultados** Do ponto de vista biomecânico, não houve diferenças estatisticamente significativas entre os tipos de osteotomia de encurtamento subtrocantérico femoral e as posições dos enxertos em haste aplicados.

**Conclusão** Não houve superioridade entre os tipos de osteotomia de encurtamento subtrocantérico femoral quanto à estabilidade. Além disso, em relação à resistência ao estresse, os resultados obtidos com diferentes posições das hastes foram similares. Assim, acreditamos que o método mais indicado é aquele em que o cirurgião é experiente e cuja aplicação é mais fácil.

**Palavras-chave**

- ▶ osteotomia
- ▶ transplante ósseo
- ▶ coxartrose
- ▶ artroplastia de quadril
- ▶ luxação do quadril

**Introduction**

Hip joints provide an anatomical structure that is connected to the lower limbs of the body to ensure an upright posture and balanced motion. These joints are formed for unlimited modifications and amplifications of basic movements such as force, movement, effective walking, running, jumping and climbing.<sup>1</sup> The hip joint is the most burdened joint in the human body.<sup>2</sup> For this reason, there is a potential risk of naturally developing degenerative arthritis throughout functional life.<sup>3</sup>

In a hip joint with degenerative arthritis, the main purpose of the treatment is to relieve pain and create a range of hip joint motion as close to normal as possible. It is currently not possible to restore the hip joint, which is affected by many factors and worn out due to the physiological nature of the cartilage structure, to its natural structure. Methods such as osteotomies, resection arthroplasties and hip arthrodeses, which were designed to balance the load distribution affecting the hip and to relieve pain, are still used whenever necessary.<sup>4,5</sup> Total hip arthroplasty is an alternative solution for the problem. Initially, cemented total hip arthroplasty applications were used, but they are progressively being replaced by hybrid and cementless systems.<sup>6-8</sup>

Developmental dysplasia of the hip involves a wide range of pathologies, from a simple hip instability consisting of capsular laxity to complete dislocation, in which the femur head is located completely outside the acetabulum.<sup>9</sup> Cases that cannot be detected at an early age can cause hip osteoarthritis in young adults.<sup>10</sup>

In patients without early diagnosis and treatment, as well as in cases of inadequately treated young adults, acetabular and

femoral osteotomies have been applied to prevent osteoarthritis and other pathologies that can develop secondary to dysplasia.<sup>3,11,12</sup> Despite these surgical interventions, degeneration and osteoarthritis of the hip joint may still develop. In patients with pain and functional limitation due to osteoarthritis, the results of total hip arthroplasty are successful and satisfactory.<sup>13</sup>

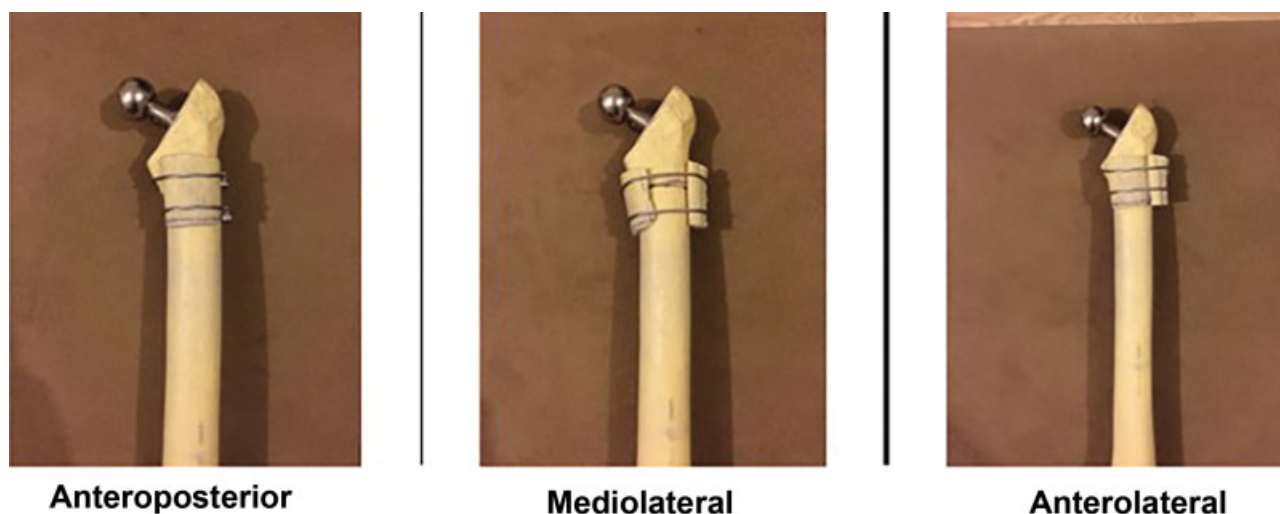The aim of the present study is to biomechanically compare the effect of graft positions and subtrochanteric osteotomy techniques on the primary stability of total hip arthroplasty requiring shortening.

**Materials and Methods**

The suitability of this study was approved by the Fatih Sultan Mehmet Education and Training Hospital Ethics Committee.

A total of 63 composite femurs (*sawbones*, item number 1130 medium-left, TST AŞ, İstanbul-Turkey) were used for each loading experiment. They were divided into three groups according to the type of femoral shortening osteotomy: transverse (TO group), oblique (OO group), and step-cut (SO group), and each group was divided into three subgroups according to the graft positions; anteroposterior (AP subgroup), mediolateral (ML subgroup) and anterolateral (AL subgroup).

A 4-cm segmental bone resection (shortening) was performed in the subtrochanteric region of each femoral *sawbone* according to the type of osteotomy of the group. The osteotomy sides were calibrated with a Vernier caliper (Astor Vernier, Calipar, China) and marked with a pen. After the osteotomy was completed, the resected bone was cut vertically into two equal pieces of grafts that were positioned



**Fig. 1** Positions of the graft: anteroposterior, mediolateral and anterolateral.

anteroposteriorly, mediolaterally and anterolaterally, centering the osteotomy side, and fixed with cables around each composite bone (►Fig. 1). This procedure was repeated for each bone according to the type of osteotomy of the group.

For the fixation of each graft, 2 bone cables (Accord cable system, no. 7136-0005, Smith and Nephew, Memphis, TN, US) tensioned at 50 pounds per inch were used. Splinted conical stems (Wagner cone, size no. 21/135, Zimmer, Warsaw, IN, US) were implanted as femoral prostheses into each bone.

Axial and torsional loading experiments of 2500 N and 200 N respectively were applied to the composites bones. The experiments were completed in a biomechanical laboratory with a test device (Instron, SHIMADZU 10KN AGS-J; made in Kyoto, Japan, 8802 load cell). The loading rate was of 5 mm per minute for all samples (data rate of 50 ms/200 Hz).<sup>14</sup>

## Results

All samples were tested until failure. The values of the breaking stress for each of the samples was measured. In every sample, the composite femur material was fractured from the distal end of the femoral prosthesis component. The results of the axial and torsional loadings are shown in ►Tables 1 and 2.

There were no statistically significant differences between the types of osteotomy when the graft was positioned anteroposteriorly, mediolaterally, and anterolaterally.

There were no statistically significant differences between the types of osteotomy and graft positions between and within each group.

The statistical analysis was performed using the Statistical Package for the Social Sciences (SPSS, SPSS, Inc., Chicago, IL, US) software, version 16.0. The data were analyzed using descriptive statistics (mean, standard deviation, median, frequency, percentage, minimum, maximum). The Kruskal-Wallis test and the Mann-Whitney U test were used for the comparison between and within the three groups.

## Discussion

In 1973, Charnley and Feagin<sup>15</sup> reported that total hip arthroplasty should be avoided in dysplastic hips, especially in cases of Crowe type 3 and 4 dislocations.<sup>15</sup> However, with the development of new types of prosthesis and techniques, total hip arthroplasty has begun to be performed at younger ages, even in cases of dysplastic hips.<sup>16,17</sup>

In the surgical treatment of coxarthrosis due to developmental dysplasia, it is widely accepted to lower the acetabulum to its true level. This helps reduce the reaction force of the joint, increases the abductor lever arm, and, consequently, improves the gait function and prolongs the mechanical survival of the acetabular component.<sup>18</sup>

Total hip prosthesis application in coxarthrosis secondary to developmental dysplasia can differ significantly from the application in primary osteoarthritis. The proximal migration of the femur creates anatomical and biomechanical changes in the bone and soft tissues, and these make the application of arthroplasty technically challenging and more prone to complications.<sup>19</sup> Many authors have emphasized that femoral subtraction osteotomy should be performed to prevent neurovascular complications in Crowe type 3 and 4 hips, which are not submitted to reduction.<sup>19-22</sup>

Two major types of femoral subtraction osteotomy have been described technically in the literature:<sup>20,21</sup> the proximal femoral resection and distal shifting of the trochanter major, and the subtrochanteric metaphyseal shortening without the trochanter major osteotomy.

Without femoral shortening, it is almost impossible to bring the femur head to the true acetabulum level. Therefore, subtraction is the standard procedure in these patients. When the clinical series in the literature were reviewed, we observed that the authors chose the osteotomy technique based on their own clinical experience. The average shortening ranged from 3.1 cm to 5 cm in various series.<sup>23,24</sup> In the present study, 4 cm was applied considering these values.<sup>14</sup>

The purpose of using a composite femur is to set up experiments at the highest level, without the difficulty of storing

**Table 1** Distribution of femoral composite bone failure values for axial loading according to the groups (N/mm)

		Femoral failure load			anteroposterior/ mediolateral <i>p</i> -value	anteroposterior/ anterolateral <i>p</i> -value	mediolateral/ anterolateral <i>p</i> -value
		Anteroposterior	Mediolateral	Anterolateral			
TO group	N	7	7	7	0.565	0.949	0.749
	Mean ± SD	827.61 ± 51.81	842.11 ± 48.14	828.38 ± 34.66			
	Min–Max	761.82–912.69	790.61–910.42	788.04–875.38			
OO group	N	7	7	7	0.749	0.848	0.949
	Mean ± SD	837.41 ± 38.19	850.24 ± 49.86	842.11 ± 52.68			
	Min–Max	783.59–886.43	780.73–907.81	797.38–916.93			
SO group	N	7	7	7	0.277	0.482	0.337
	Mean ± SD	838.71 ± 48.15	853.53 ± 33.99	826.06 ± 47.66			
	Min–Max	791.82–913.43	817.54–917.75	765.61–881.03			
<sup>a</sup> <i>p</i> -value		0.872	0.763	0.708			
<sup>b</sup> <i>p</i> -value (group 1-group 2)		0.655	0.848	0.565			
<sup>b</sup> <i>p</i> -value (group 1-group 3)		0.655	0.337	0.949			
<sup>b</sup> <i>p</i> -value (group 2-group 3)		0.949	0.949	0.406			

Notes: <sup>a</sup>Kruskal-Wallis test; <sup>b</sup>Mann-Whitney U test; \**p* < 0.05.

Abbreviations: Max, maximum; Min, minimum; OO, oblique osteotomy; SD, standard deviation; SO, step-cut osteotomy; TO, transverse osteotomy.

**Table 2** Distribution of femoral composite bone failure values for rotational loading according to the groups (N/mm)

		Femoral failure load			anteroposterior/ mediolateral <i>p</i> -value	anteroposterior/ anterolateral <i>p</i> -value	mediolateral/ anterolateral <i>p</i> -value
		Anteroposterior	Mediolateral	Anterolateral			
TO group	N	7	7	7	0.87	0.99	0.75
	Mean ± SD	54.87 ± 3.43	55.64 ± 3.18	54.83 ± 2.28			
	Min–Max	50.49–60.55	52.21–60.19	52.14–57.96			
OO group	N	7	7	7	0.81	0.87	0.98
	Mean ± SD	55.53 ± 2.53	56.18 ± 3.29	56.14 ± 3.49			
	Min–Max	51.84–58.70	51.75–60.22	52.66–60.63			
SO group	N	7	7	7	0.49	0.69	0.42
	Mean ± SD	55.51 ± 3.18	56.40 ± 2.23	54.77 ± 3.16			
	Min–Max	52.39–60.50	54.00–60.68	50.74–58.43			
<sup>a</sup> <i>p</i>		0.96	0.88	0.78			
<sup>b</sup> <i>p</i> (group 1-group 2)		0.69	0.88	0.61			
<sup>b</sup> <i>p</i> (group 1-group 3)		0.66	0.53	0.96			
<sup>b</sup> <i>p</i> (group 2-group 3)		0.99	0.96	0.52			

Notes: <sup>a</sup>Kruskal-Wallis test; <sup>b</sup>Mann-Whitney U test; \**p* < 0.05.

Abbreviations: Max, maximum; Min, minimum; OO, oblique osteotomy; SD, standard deviation; SO, step-cut osteotomy; TO, transverse osteotomy.

cadaverous specimens, and to standardize the conditions, such as the material used and the commercial suitability.

There are various studies on the effect of joint reaction forces and joint surface pressure distribution on the hip during single-leg stance and walking.<sup>25,26</sup> In the present study, 2.5 kN were chosen for the axial load, which is ~ 3.5 times the average adult body weight.<sup>14</sup> The load transfer affecting the osteotomy

line may negatively affect the fracture in some subtrocantalic osteotomy patients.<sup>26,27</sup> For this reason, there is a need for stabilization in the osteotomy line. Transverse osteotomy is thought to have low rotational stability. However, similar results have been reported with difficult techniques (such as step-cut), which are thought to have high rotational stability.<sup>18,24,28–30</sup>

Large numbers of biomechanical studies have been performed with trochanteric and subtrochanteric osteotomies, as well as with pelvic osteotomies related to total hip arthroplasties. However, according to the current knowledge, there is no study on the position of the graft applied in total hip arthroplasty combined with subtrochanteric shortening osteotomy. In the present study, the osteotomy methods and the relationship of stability according to the graft positions in the osteotomy line were investigated. There was no statistically significant difference between the osteotomy methods and the graft positions.

Gotze et al<sup>30</sup> investigated the need for extramedullary fixation in transverse subtrochanteric shortening osteotomy, and found that intramedullary stabilization is related to the cross-sectional geometry of the femoral component, which is also related to distal rotational stability. They have also suggested that step-cut osteotomy or the use of strut graft and cable fixation are not required. On the other hand, although the structural properties of the implants used in arthroplasty are thought to play an important role in osteotomy fixation,<sup>29</sup> many authors recommend strut graft and cable fixation, cable-plate combination, or screw and plate osteosynthesis to improve stability in fixation.<sup>23,27,30</sup> Moreover, Muratli et al<sup>14</sup> found in their study that there was no difference between the types of osteotomies in terms of stability, but that osteotomy line grafting increased the stability individually.

Our hypothesis is that the graft applied to the osteotomy line is easier to position anterolaterally, and there is no biomechanical difference in terms of stabilization together.

The present study may have some limitations. As the tests were performed in vitro, they do not contain the effects of muscle and ligament structures. Cadaver or finite element analysis studies involving these parameters can be designed for this purpose.

## Conclusion

In the current study, in cases of dysplastic coxarthrosis requiring total hip arthroplasty with shortening, osteotomy methods and graft positions were investigated and compared regarding stability before the consolidation of the bone line in the osteotomy line. We found that different subtrochanteric osteotomy types and graft sites have similar resistance against strength and stability.

As a conclusion, due to lack of superiority among the existing techniques, it is suggested that the preferable method is the one that is the easiest to be performed and in which the surgeon is most experienced.

### Conflicts of Interest

The authors have none to declare.

## References

- 1 Ganey TM, Ogden JA. Pre and postnatal development of the hip. In: Callaghan JJ, Rosenberg AG, Rubash HE, editors. The adult hip. 2nd ed. Philadelphia: Lippincott Williams & Wilkins; 2007:35
- 2 Barrack RL, Newland CC. Uncemented total hip arthroplasty with superior acetabular deficiency. Femoral head autograft technique and early clinical results. *J Arthroplasty* 1990;5(02):159-167
- 3 Steel HH. Triple osteotomy of the innominate bone. *J Bone Joint Surg Am* 1973;55(02):343-350
- 4 Wedge JH, Wasylenko MJ. The natural history of congenital disease of the hip. *J Bone Joint Surg Br* 1979;61-B(03):334-338
- 5 Trousdale RT, Cabanela ME. Lessons learned after more than 250 periacetabular osteotomies. *Acta Orthop Scand* 2003;74(02):119-126
- 6 Charnley J. Anchorage of the femoral head prosthesis to the shaft of the femur. *J Bone Joint Surg Br* 1960;42-B:28-30
- 7 Bobyn JD, Pilliar RM, Cameron HU, Macnab I. Porous surfaced layered prosthetic devices. *J Biomed Eng* 1975;10(04):126-131
- 8 Bonfiglio M, Voke EM. Aseptic necrosis of the femoral head and nonunion of the femoral neck. *J Bone Joint Surg Am* 1968;50(01):48-66
- 9 Crowe JF, Mani VJ, Ranawat CS. Total hip replacement in congenital dislocation and dysplasia of the hip. *J Bone Joint Surg Am* 1979;61(01):15-23
- 10 Doğan A, Zorer G, Ozer UE. [Treatment of acetabular dysplasia by triple pelvic osteotomy and its short-term results]. *Acta Orthop Traumatol Turc* 2007;41(05):355-366
- 11 Tönnis D, Arning A, Bloch M, Heinecke A, Kalchschmidt K. Triple pelvic osteotomy. *J Pediatr Orthop B* 1994;3:54-67
- 12 Ganz R, Klaue K, Vinh TS, Mast JW. A new periacetabular osteotomy for the treatment of hip dysplasias. Technique and preliminary results. *Clin Orthop Relat Res* 1988;(232):26-36
- 13 Akman Ş, Şen C, Şener N, Tözün R. Doğuştan kalça çıkığı ve displazisinde total kalça artroplastisi. *Acta Orthop Traumatol Turc* 2000;34:176-182
- 14 Muratli KS, Karatosun V, Uzun B, Celik S. Subtrochanteric shortening in total hip arthroplasty: biomechanical comparison of four techniques. *J Arthroplasty* 2014;29(04):836-842
- 15 Charnley J, Feagin JA. Low-friction arthroplasty in congenital subluxation of the hip. *Clin Orthop Relat Res* 1973;(91):98-113
- 16 Harris WH. Total hip arthroplasty in the management of the congenital hip dislocation. In: Callaghan JJ, Rosenberg AG, Rubash HE, editors. The adult hip. Philadelphia: Lippincott-Raven; 1988:1651-1682
- 17 Chougale A, Hemmady MV, Hodgkinson JP. Long-term survival of the acetabular component after total hip arthroplasty with cement in patients with developmental dysplasia of the hip. *J Bone Joint Surg Am* 2006;88(01):71-79
- 18 Kiliçoğlu OI, Türker M, Akgül T, Yazicioğlu O. Cementless total hip arthroplasty with modified oblique femoral shortening osteotomy in Crowe type IV congenital hip dislocation. *J Arthroplasty* 2013;28(01):117-125
- 19 Symeonides PP, Pournaras J, Petsatodes G, Christoforides J, Hatzokos I, Pantazis E. Total hip arthroplasty in neglected congenital dislocation of the hip. *Clin Orthop Relat Res* 1997;(341):55-61
- 20 Dunn HK, Hess WE. Total hip reconstruction in chronically dislocated hips. *J Bone Joint Surg Am* 1976;58(06):838-845
- 21 Paavilainen T, Hoikka V, Solonen KA. Cementless total replacement for severely dysplastic or dislocated hips. *J Bone Joint Surg Br* 1990;72(02):205-211
- 22 Paavilainen T, Hoikka V, Paavolainen P. Cementless total hip arthroplasty for congenitally dislocated or dysplastic hips. Technique for replacement with a straight femoral component. *Clin Orthop Relat Res* 1993;(297):71-81
- 23 Togrul E, Ozkan C, Kalaci A, Gülşen M. A new technique of subtrochanteric shortening in total hip replacement for Crowe type 3 to 4 dysplasia of the hip. *J Arthroplasty* 2010;25(03):465-470

- 24 Reikeraas O, Lereim P, Gabor I, Gunderson R, Bjerkreim I. Femoral shortening in total arthroplasty for completely dislocated hips: 3-7 year results in 25 cases. *Acta Orthop Scand* 1996;67(01):33-36
- 25 Davy DT, Kotzar GM, Brown RH, et al. Telemetric force measurements across the hip after total arthroplasty. *J Bone Joint Surg Am* 1988;70(01):45-50
- 26 Lim LA, Carmichael SW, Cabanela ME. Biomechanics of total hip arthroplasty. *Anat Rec* 1999;257(03):110-116
- 27 Bruce WJ, Rizkallah SM, Kwon YM, Goldberg JA, Walsh WR. A new technique of subtrochanteric shortening in total hip arthroplasty: surgical technique and results of 9 cases. *J Arthroplasty* 2000;15(05):617-626
- 28 Sun JY, Wei L. Subtrochanteric shortening with overlapping femoral resection in total hip arthroplasty for Crowe type IV adult dislocation of the hip. *Orthop Surg* 2009;1(03):207-211
- 29 Bernasek TL, Haidukewych GJ, Gustke KA, Hill O, Levering M. Total hip arthroplasty requiring subtrochanteric osteotomy for developmental hip dysplasia: 5- to 14-year results. *J Arthroplasty* 2007;22(06, Suppl 2):145-150
- 30 Götze C, Winkelmann W, Gosheger G, Rödl R. [Is there a need of an additional extramedullary fixation in transverse subtrochanteric shortening in primary total hip arthroplasty for patients with severe hip dysplasia? Short-term experience in seven patients with congenital dislocation]. *Z Orthop Unfall* 2007;145(05):568-573