

# A Rare Cause of Weight Loss in Immunocompetent Subject

Mukesh Nasa<sup>1</sup> Mahesh Gupta<sup>1</sup> Shashank Bhansali<sup>1</sup> Lipika Lipi<sup>2</sup> Rajesh Puri<sup>1</sup>

<sup>1</sup>Medanta Institute of Digestive and Hepatobiliary Sciences, Medanta-The Medicity, Gurgaon, Haryana, India  
<sup>2</sup>Departments of Pathology, Medanta—The Medicity, Gurgaon, Haryana, India

**Address for correspondence** Dr. Mukesh Nasa, DM (Gastroenterology), Medanta Institute of Digestive and Hepatobiliary Sciences, Medanta—The Medicity, Gurgaon, Haryana, India (e-mail: mukeshnasa78@gmail.com).

J Digest Endosc 2019;10:134–135

## Abstract

### Keywords

- ▶ edema
- ▶ *Strongyloides stercoralis*
- ▶ weight loss

We report a case of 61-year-old immunocompetent man with no comorbidity presenting with unexplained weight loss. All routine investigations could not point to the etiology of weight loss, but duodenal biopsy taken on upper gastrointestinal endoscopy revealed larvae of *Strongyloides stercoralis*, a nematode endemic to Indian subcontinent. The patient recovered after course of albendazole, and in the absence of other causality, weight loss was attributed to strongyloidiasis.

## Introduction

*Strongyloides stercoralis*, a nematode, endemic to Indian subcontinent, is known to cause a wide spectrum of disease ranging from fatal hyperinfection syndrome in immunocompromised patients to asymptomatic low-grade infection in immunocompetent population and rare manifestations such as eosinophilic ascites and cervix lesions.<sup>1,2</sup> Diagnosis requires a high index of suspicion. We are describing a case of weight loss due to strongyloidiasis in immunocompetent individuals to sensitize physicians to look for this infection in patients with unexplained weight loss.

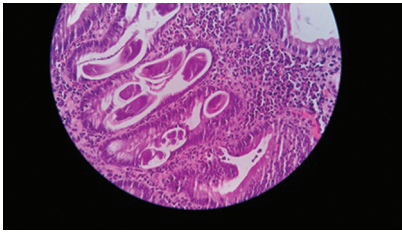
## Case Report

We report a case of a 61-year-old immunocompetent man who presented with a history of reduced appetite and significant unintentional weight loss (6 kg over 6 weeks). There were no symptoms suggestive of other organ system involvement, and no significant medical, social, or family history could be elicited. General and systemic examination did not reveal any significant finding other than pallor and pedal edema. His laboratory investigations showed high total leukocyte counts (13,500/ $\mu$ L) with increased absolute eosinophil count (2,000/ $\mu$ L) and hypoalbuminemia (2 g/dL); normal renal functions (creatinine: 0.8 mg/dL) and serum immunoglobulin (Ig) levels (IgA: 250 mg/dL [81–211 mg/dL], IgG: 1,200 mg/dL [688–1251 mg/dL], and IgM: 120 mg/

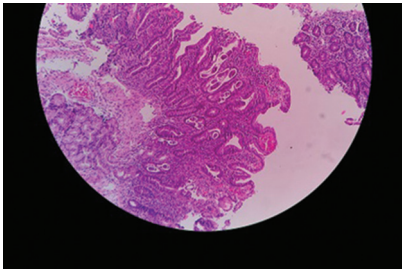
dL [65–132 mg/dL]) were normal apart from raised IgE levels (2,000 IU/mL [150–1000 IU/mL]) and normal thyroid function tests (free T4: 1.8 ng/dL and thyroid-stimulating hormone: 0.9 mIU/mL); serum cortisol levels were normal (14  $\mu$ g/dL), and he was nonreactive for antihuman immunodeficiency virus (HIV)-1 and HIV-2 antibodies. Radiological investigations, namely high-resolution computed tomography of the chest and contrast enhanced computed tomography of the abdomen with enterography were normal. Upper gastrointestinal endoscopy showed edematous duodenal folds and biopsy from the second part of the duodenum showed larvae of *Strongyloides* (▶ **Figs. 1** and **2**). The patient was given oral albendazole (400 mg twice daily) for 7 consecutive days to which he responded by regaining weight and normalization of serum albumin levels and complete blood counts at 4 weeks.

## Discussion

Strongyloidiasis is a parasitic infestation caused by *S. stercoralis* and affects more than 100 million people worldwide.<sup>3</sup> Strongyloidiasis is clinically significant because infection can persist undetected for many years in the untreated host through autoinfection.<sup>3,4</sup> If symptomatic, symptoms are non-specific and highly variable. Infected individuals may present with waxing and waning cutaneous, pulmonary, and gastrointestinal symptoms. The most common cutaneous symptoms are urticaria, localized or generalized pruritus,



**Fig. 1** Haematoxylin and eosin (H&E) stain, duodenal mucosa x100 showing cross and longitudinal sections of *Strongyloides stercoralis*.



**Fig. 2** Haematoxylin and eosin (H&E) stain, duodenal mucosa x40 showing cross-sections of *Strongyloides stercoralis*.

and maculopapular exanthemata or pathognomonic larva currens. Larva currens is an allergic reaction to the migration of filariform larvae in the skin leaving behind itchy urticarial tortuous tracks.<sup>5,6</sup> Migration of larvae into the gastrointestinal tract may present with indigestion, crampy abdominal pain, diarrhea, malabsorption, or rarely weight loss. In immunocompromised host, most commonly HIV patients and post-organ transplant patients, it may disseminate and lead to hyperinfection syndrome with severe watery diarrhea and weight loss and is eventually fatal without proper treatment.

## Conclusion

Strongyloidiasis should be suspected in immunocompetent patients with persistent eosinophilia, pruritus, and abdominal discomfort associated with weight loss and features of malabsorption. All infected patients should be treated even if they are asymptomatic.

### Financial Support and Sponsorship

Nil.

### Conflicts of Interest

None.

## References

- 1 Shukla S, Chauhan R, Wadhwa S, Sehgal S, Singh S. Strongyloides stercoralis hyperinfection causing eosinophilic ascites. *Diagn Cytopathol* 2015;43(9):731–733
- 2 Panda S, Kar A, Das U, Rout N. Cervical strongyloidiasis in an immunocompetent patient: a clinical surprise. *Indian J Pathol Microbiol* 2015;58(3):389–391
- 3 Tiwari S, Rautaraya B, Tripathy KP. Hyperinfection of *Strongyloides stercoralis*. in an immunocompetent patient. *Trop Parasitol* 2012;2(2):135–137
- 4 Valerio L, Roure S, Fernández-Rivas G, et al; North Metropolitan Working Group on Imported Diseases. *Strongyloides stercoralis*, the hidden worm. Epidemiological and clinical characteristics of 70 cases diagnosed in the North Metropolitan Area of Barcelona, Spain, 2003–2012. *Trans R Soc Trop Med Hyg* 2013;107(8):465–470
- 5 Centers for Disease Control, DPDx Parasites and health: Strongyloidiasis. Centers for Disease Control & Prevention;2009;
- 6 Károlyi Z, Erös N, Kriston R. [Cutaneous manifestations of strongyloidosis] *Orv Hetil* 1999;140(4):191–194