

# Closure of Lateral Duodenal Wall Perforation using Over-the-Scope Clip

Vikas Singla<sup>1</sup> Ravi Daswani<sup>1</sup> Shrihari Anil Anikhindi<sup>1</sup> Ashish Kumar<sup>1</sup> Praveen Sharma<sup>1</sup>  
Naresh Bansal<sup>1</sup> Anil Arora<sup>1</sup>

<sup>1</sup>Institute of Liver, Gastroenterology and Pancreaticobiliary Sciences, Sir Ganga Ram Hospital, New Delhi, India

**Address for correspondence** Dr Vikas Singla, DM, Institute of Liver, Gastroenterology and Pancreaticobiliary Sciences, Sir Ganga Ram Hospital, Rajinder Nagar 110 060, New Delhi, India (e-mail: singlavikas1979@gmail.com).

J Digest Endosc 2019;10:130–133

## Abstract

Lateral duodenal wall perforation occurring during endoscopic retrograde cholangiopancreatography (ERCP) due to scope trauma is large and usually treated by surgery. With advances in endoscopic instrumentation, interest in treating these complications using endoscopic devices has increased. Over-the-scope clip (OTSC) which has higher compression force and can approximate large perforations is being increasingly used for the closure of gastrointestinal fistulae and perforations. We recently used OTSC for treating duodenal perforations which occurred during ERCP in two elderly patients. Both these patients had comorbid conditions and were high risk for surgery. Perforations were immediately identified during endoscopy and were closed with OTSC. Both patients had uneventful further course and were discharged successfully. These cases highlight the usefulness of OTSC for the management of endoscopic duodenal perforations.

## Keywords

- ▶ endoscopic retrograde cholangiopancreatography
- ▶ over-the-scope clip
- ▶ perforation

## Introduction

Duodenal perforation is a serious complication, which can occur during endoscopic retrograde cholangiopancreatography (ERCP) and is reported in 0.14 to 0.61% of all ERCP procedures.<sup>1–5</sup> According to the classification given by Stapfer et al, ERCP perforations can be divided into four subgroups.<sup>6</sup> Type I injuries correspond to lateral or medial duodenal wall perforations and mostly occur due to injury due to duodenoscopy; type II injuries are perivaterian and most commonly occur during sphincterotomy or sphincteroplasty; type III injuries are biliary or pancreatic duct injuries due to guide-wire, cannula, or basket; and type IV injuries are the presence of retroperitoneal air alone. Type IV injuries do not require any treatment. While type II and III injuries respond better to nonoperative treatment, type I injuries were conventionally being treated with surgery as they are large and often lead to peritonitis. As most of the elderly patients undergoing ERCP have underlying comorbidities, emergency surgery for management of such perforations is challenging.

With advances in therapeutic endoscopy, interest in endoscopic management of post-ERCP perforation has increased.

Various endoscopic devices such as through-the-scope clips, ligation bands,<sup>7,8</sup> fibrin glue, endoclips and endoloops,<sup>9</sup> suturing devices, and covered luminal stents have been used for the closure of perforation. Most of the existing endoscopic devices are designed for application in small perforations. Closure may not be optimal in most cases, especially with inexperienced operators. Over-the-scope clip (OTSC) device can close large perforations with the higher force of compression and is now being increasingly used to manage duodenal perforations.<sup>10,11</sup> We report our experience with the endoscopic closure of type I duodenal injury with OTSC in two patients.

## Patients and Procedure

Both the ERCPs were performed at a high-volume tertiary care referral endoscopy center performing >1500 ERCPs in a year.

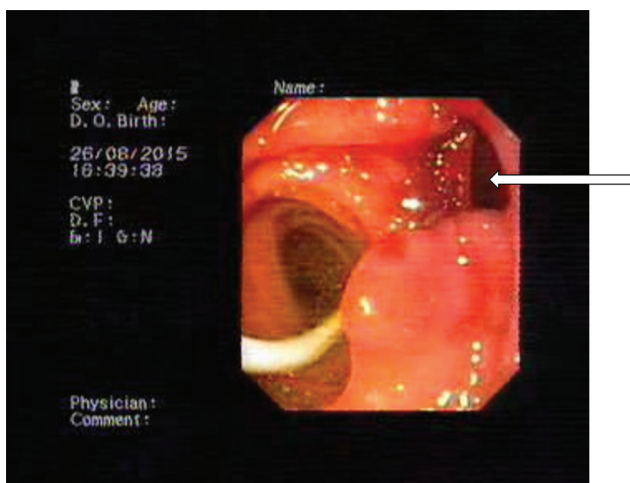
### Patient 1

A 79-year-old patient with the previous history of coronary artery disease, chronic kidney disease, and hypertension presented with right upper quadrant pain of 10-day duration.

Clinical examination revealed tenderness in the right hypochondrium. Liver biochemistry revealed total/direct bilirubin 1.14/0.31 mg/dL (normal 0.2–1.2/0–0.2 mg/dL), aspartate aminotransferase (AST)/alanine aminotransferase (ALT) 31/15 U/L (normal 17–59/21–72 U/L), and alkaline phosphatase (ALP)/gamma-glutamyl transpeptidase (GGT) 63/15 U/L (normal 38–126/15–73 U/L). Total leukocyte count was 9.7 thousands/uL (normal 4–11 thousands/uL), and serum creatinine was 2.7 mg/dL (normal 0.7–1.2 mg/dL). Ultrasound abdomen revealed dilated intrahepatic biliary radicals with multiple common bile duct (CBD) stones, and ERCP was planned.

ERCP was performed in the left lateral decubitus position under conscious sedation with midazolam and pentazocine, and carbon dioxide gas was used for insufflation. The procedure was performed with olympus duodenoscope (TJF-180V, Olympus Corporation, Tokyo, Japan). Papillary orifice was normal, and CBD opening could be cannulated easily with sphincterotome (Ultratome XL, 5 mm Short Nose, Boston scientific, Alajuela, Costa Rica) and 0.032-inch Terumo guidewire (Radiofocus Guidewire M 0.032-inch, 260-cm, Fujinoma, Japan). Sphincterotomy was done for three-fourths part of intramural part of CBD. Cholangiogram revealed multiple filling defects, and stone extraction was done with dormia basket (Grasping Forceps, 22-mm, Aomori, Japan). However, during final CBD clearance with balloon sweep (Boston Scientific Extractor Pro XL, 15 mm, Cork, Ireland), trauma occurred on the lateral duodenal wall. Perforation was immediately suspected due to visualization of a defect in the duodenum and confirmed by the presence of perinephric and subdiaphragmatic air on fluoroscopy. One 10 French × 10-cm straight stent (Cotton-Leung Biliary stent CLSO, Cook Ireland, Limerick, Ireland) was placed in CBD, and duodenoscope was withdrawn. Because of comorbid conditions and elderly age group, surgery was not preferred. Option of closing the perforation with the endoscopic device was discussed with family, and procedure was done with consent.

Endoscopy using a forward-viewing endoscope revealed 10-mm-sized defect in the lateral duodenal wall (►Fig. 1). Endoscope was loaded with the 12-mm OTSC (11-mm,



**Fig. 1** Perforation in the lateral duodenal wall (marked with arrow).

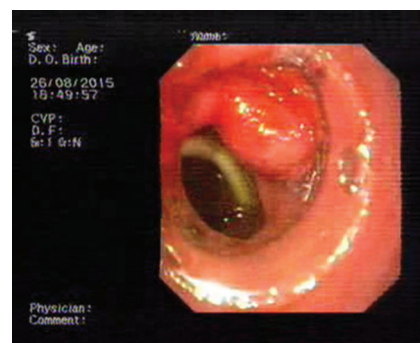
12/6t, OTSC system, Ovesco Endoscopy, Tübingen, Germany) (►Fig. 2). At the perforation site, suction was used to pull the margins inside the cuvette, and clip was deployed ensuring approximation of all the margins (►Fig. 3). Immediate contrast study did not reveal any leak into periduodenal space. A triple-lumen nasojejunal tube (Freka Trelumina 150-cm, Fresenius Kabi, Bad Homburg, Germany) was placed for gastric aspiration and jejunal feeding. The patient was started on IV fluids and antibiotics. Jejunal feeds were started on the third day, and the patient had subsequent uneventful course in the hospital. Computed tomography (CT) scan was done on day 5, which revealed small amount of residual air without any periduodenal collection. The nasojejunal tube was removed, and the patient was discharged two days after the CT scan. The patient has been under follow-up for the past 6 months and is doing well.

### Patient 2

An 84-year-old woman presented right upper quadrant pain for two days without any history of fever. The patient had a history of stroke for which she was taking dabigatran etexilate mesylate and had undergone laparoscopic cholecystectomy for gallbladder stones previously. Examination revealed icterus and tenderness on deep palpation in



**Fig. 2** Over-the-scope clip with rounded teeth loaded on over-the-scope clip applicator cap. The applicator cap has to be mounted on the tip of the endoscope.



**Fig. 3** Complete closure of the lateral duodenal wall perforation with over-the-scope clip.

the right hypochondrium. Laboratory evaluation revealed increased total and direct bilirubin 3.7 (normal 0.2–1.2 mg/dL) and 2.4 mg/dL (normal 0–0.2 mg/dL), respectively, AST/ALT 165/150 IU/L (normal 17–59/21–72 U/L), ALP/GGT 164/268 IU/L (normal 38–126/15–73 U/L), and normal leukocyte count. Ultrasound abdomen showed dilated CBD with multiple calculi (largest measuring 1.6 cm) with intrahepatic biliary radical dilatation. Oral anticoagulant was withheld, and the patient was started on low-molecular-weight heparin (enoxaparin 30 mg subcutaneously twice daily), which was withheld on the day of ERCP.

Similar complication occurred in this patient also lateral duodenal wall injury due to duodenoscope was immediately identified and closed with 12-mm OTSC, and the patient had uneventful further hospital stay, was discharged on day 7, and is under regular follow-up for 4 months.

## Discussion

Lateral duodenal perforation during ERCP is a serious complication. It occurs due to direct trauma by duodenoscope. In our center, which performs around 1,500 ERCP procedures a year, we encountered two such cases in the past 6 months.

Lateral duodenal perforations are diagnosed immediately due to direct visualization of retroperitoneal tissue or visualization of air around the duodenum under fluoroscopy. They are usually large and can lead to peritoneal contamination. Conventionally, these patients were treated by surgical intervention. Surgical procedures included repair with an omental patch, pyloric exclusion, and gastrojejunostomy.

Elderly patients with comorbidities poorly tolerate emergency surgical procedures. Closure with minimally invasive techniques using endoscopic intervention is desirable in these patients. Both of our patients were elderly and had comorbidities, and hence, the endoscopic closure was considered for initial treatment. Endoscopic techniques include through-the-scope clips, covered duodenal stents, band ligation with or without clips, and purse-string closure. All these procedures have limitations. They are useful mostly for closing small perforations, are time consuming, and mostly require special endoscopes, such as double-channel endoscope. Fujishiro et al reported their experience in managing perforations which occurred during endoscopic submucosal dissection in 27 patients. They concluded that perforations <1 cm and clean gastrointestinal contents can be successfully closed with through-the-scope clips by an experienced endoscopist.<sup>12</sup>

Recently, OTSC has been increasingly used for the management of various complications such as fistula, perforation, and gastrointestinal bleed. The efficacy of OTSC is attributable to the ability of the clip to provide full-thickness closure of the perforation. This has been demonstrated in several animal models.<sup>13,14</sup> OTSC is easier to apply, less time-consuming, has higher compression force, and captures a larger tissue volume.<sup>15,16</sup> Haito-Chavez et al<sup>17</sup> reported the outcome of OTSC in 188 patients, of which 48 had perforations (9 patients had duodenal perforations). They reported long-term success rates of 90%. OTSC was more successful if used as primary modality of repair, rather than for rescue

treatment. OTSC has been used previously for duodenal perforation,<sup>10,11</sup> occurring during ERCP. Donatelli et al reported the use of combined colonic and gastric OTSC for the closure of large duodenal perforations.<sup>10</sup> Buffoli et al reported the use of OTSC for the closure of jejunal perforation occurring during ERCP in a patient with altered anatomy.<sup>11</sup> Suction or twin graspers have been used with OTSC to approximate the margins. Because we applied the clip immediately after perforation, the margins were soft and nonfibrotic, and approximation with suction was successful. In our both patients, primary closure of perforation could be achieved without any long-term complications.

In summary, OTSC is an effective modality in patients with lateral duodenal wall perforation and should be considered, especially in patients with comorbid conditions.

## Financial Support and Sponsorship

Nil.

## Conflicts of Interest

None.

## References

- Jin YJ, Jeong S, Kim JH, et al. Clinical course and proposed treatment strategy for ERCP-related duodenal perforation: a multicenter analysis. *Endoscopy* 2013;45(10):806–812
- Morgan KA, Fontenot BB, Ruddy JM, Mickey S, Adams DB. Endoscopic retrograde cholangiopancreatography gut perforations: when to wait! When to operate! *Am Surg* 2009;75(6):477–483, discussion 483–484
- Fatima J, Baron TH, Topazian MD, et al. Pancreaticobiliary and duodenal perforations after periampullary endoscopic procedures: diagnosis and management. *Arch Surg* 2007;142(5):448–454
- Cotton PB, Garrow DA, Gallagher J, Romagnuolo J. Risk factors for complications after ERCP: a multivariate analysis of 11,497 procedures over 12 years. *Gastrointest Endosc* 2009;70(1):80–88
- Kim BS, Kim IG, Ryu BY, et al. Management of endoscopic retrograde cholangiopancreatography-related perforations. *J Korean Surg Soc* 2011;81(3):195–204
- Stapfer M, Selby RR, Stain SC, et al. Management of duodenal perforation after endoscopic retrograde cholangiopancreatography and sphincterotomy. *Ann Surg* 2000;232(2):191–198
- Han JH, Lee TH, Jung Y, et al. Rescue endoscopic band ligation of iatrogenic gastric perforations following failed endoclip closure. *World J Gastroenterol* 2013;19(6):955–959
- Li Y, Han Z, Zhang W, et al. Successful closure of lateral duodenal perforation by endoscopic band ligation after endoscopic clipping failure. *Am J Gastroenterol* 2014;109(2):293–295
- Nakagawa Y, Nagai T, Soma W, et al. Endoscopic closure of a large ERCP-related lateral duodenal perforation by using endoloops and endoclips. *Gastrointest Endosc* 2010;72(1):216–217
- Donatelli G, Dumont JL, Vergeau BM, et al. Colic and gastric over-the-scope clip (Ovesco) for the treatment of a large duodenal perforation during endoscopic retrograde cholangiopancreatography. *Therap Adv Gastroenterol* 2014;7(6):282–284
- Buffoli F, Grassia R, Iiritano E, Bianchi G, Dizioli P, Staiano T. Endoscopic “retroperitoneal fatpexy” of a large ERCP-related jejunal perforation by using a new over-the-scope clip device in Billroth II anatomy (with video) *Gastrointest Endosc* 2012;75(5):1115–1117

- 12 Fujishiro M, Yahagi N, Kakushima N, et al. Successful nonsurgical management of perforation complicating endoscopic submucosal dissection of gastrointestinal epithelial neoplasms. *Endoscopy* 2006;38(10):1001–1006
- 13 Matthes K, Jung Y, Kato M, Gromski MA, Chuttani R. Efficacy of full-thickness GI perforation closure with a novel over-the-scope clip application device: an animal study. *Gastrointest Endosc* 2011;74(6):1369–1375
- 14 Schurr MO, Hartmann C, Ho CN, Fleisch C, Kirschniak A. An over-the-scope clip (OTSC) system for closure of iatrogenic colon perforations: results of an experimental survival study in pigs. *Endoscopy* 2008;40(7):584–588
- 15 Banerjee S, Barth BA, Bhat YM, et al; ASGE Technology Committee. Endoscopic closure devices. *Gastrointest Endosc* 2012;76(2):244–251
- 16 von Renteln D, Vassiliou MC, Rothstein RI. Randomized controlled trial comparing endoscopic clips and over-the-scope clips for closure of natural orifice transluminal endoscopic surgery gastrotomies. *Endoscopy* 2009;41(12):1056–1061
- 17 Haito-Chavez Y, Law JK, Kratt T, et al. International multicenter experience with an over-the-scope clipping device for endoscopic management of GI defects (with video) *Gastrointest Endosc* 2014;80(4):610–622