


How do Orthopedic Surgeons Manage Displaced Femoral Neck Fracture in the Middle-Aged Patient? Brazilian Survey of 78 Orthopaedic Surgeons*

Como os cirurgiões ortopédicos tratam a fratura desviada do colo do fêmur no paciente de meia-idade? Pesquisa brasileira com 78 cirurgiões ortopédicos

Vincenzo Giordano^{1,2}  Marcos Giordano³ Rodrigo Aquino¹ João Otávio Grossi¹ Hudson Senna¹ Hilton Augusto Koch⁴

¹Prof. Nova Monteiro Service of Orthopedics and Traumatology, Hospital Municipal Miguel Couto, Rio de Janeiro, RJ, Brazil

²Clínica São Vicente, Rio de Janeiro, RJ, Brazil

³Traumatology and Orthopedics Service, Hospital de Força Aérea do Galeão, Rio de Janeiro, RJ, Brazil

⁴Department of Radiology, Universidade Federal do Rio de Janeiro, Rio de Janeiro, RJ, Brazil

Address for correspondence Vincenzo Giordano, Clínica São Vicente, Rua João Borges 204, Gávea, Rio de Janeiro, RJ, 22451-100, Brazil (e-mail: v_giordano@me.com).

Rev Bras Ortop 2019;54:288–294.

Abstract

Objective The aim of the present study was to evaluate the practices and preferences of Brazilian orthopedic surgeons for the treatment of femoral neck fractures in middle-aged patients.

Methods A survey containing 10 images of femoral neck fractures was sent to a group of 100 orthopedic surgeons, all of them members of the Brazilian Society of Orthopedics and Traumatology. The questionnaire asked the treatment option for cases of nondisplaced and displaced fractures of the femoral neck in middle-aged patients, that is, those between 50 and 69 years old. Descriptive and inferential statistical analyzes were performed using the chi-squared (χ^2) and the Fisher exact tests. The level of significance was 5%.


Results The survey was answered by 78% of the orthopedic surgeons invited to participate in the study. There was no significant difference in the treatment method distribution between generalists and specialists ($p = 0.16$) in the sample of nondisplaced femoral neck fractures. There was a highly significant difference in the treatment method distribution between generalists and specialists ($p < 0.0001$) in the sample of displaced fractures of the femoral neck.

Conclusion Preservation of the femoral head through multiple cannulated screws fixation is the treatment of choice for nondisplaced femoral neck fractures for both

Keywords

- ▶ femur
- ▶ femoral neck fractures
- ▶ bone screws
- ▶ arthroplasty

* Work developed at the Serviço de Ortopedia e Traumatologia Prof. Nova Monteiro, Hospital Municipal Miguel Couto, Rio de Janeiro, RJ, Brasil.

 Vincenzo Giordano's ORCID is <https://orcid.org/0000-0002-4429-312X>.

Introduction

Approximately half of the fractures occurring at the proximal end of the femur are located in the neck region.^{1,2} These fractures are historically associated almost exclusively with

generalists and specialists. Low chronological and/or physiological age are the main factors for this decision-making. In displaced femoral neck fractures, femoral head replacement is preferred for both groups of orthopedists (generalists and specialists). In this situation, specialists prefer total hip arthroplasty (THA), whereas generalists favor partial hip arthroplasty (PHA).

Resumo

Objetivo O objetivo do presente estudo foi avaliar as práticas e preferências dos cirurgiões ortopédicos brasileiros para o tratamento da fratura do colo do fêmur no paciente de meia-idade.

Métodos Foi elaborado um questionário contendo 10 imagens de fraturas do colo do fêmur, o qual foi enviado a um grupo de 100 ortopedistas, todos membros titulares da Sociedade Brasileira de Ortopedia e Traumatologia. No questionário, foi perguntada a opção de tratamento para casos de fratura não desviada e desviada do colo do fêmur em pacientes de meia-idade, caracterizados com aqueles com idade entre 50 e 69 anos. Foram realizadas análises estatísticas descritiva e inferencial, pelos testes de qui-quadrado (χ^2) e exato de Fisher. O critério de determinação de significância adotado foi o nível de 5%.

Resultados O questionário foi respondido por 78% dos ortopedistas convidados a participar do estudo. Observou-se que não existe diferença significativa na distribuição do método de tratamento entre as avaliações de generalistas e de especialistas ($p = 0,16$) na amostra de fraturas não desviadas do colo do fêmur. Observou-se que existe diferença altamente significativa na distribuição do método de tratamento entre as avaliações de generalistas e especialistas ($p < 0,0001$) na amostra de fraturas desviadas do colo do fêmur.

Conclusão A preservação da cabeça femoral por meio da fixação com múltiplos parafusos canulados é o tratamento de escolha para as fraturas não desviadas do colo do fêmur, tanto para os generalistas quanto para os especialistas. Idade cronológica e/ou fisiológica baixas são os principais fatores para esta tomada de decisão. Nos casos em que a fratura do colo do fêmur encontra-se desviada, a substituição da cabeça femoral é a preferência para os dois grupos de ortopedistas (generalistas e especialistas). Nesta situação, os especialistas preferem a artroplastia total do quadril (ATQ), e os generalistas a artroplastia parcial do quadril (APQ).

Palavras-chave

- ▶ fêmur
- ▶ fraturas do colo femoral
- ▶ parafusos ósseos
- ▶ artroplastia

elderly patients, often resulting from banal falls; however, due to the current populational aging and urban growth rate, femoral fractures are observed after several types of trauma in patients from all age groups.^{1,3-5}

All of the current therapeutic approaches are aimed at restoring the mobility of the patient as early as possible, preferably at the preoperative level, either through preservation (osteosynthesis) or replacement (arthroplasty) of the femoral head. In young adult patients (< 50 years old), there is no doubt that osteosynthesis should always be the 1st option, while in the elderly (> 65 years old), arthroplasty should be preferred.^{3,4} The problem arises for middle-aged patients (between 50 and 65 years old), for whom the therapeutic indication is intensely discussed and controversial, and should be individually defined for each patient.

In this age group, numerous factors contribute to warrant the decision between internal fixation of the displaced fracture or primary prosthetic replacement of the femoral neck in the acute phase.³ It now seems well understood that

more important than objective criteria, such as chronological age, the therapeutic choice is defined by functional parameters that further value the general health status, bone quality, cognitive status, and life expectancy of the patient.⁶ Subjective aspects, such as variations in patient demographics, treatment methods, and other local cultural aspects from different countries, have been increasingly valued and should be considered in the decision-making process.

The present study aimed to evaluate the practices and preferences of Brazilian orthopedic surgeons for the treatment of femoral neck fractures in middle-aged patients. The results of the research will help to understand how these surgeons make their therapeutic decisions and which factors are perceived as important in their choice.

Methods

A questionnaire containing radiographic images of 10 displaced femoral neck fractures was developed and the participants

were asked to select their treatment option (osteosynthesis or arthroplasty) and to indicate the main reason for their decision. Osteosynthesis options included (1) cannulated screws (in situ fixation), (2) cannulated screws (closed reduction), (3) cannulated screws (open reduction), and (4) fixed-angle side plate. Arthroplasty options included (1) partial hip arthroplasty (PHA) and (2) total hip arthroplasty (THA).

The radiographs were randomly selected from the hospital files, with no identification of the patient, of his/her hospital records or of any medical record data. The complete images were separated, including a panoramic hip radiograph in anteroposterior (AP) view and in AP and lateral incidences of the fractured hips. The fractures were previously classified by two active members of the Brazilian Society of Orthopedics and Traumatology (SBOT, in the Portuguese acronym) as nondisplaced or displaced, according to the Garden classification. In case of disagreement, the opinion of a third expert would be asked, but this was not required. Four nondisplaced fractures (Garden I and II) and six displaced fractures (Garden III and IV) were included. The choice of fracture types was aimed at evaluating whether, in this age group, the initial fracture displacement aspect would have relevance in the decision-making process.

The radiographs were photographed and their grayscale was adjusted in a computer program (Grayscale Image Converter - <https://www.dcode.fr/grayscale-image>). Next, the images were assembled in sequence, including AP panoramic, AP and lateral views of the fractured hip (►Fig. 1). The cases were numbered from 1 to 10, and the clinical history, with the age and comorbidities of the patient, was elaborated by the senior author. Ages chosen to characterize middle-aged patients ranged from 50 to 69 years old. This methodology was followed so that there was no risk of patient identification from their images used in the present study.

The link with the questionnaire containing the 10 clinical cases was e-mailed to 50 orthopedists who are members of the Brazilian Hip Society (SBQ, in the Portuguese acronym) – so-called specialists – and to 50 orthopedists who are members of the SBOT, who regularly perform surgeries for this type of fracture – so-called generalists. SurveyMonkey (SurveyMonkey, San Mateo, CA, USA) was used as an online platform.

Descriptive statistical analysis of the data expressed as frequency (*n*) and percentage (%), and graphical distribution

were performed to illustrate the differences between the types of evaluators (surgeons). An inferential statistical analysis was performed using the chi-squared (χ^2) and the Fisher exact tests to verify the association between the treatment method (six types) and the type of evaluator (generalist or specialist). The significance criterion adopted was the level of 5%. The statistical analysis was performed using the statistical software SAS System, version 6.11 (SAS Institute, Inc., Cary, NC, USA).

Results

Out of the 100 questionnaires sent, 78 were answered. Of these, 33 (66%) were from the generalists group, and 45 (90%) were from the specialists group.

There was no significant difference in the treatment method distribution between the evaluations by generalists and specialists ($p = 0.16$) in the subsample of nondisplaced fractures of the femoral neck. Among the generalists, 62.1% preferred to fix the femoral neck fracture with cannulated screws in situ or following a closed reduction maneuver. Among the specialists, 69.0% preferred to fix the femoral neck fracture with cannulated screws in situ or following a closed reduction maneuver. In the generalists group, 27.3% indicated the replacement of the femoral head, 9.1% preferred PHA, and 18.2% favored THA, whereas, in the specialists group, 19.4% indicated femoral head replacement, with 2.2% preferring PHA, and 17.2% favoring THA. The complete data set is shown in ►Fig. 2 and in ►Table 1.

There was a highly significant difference in the treatment method distribution between generalists and specialists ($p < 0.0001$) in the subsample of displaced fractures of the femoral neck. Specialists favored THAs (56.7%) compared with generalists (38.9%). On the other hand, more generalists preferred PHA (23.7%) compared with specialists (8.5%). Femoral head preservation (osteosynthesis) was preferred by 37.4% of the generalists and by 34.9% of the specialists, and fixation with cannulated screws following a closed reduction was the most chosen option (20.7% for generalists and 16.7% for specialists). The complete data set is shown in ►Fig. 3 and in ►Table 2.

Similarly, there was a highly significant difference in the treatment method distribution between generalists and specialists ($p < 0.0001$) in the femoral neck fracture subsample, regardless of the displacement. The preservation of the

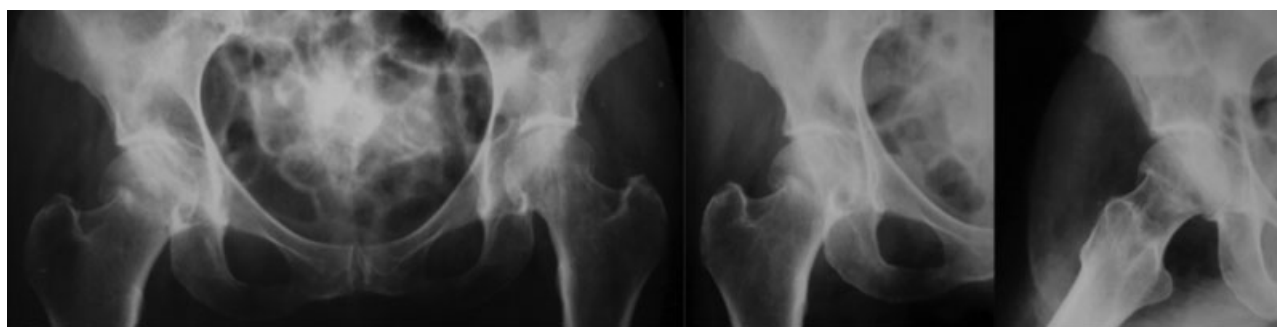


Fig. 1 Images from Case 6. Note the sequential arrangement of the radiographs of a nondisplaced fracture at the right femoral neck. In the clinical history set up by the senior author, this patient was identified as M. G. A., female, 64 years old, who walked only at home and suffered a fall from the 3rd step of a masonry stairway 2 days before. She was also a smoker and presented (controlled) bipolar disorder.

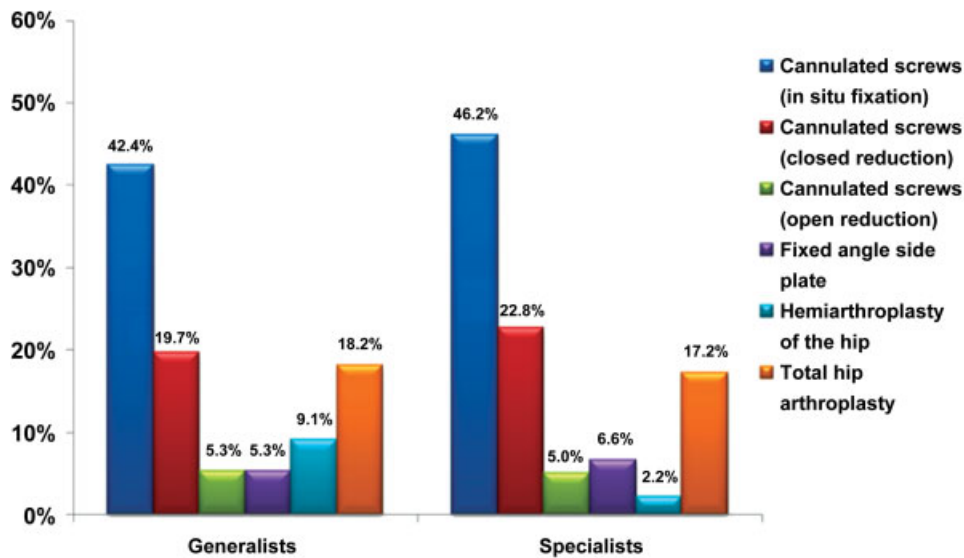


Fig. 2 Fixation method according to the type of evaluator (surgeon) in the subsample of nondisplaced femoral neck fractures ($p = 0.16$).

Table 1 Fixation method according to the evaluator in the subsample of nondisplaced femoral neck fractures

Fixation method	Evaluations by generalists		Evaluations by specialists		p -value
Cannulated screws (in situ fixation)	56	42.4%	83	46.2%	0.16
Cannulated screws (closed reduction)	26	19.7%	41	22.8%	
Cannulated screws (open reduction)	7	5.3%	9	5.0%	
Fixed angle side plate	7	5.3%	12	6.6%	
Hemiarthroplasty of the hip	12	9.1%	4	2.2%	
Total hip arthroplasty	24	18.2%	31	17.2%	

Source: SOT, 2017. Chi-squared test.

femoral head was chosen by the specialists in 51.4% of the cases, with a predominance of cannulated screws in situ (21.2%), or following a closed reduction (20.3%). The specialists preferred to preserve the femoral head in 53.1% of the cases, with 19.1% favoring cannulated screws in situ, and 19.1% indicating the use of cannulated screws following a closed reduction. The replacement of the femoral head was chosen by 48.6% of the generalists and by 46.9% of the specialists. In the choice of arthroplasty, more specialists tended to perform THA (40.9%) than generalists (30.6%). On the other hand, more generalists tended to perform PHA (18%) than specialists (6.0%). These data are fully illustrated in ► Fig. 4 and are shown in ► Table 3.

Discussion

The treatment of femoral neck fracture in middle-aged patients continues to be controversial among orthopedists, with several algorithms described in the literature, including the one proposed by the SBQ.^{7,8} The complex biomechanics of hip-acting forces, the vascular vulnerability of the femoral head, and the existence of some degree of bone loss make this age group a therapeutic challenge, fueling the controversy and leaving a big question mark for the surgeon treating these

lesions. If the preservation of the femoral head is an option, anatomical reduction and stable internal fixation are very important. On the other hand, if the option is for replacement, the optimization of medical comorbidities and the surgical execution with minimum delay are fundamental.⁹

In the present study, femoral head preservation is the treatment of choice for nondisplaced fractures of the femoral neck for both generalists and specialists, especially in patients with low chronological and/or physiological age. Although no difference in treatment outcome was demonstrated using multiple cannulated screws, fixed-angle plate or sliding hip screw (with or without antirotational screw), there was a clear preference for cannulated screws in both groups (67.4% of generalists and 74.0% of specialists).¹⁰ We believe that this finding is justified by the lower degree of surgical invasiveness of the procedure, with lower blood loss and morbidity.^{11,12} There was no statistical difference between the treatment method chosen by the 2 groups of orthopedists ($p = 0.16$).

Primary femoral head replacement was preferred by 27.3% of the generalists and by 19.4% of the specialists in nondisplaced femoral neck fractures, perhaps because they considered that some patients included in the questionnaire presented low functional demand and poor health conditions, which are factors that contribute to the indication of

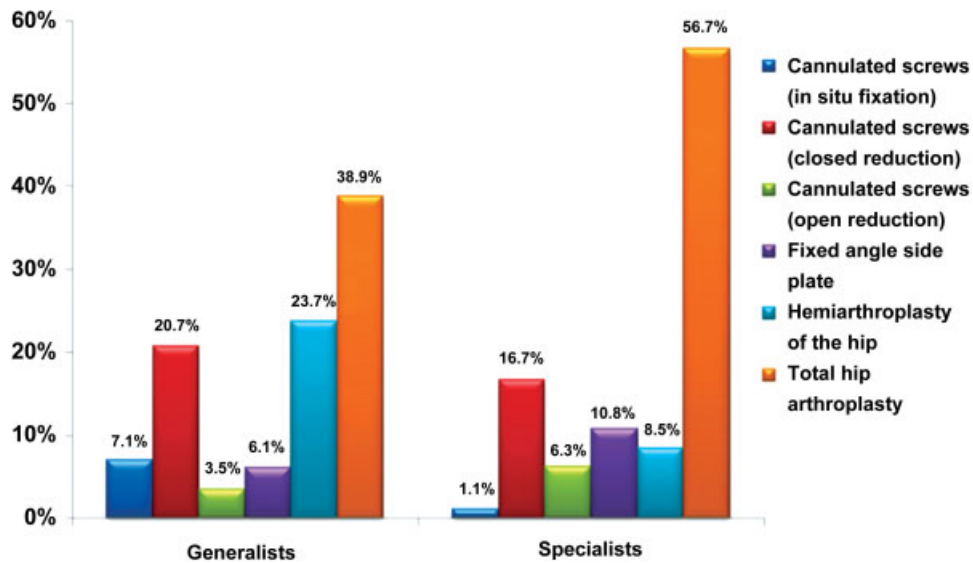


Fig. 3 Fixation method according to the type of evaluator (surgeon) in the subsample of displaced femoral neck fractures ($p < 0.0001$).

Table 2 Fixation method according to the evaluator in the subsample of displaced femoral neck fractures

Fixation method	Evaluations by generalists		Evaluations by specialists		p-value
	Count	Percentage	Count	Percentage	
Cannulated screws (in situ fixation)	14	7.1%	3	1.1%	< 0.0001
Cannulated screws (closed reduction)	41	20.7%	45	16.7%	
Cannulated screws (open reduction)	7	3.5%	17	6.3%	
Fixed angle side plate	12	6.1%	29	10.8%	
Hemiarthroplasty of the hip	47	23.7%	23	8.5%	
Total hip arthroplasty	77	38.9%	153	56.7%	

Source: SOT, 2017. Chi-squared test.

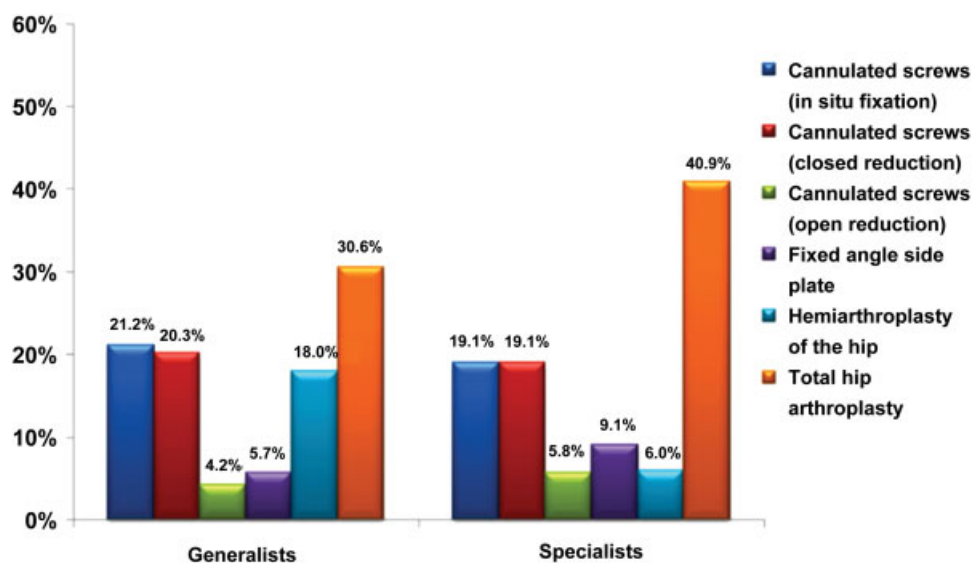


Fig. 4 Fixation method according to the type of evaluator (surgeon) in the subsample of femoral neck fractures regardless of the initial displacement ($p < 0.0001$).

Table 3 Fixation method according to the evaluator in the subsample of femoral neck fracture regardless of displacement (total)

Fixation method	Evaluations by generalists		Evaluations by specialists		<i>p</i> -value
	Number	Percentage	Number	Percentage	
Cannulated screws (in situ fixation)	70	21.2%	86	19.1%	< 0.0001
Cannulated screws (closed reduction)	67	20.3%	86	19.1%	
Cannulated screws (open reduction)	14	4.2%	26	5.8%	
Fixed angle side plate	19	5.7%	41	9.1%	
Hemiarthroplasty of the hip	59	18.0%	27	6.0%	
Total hip arthroplasty	101	30.6%	184	40.9%	

Source: SOT, 2017. Chi-squared test.

arthroplasty.^{3,13} Swart et al,⁵ using the Markov economic decision-making analytical model, concluded that middle-aged patients with several medical comorbidities present a higher risk of fixation failure, and, therefore, a primary arthroplasty would be advisable.

In displaced femoral neck fractures, femoral head replacement was preferred by both groups of orthopedists (62.6% of generalists and 65.2% of specialists). There was a statistically significant difference between these 2 groups regarding the type of joint replacement, whether partial or total ($p < 0.0001$). While 56.7% of the specialists opted for THA, only 38.9% of the generalists chose this type of procedure. On the other hand, 23.7% of the generalists preferred PHA, against 8.5% of the specialists. This finding was very relevant in characterizing the training and continuing medical education of hip surgery specialists, as recent studies have shown that THA is superior to PHA in the treatment of displaced femoral neck fractures.^{14–16} Macaulay et al,¹⁴ in a comparative prospective randomized study including 40 patients with displaced femoral neck fractures, found that those submitted to THA had significantly less pain and better functional scores. Yu et al¹⁵ performed a meta-analysis of 12 randomized controlled trials (1,320 patients) comparing the results of THA and PHA in the treatment of displaced femoral neck fractures, and observed that the former had a lower risk of reoperation (relative risk [RR] = 53) and a higher Harris Hip Score after 1 year.

As in nondisplaced fractures, when osteosynthesis was indicated for the treatment of displaced femoral neck fractures, multiple cannulated screws were preferred by the participants (31.3% of the generalists and 24.1% of the specialists). Swart et al⁵ demonstrated the cost-effectiveness of femoral head preservation in this middle-aged group with displaced fractures, provided that some prerequisites are fulfilled. The success rate of osteosynthesis depends on factors related to the patient (mechanism of injury and comorbidities), to the surgeon (surgical training), and to the hospital environment (surgical facilities).⁵

The present study had some limitations. The 1st was the small number of participants, which may be questioned when extrapolating our results as a preference for orthopedists across the country. However, 78% of the participants who were invited to participate answered the question-

naire, which seems to be representative of the others who did not answer it.¹⁷ With the number of responses received, a sampling error of ~ 3% was observed, with a 95% confidence level. Another limitation was the lack of information on the characteristics desired in an arthroplasty, such as type of fixation to the host bone and tribological pair (in THA), although these data did not interfere in the identification of the preference of generalist or specialist orthopedists as to the preservation or not of the femoral head. In the context of a larger epidemiological study, involving more detailed clinical situations, this information could be better explored.

Conclusion

The preservation of the femoral head by multiple cannulated screws fixation is the treatment of choice for nondisplaced femoral neck fractures for both generalists and specialists. Low chronological and/or physiological age are the main factors in this decision-making process. In cases in which the femoral neck fracture is displaced, femoral head replacement is preferred by both groups of orthopedists (generalists and specialists). In this situation, specialists prefer THA, and generalists favor PHA ($p < 0.0001$).

Conflicts of interests

The authors have no conflicts of interests to declare.

References

- 1 Pauyo T, Drager J, Albers A, Harvey EJ. Management of femoral neck fractures in the young patient: A critical analysis review. *World J Orthop* 2014;5(03):204–217
- 2 Raaymakers EL. Fractures of the femoral neck: a review and personal statement. *Acta Chir Orthop Traumatol Cech* 2006;73(01):45–59
- 3 Haidukewych GJ. Femoral neck fractures: in the bucket or on top of the neck? *Semin Arthroplasty* 2010;21(01):5–8
- 4 Sendtner E, Renkawitz T, Kramny P, Wenzl M, Grifka J. Fractured neck of femur—internal fixation versus arthroplasty. *Dtsch Arztebl Int* 2010;107(23):401–407
- 5 Swart E, Roulette P, Leas D, Bozic KJ, Karunakar M. ORIF or arthroplasty for displaced femoral neck fractures in patients younger than 65 years old. An economic decision analysis. *J Bone Joint Surg Am* 2017;99(01):65–75
- 6 Su EP, Su SL. Femoral neck fractures: a changing paradigm. *Bone Joint J* 2014;96-B(11, Supple A)43–47

- 7 Consenso no tratamento das fraturas do colo femoral [accessed in 28 Sept, 2017]. Available at: <http://app.sbquadril.org.br/consensos.php?ver=2>
- 8 Palm H, Krashennikoff M, Holck K, Lemser T, Foss NB, Jacobsen S, et al. A new algorithm for hip fracture surgery. Reoperation rate reduced from 18 % to 12 % in 2,000 consecutive patients followed for 1 year. *Acta Orthop* 2012;83(01):26–30
- 9 Forsh DA, Ferguson TA. Contemporary management of femoral neck fractures: the young and the old. *Curr Rev Musculoskelet Med* 2012;5(03):214–221
- 10 Parker MJ, Blundell C. Choice of implant for internal fixation of femoral neck fractures. Meta-analysis of 25 randomised trials including 4,925 patients. *Acta Orthop Scand* 1998;69(02):138–143
- 11 Lee YS, Chen SH, Tsuang YH, Huang HL, Lo TY, Huang CR. Internal fixation of undisplaced femoral neck fractures in the elderly: a retrospective comparison of fixation methods. *J Trauma* 2008;64(01):155–162
- 12 Parker MJ, White A, Boyle A. Fixation versus hemiarthroplasty for undisplaced intracapsular hip fractures. *Injury* 2008;39(07):791–795
- 13 Rogmark C, Carlsson A, Johnell O, Sernbo I. A prospective randomised trial of internal fixation versus arthroplasty for displaced fractures of the neck of the femur. Functional outcome for 450 patients at two years. *J Bone Joint Surg Br* 2002;84(02):183–188
- 14 Macaulay W, Nellans KW, Garvin KL, Iorio R, Healy WL, Rosenwasser MP; other members of the DFACTO Consortium. Prospective randomized clinical trial comparing hemiarthroplasty to total hip arthroplasty in the treatment of displaced femoral neck fractures: winner of the Dorr Award. *J Arthroplasty* 2008;23(06, Suppl 1):2–8
- 15 Yu L, Wang Y, Chen J. Total hip arthroplasty versus hemiarthroplasty for displaced femoral neck fractures: meta-analysis of randomized trials. *Clin Orthop Relat Res* 2012;470(08):2235–2243
- 16 Zi-Sheng A, You-Shui G, Zhi-Zhen J, Ting Y, Chang-Qing Z. Hemiarthroplasty vs primary total hip arthroplasty for displaced fractures of the femoral neck in the elderly: a meta-analysis. *J Arthroplasty* 2012;27(04):583–590
- 17 Nulty DD. The adequacy of response rates to online and paper surveys: what can be done? *Assess Eval High Educ* 2008;33(03):301–314