

# Clinical and Radiological Evaluation of Patients Undergoing Distal Radio Osteosynthesis with Locking Plate—Retrospective Study\*

## *Avaliação clínica e radiológica dos pacientes submetidos a osteossíntese de rádio distal com placas bloqueadas – estudo retrospectivo*

Jurandyr de Abreu Câmara Filho<sup>1</sup> Saulo Fontes Almeida<sup>1</sup>

<sup>1</sup> Clinical Service of Orthopedics and Traumatology, Hospital Naval Marcílio Dias, Rio de Janeiro, RJ, Brazil

Address for correspondence Jurandyr de Abreu Câmara Filho, PhD, Rua Petrolândia 480 Vista Alegre, Rio de Janeiro, RJ, CEP: 21230-720, Brazil (e-mail: jurandyrabreu@id.uff.br).

Rev Bras Ortop 2019;54:303–308.

### Abstract

**Objective** The objective of the present work was to perform a retrospective study based on the medical files and radiographs of the patients, as well as on the socio-economic data of the patients submitted to distal radio osteosynthesis with locking plates, evaluating them clinically and radiographically.

**Methods** The postoperative period was evaluated clinically and radiologically in the orthopedics and traumatology clinic service of our hospital between 2016 and 2017.

**Results** In the radiographic evaluation, we found 22 (75.86%) excellent results, 6 (20.69%) good results, and 1 (3.45%) regular result. In the clinical evaluation, the ulnar deviation obtained a mean of 28.40, a standard deviation (SD) of 3.0 and a coefficient of variation of 10.56%. The radial deviations averaged 22.93, with a SD of 2.2 and a coefficient of variation of 9.59%. The range of motion in flexion obtained a mean of 59.43, a SD of 9.86 and a coefficient of variation of 16.59%. The extension obtained a mean of 53.83, a SD of 5.09 and a coefficient of variation of 9.46%.

**Conclusion** We have concluded that there is statistical correlation between clinical and radiographic data, and that the locking plate is a treatment method with a high success rate in the surgical procedure of distal radius fractures.

### Keywords

- ▶ fractures, bone
- ▶ radius fractures
- ▶ internal fracture fixation
- ▶ retrospective studies

### Resumo

**Objetivo** O objetivo do presente trabalho foi realizar um estudo retrospectivo com base no arquivo médico dos prontuários e das radiografias dos pacientes, assim como em seus dados socioeconômicos, avaliando clínica e radiograficamente as informações dos pacientes submetidos a osteossíntese de rádio distal com placas bloqueadas.

**Métodos** Avaliou-se clinicamente e radiologicamente o pós-operatório no serviço da clínica de ortopedia e traumatologia do nosso hospital entre os anos de 2016 e 2017.

\* Work performed at the Hospital Naval Marcílio Dias, Rio de Janeiro, RJ, Brazil.

**Palavras-chave**

- ▶ fraturas ósseas
- ▶ fraturas do rádio
- ▶ fixação interna de fraturas
- ▶ estudos retrospectivos

**Resultados** Durante a avaliação radiográfica, encontramos 22 (75,86%) resultados excelentes, 6 (20,69%) bons e 1 (3,45%) regular. Na avaliação clínica, o desvio ulnar obteve média de 28,40, desvio padrão (DP) de 3,0 e coeficiente de variação de 10,56%. O desvio radial obteve média de 22,93, DP de 2,2 e coeficiente de variação de 9,59%. A amplitude de movimento em flexão obteve média de 59,43, DP de 9,86 e coeficiente de variação de 16,59%. Já a extensão obteve média de 53,83, DP de 5,09 e coeficiente de variação de 9,46%.

**Conclusão** Concluímos que há correlação estatística entre os dados clínicos e radiográficos, e que a placa bloqueada é um método de tratamento com alto índice de sucesso no procedimento cirúrgico das fraturas de rádio distal.

**Introduction**

Distal radial fractures are frequent lesions, accounting for 10 to 12% of human skeletal fractures. Most occur after low energy trauma, such as falling from own height, and are related to bone density loss (osteoporosis).<sup>1</sup>

In young patients, on the other hand, these fractures are associated with high energy traumas, such as traffic accidents, sports accidents and falls from height.

The literature does not mention a single treatment method that is effective for all types of distal radial fractures.<sup>2,3</sup>

Described treatment modalities include plaster immobilization, percutaneous placement of intrafocal, extrafocal or intramedullary Kirschner wires, dorsal and volar plates and external fixation.<sup>4,5</sup>

Recent developments in implants and techniques, such as locking plates, have changed the orthopedic treatment of these fractures. The locking plate and screw systems act as a unit for fracture fixation, unlike conventional plates that require compression between the implant and the bone for stabilization. In elderly patients, who have a lower bone density, these systems provide greater stiffness and better stabilization than the conventional plates. In addition, the locking plate-screw mechanism functions as a substitute for cortical bone, allowing the use of monocortical screws.<sup>6</sup>

The stable internal fixation has advantages, including early mobilization of the wrist and fingers, facilitating post-operative rehabilitation and decreasing the stiffness due to the immobilization period.<sup>7</sup>

Biomechanical studies demonstrate that locking plates provide greater stability of fixed fractures than unlocking, dorsal or volar plates. Volar plates have the advantage of a lower incidence of complications related to the extensor tendons when compared to dorsal plates.<sup>8</sup>

The aim of surgical treatment of unstable distal radial fractures is anatomic reduction and a better functional recovery of the patient.<sup>9,10</sup> However, studies show no correlation between restoration of volar inclination, radial length, and radial inclination with better subjective functional outcomes of patients treated with plaster immobilization or Kirschner wires.<sup>9</sup> The relationship of these radiographic measurements with the range of motion recovery is controversial.

Radial length and volar angulation are the features most cited as responsible for repercussions on the wrist movement of patients treated for distal radial fractures.<sup>10</sup>

Our objective was to perform a retrospective study based on medical records and radiographs, evaluating socioeconomic, clinical and radiographic data from patients submitted to distal radial osteosynthesis with locking plates.

**Material and Methods**

We performed a retrospective study, based on medical records and radiographs of 30 patients admitted to the Clinical Service of Orthopedics and Traumatology of Hospital Naval Marcílio Dias, Rio de Janeiro, RJ, Brazil, submitted to the surgical treatment for distal radial fractures with specifically-designed titanium plates with double distal column and locking in variable angles. The surgeries were performed by Dr. Saulo Fontes Almeida and Dr. Jurandy de Abreu Câmara Filho between 2016 and 2017. Patients with immature skeleton were excluded. This project was approved by the ethics committee of the institution with number 2.447.319.

Sociodemographic data, including age, gender, date of surgery, side and dominant hand, were obtained and recorded (► **Table 1**).

Wrist radiographs in anteroposterior and lateral incidences were preoperatively classified according to the universal method proposed by Cooney and Berger and the AO Foundation.

The Lafontaine instability criteria were used as study parameters to indicate the surgical procedure in question: dorsal deviation greater than 20 degrees, dorsal comminution, radial shortening greater than 9 mm, radiocarpal and distal radioulnar joint involvement, association with ulnar fractures, distance between intra-articular fragments greater than 2 mm, and age greater than 60 years-old.

Clinically, the range of motion of the wrist was observed through flexion, extension, and radial and ulnar deviation between 6 and 8 months postoperatively. Measurements of the motion arcs were performed by at least two authors using a goniometer, and average values were documented.

Anteroposterior and lateral radiographic incidences of both wrists were used for comparative purposes to control the surgical reduction. The radiographic control was evaluated according to the Lidström's anatomical and radiological

**Table 1** Clinical evaluation

Patient	Age	Gender	Affected arm	Ulnar deviation	Radial deviation	Flexion	Extension	Radiological evaluation
1	91	M	L	26°	21°	55°	50°	Good
2	66	M	L	29°	20°	58°	49°	Good
3	49	F	R	28°	25°	62°	58°	Excellent
4	58	F	L	26°	25°	40°	50°	Excellent
5	63	M	R	29°	26°	45°	52°	Good
6	54	F	R	28°	25°	59°	58°	Excellent
7	31	F	L	30°	25°	62°	59°	Excellent
8	43	M	L	30°	25°	80°	50°	Good
9	76	F	R	29°	24°	56°	52°	Excellent
10	40	F	R	31°	23°	63°	60°	Excellent
11	67	F	L	25°	23°	55°	50°	Excellent
12	63	F	R	34°	25°	48°	56°	Excellent
13	79	F	L	30°	25°	80°	50°	Good
14	50	M	L	30°	25°	70°	63°	Excellent
15	70	M	L	26°	24°	45°	50°	Excellent
16	52	M	R	31°	22°	55°	53°	Good
17	83	F	L	21°	23°	55°	52°	Regular
18	68	F	L	30°	23°	80°	68°	Excellent
19	83	F	L	30°	20°	60°	55°	Excellent
20	84	F	L	32°	22°	55°	48°	Excellent
21	32	M	R	30°	23°	60°	56°	Excellent
22	49	M	L	30°	21°	72°	55°	Excellent
23	68	F	L	25°	20°	68°	45°	Excellent
24	80	F	L	26°	19°	63°	48°	Excellent
25	83	F	R	27°	18°	60°	49°	Excellent
26	58	F	R	30°	25°	55°	53°	Excellent
27	70	F	L	30°	24°	55°	52°	Excellent
28	20	M	L	20°	25°	58°	60°	Excellent
29	63	F	L	30°	22°	50°	58°	Excellent
30	58	F	R	29°	20°	59°	56°	

Abbreviations: F, female; L, left; M, male; R, right.

classification for distal radial fractures and classified as excellent, good, regular and poor (► **Table 2**).

Clinical and radiographic results were analyzed and compared.

## Results

The results from the 30 patients are shown in ► **Table 1**; however, the radiological evaluation of the 30<sup>th</sup> patient was lacking from the medical record.

No infections were observed, and all fractures were consolidated.

Patients ages ranged from 20 to 91 years-old, with a mean of 56 years-old; 66.6% of the patients were female and 33.3% male. The left side was affected in 63.3% of the patients,

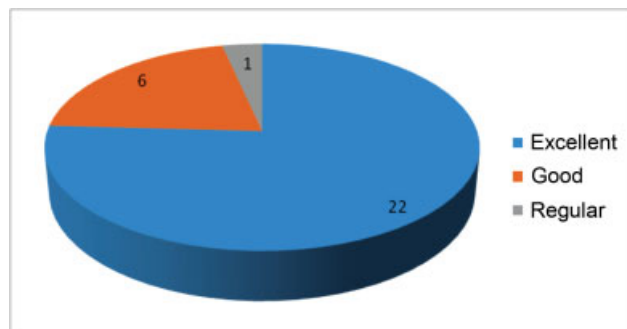
whereas the right side was involved in 36.3% of the patients. The radiographic evaluation showed 22 (75.86%) excellent results, 6 (20.69%) good results, and 1 (3.45%) regular result (► **Fig. 1**).

In the clinical evaluation, the mean ulnar deviation was 28.40, with a standard deviation of 3.0 and a coefficient of variation of 10.56%. The mean radial deviation was of 22.93, with a standard deviation of 2.2 and a coefficient of variation of 9.59%. The mean range of motion in flexion was 59.43, with a standard deviation of 9.86 and a coefficient of variation of 16.59%. In extension, the mean range of motion was 53.83, with a standard deviation of 5.09 and a coefficient of variation of 9.46%. These results are shown in ► **Table 3**.

There were no postoperative complications reports in the patients' records.

**Table 2** Anatomical and radiological classification for distal radial fractures according to Lidström

<b>Excellent</b>
Insignificant deformity
- Dorsal angle greater than 0° (neutral)
- Radial shortening lower than 3 mm
- Radial inclination loss not greater than 4°
<b>Good</b>
Small deformity
- Dorsal angle between 1–10°
- Radial shortening between 3–6 mm
- Radial inclination loss between 5–9 °
<b>Regular</b>
Moderate deformity
- Dorsal angle between 11–14°
- Radial shortening between 7–11 mm
- Radial inclination loss between 10–14°
<b>Bad</b>
Severe deformity
- Dorsal angle greater than 15°
- Radial shortening greater than 11 mm
- Radial inclination loss greater than 15°

**Fig. 1** Radiological evaluations results

## Discussion

The distal radial fracture is a complex lesion. It is more frequent in adult patients after the 4th decade of life, accounting for 10 to 20% of all fractures seen in the emergency room. The most affected age group is between 60 and 69 years-old, and the incidence is higher in women. However, in the last 20 years, a second peak of incidence has appeared in people between 20 and 40 years-old.<sup>11–14</sup> In our study, patients ages ranged from 20 to 91 years-old, with an average age of 56 years-old, and these fractures were more frequent after the 5th decade of life, approaching the values found by the aforementioned authors.

**Table 3** Mean, standard deviation and coefficient of variation from ulnar and radial deviations, flexion and extension

Estimative	Ulnar deviation	Radial deviation	Flexion	Extension
<b>Mean</b>	28.40%	22.93%	59.43%	53.83%
<b>Standard deviation</b>	3.00%	2.20%	9.86%	5.09%
<b>Coefficient of variation</b>	10.56%	9.59%	16.59%	9.46%

There are no Brazilian epidemiological data, but, in the United Kingdom, the incidence is 9 per 10,000 men and 37 per 10,000 women per year.<sup>15</sup> The present study had 20 female patients, corresponding to 66.6% of the sample, and 10 male patients, corresponding to 33.3%, evidencing the higher incidence of this type of fracture in women. The left side was affected in 63.3% of the cases, whereas the right side was involved in 36.3% of the cases.

It has been observed that the volar plate reduces the risk of tendon irritation, which is one of the major problems of the dorsal plate. Some authors have reported few complications using this plate. The postoperative complications of the distal radial fracture discussed in the literature include extensor or flexor tendon tenosynovitis, reflex sympathetic dystrophy, carpal tunnel syndrome, delayed consolidation, implant loosening, tendon rupture (long flexor tendon of the thumb or long extensor tendon of the thumb), defective consolidation, neural lesions (median nerve) and radiocarpal and radioulnar arthrosis.<sup>8,12,16–22</sup> No complications were observed in our study.

Leung et al<sup>23</sup> reported better functional and radiographic results with the use of locking volar plates regardless of the postoperative follow-up time when compared with external fixators or percutaneous fixation with Kirschner wires. Our study corroborates these findings regarding functional results, but we disagree about the time of postoperative follow-up, since we observed better results in the evaluation performed after 6 months.

Fujii et al<sup>24</sup> found no relation between the functional result and the radiographic parameters at the distal end of the radius as it was before the fracture. Similarly, Jaremko et al,<sup>25</sup> who evaluated patients submitted to conservative treatment for distal radial fractures, observed that there was no relationship between functional results and the fracture reduction to “acceptable” radiographic levels. Xavier et al<sup>18</sup> reported that the radiological values do not influence the range of motion; no significant difference was observed because, while the radiographs of certain patients with smaller wrist motions were classified as good or excellent, radiographs from other patients with extensive wrist mobilization were classified as regular or poor according to van Eerten et al.<sup>26</sup> Drobotz et al<sup>20</sup> obtained radiographic results from a total of 30 patients, 24 of whom were classified as good or excellent (7 as excellent and 17 as

good) according to the Lidström method, which corresponded to 80% of the study patients; in addition, four patients were classified as regular, and two cases as bad. Severo et al,<sup>27</sup> in a study of distal radial fracture treated with the Ulson technique, obtained 64 results considered excellent (43.2%), 62 good (41.9%), 18 regular (12.2%), and 4 poor (2.7%). The mean range of motion at wrist flexion was 65° (normal, up to 80°), whereas, at wrist extension, the mean range of motion was 61° (normal, up to 70°) determined radiographically by statistical analysis. At our radiographic evaluation, there were 22 (75.86%) excellent results, 6 (20.69%) good and 1 (3.45%) regular. Moreover, analyzing the data, it can be said that virtually all surgical procedures were successful, since most (75.86%) led to excellent radiographic results. Regarding the arc of motion, we obtained a mean ulnar deviation of 28.40°; a mean radial deviation of 22.93°; and 59.43° in flexion, and 53.83° in extension. This leads us to disagree with Fujii et al<sup>24</sup> and Jaremko et al,<sup>25</sup> who mention that there is no relation between the functional outcome and the reestablishment of the radiographic parameters of the distal radial end as it was before the fracture. However, in our radiographic study, the coefficient of variation demonstrated a homogeneous scattering result, corroborating data from Drobetz et al<sup>20</sup> and Severo et al,<sup>27</sup> who obtained excellent radiographic parameters in the postoperative period.

## Conclusion

After analyzing the results, we conclude that:

- Distal radial fractures affected patients in their 5<sup>th</sup> decade of life.
- Females were most affected.
- There was a predominance of left side involvement.
- After clinical and radiological evaluation, the use of a locking plate is a method with a high success rate in the surgical treatment of distal radial fractures.

### Conflicts of interest

The authors declare that there is no conflict of interest.

## References

- 1 Arora R, Gabl M, Gschwentner M, Deml C, Krappinger D, Lutz M. A comparative study of clinical and radiologic outcomes of unstable colles type distal radius fractures in patients older than 70 years: nonoperative treatment versus volar locking plating. *J Orthop Trauma* 2009;23(04):237–242
- 2 O'Neill TW, Cooper C, Finn JD, Lunt M, Purdie D, Reid DM, et al; UK Colles' Fracture Study Group. Incidence of distal forearm fracture in British men and women. *Osteoporos Int* 2001;12(07):555–558
- 3 Liporace FA, Adams MR, Capo JT, Koval KJ. Distal radius fractures. *J Orthop Trauma* 2009;23(10):739–748
- 4 Osada D, Viegas SF, Shah MA, Morris RP, Patterson RM. Comparison of different distal radius dorsal and volar fracture fixation plates: a biomechanical study. *J Hand Surg Am* 2003;28(01):94–104
- 5 McCall TA, Conrad B, Badman B, Wright T. Volar versus dorsal fixed-angle fixation of dorsally unstable extra-articular distal radius fractures: a biomechanical study. *J Hand Surg Am* 2007;32(06):806–812
- 6 Wong KK, Chan KW, Kwok TK, Mak KH. Volar fixation of dorsally displaced distal radial fracture using locking compression plate. *J Orthop Surg (Hong Kong)* 2005;13(02):153–157
- 7 Jupiter JB, Marent-Huber M; LCP Study Group. Operative management of distal radial fractures with 2.4-millimeter locking plates. A multicenter prospective case series. *J Bone Joint Surg Am* 2009;91(01):55–65
- 8 Arora R, Lutz M, Hennerbichler A, Krappinger D, Espen D, Gabl M. Complications following internal fixation of unstable distal radius fracture with a palmar locking-plate. *J Orthop Trauma* 2007;21(05):316–322
- 9 Barton T, Chambers C, Bannister G. A comparison between subjective outcome score and moderate radial shortening following a fractured distal radius in patients of mean age 69 years. *J Hand Surg Eur Vol* 2007;32(02):165–169
- 10 Anzarut A, Johnson JA, Rowe BH, Lambert RG, Blitz S, Majumdar SR. Radiologic and patient-reported functional outcomes in an elderly cohort with conservatively treated distal radius fractures. *J Hand Surg Am* 2004;29(06):1121–1127
- 11 Caporrino FA, Belotti JC, Ulson HJR, Toledo LFO, Reis FB, Machado JKS. Fraturas da extremidade distal do rádio e da ulna. In: Pardini Júnior AG, Freitas A. *Traumatismos da mão*. 4a. ed. Rio de Janeiro: MedBook; 2008:411–445
- 12 de Oliveira Filho OM, Belangero WD, Teles JB. Fraturas do rádio distal: avaliação das classificações. *Rev Assoc Med Bras* (1992) 2004;50(01):55–61
- 13 Figl M, Wening P, Liska M, Hofbauer M, Leixnering M. Volar fixed-angle plate osteosynthesis of unstable distal radius fractures: 12 months results. *Arch Orthop Trauma Surg* 2009;129(05):661–669
- 14 Trumble TE, Wagner W, Hanel DP, Vedder NB, Gilbert M. Intrafocal (Kapandji) pinning of distal radius fractures with and without external fixation. *J Hand Surg Am* 1998;23(03):381–394
- 15 Nazar MA, Mansingh R, Bassi RS, Waseem M. Is there a consensus in the management of distal radial fractures? *Open Orthop J* 2009;3:96–99
- 16 Orbay JL, Fernandez DL. Volar fixation for dorsally displaced fractures of the distal radius: a preliminary report. *J Hand Surg Am* 2002;27(02):205–215
- 17 Reis FB, Machado JKS. Fraturas da extremidade distal do rádio e da ulna – tratamento cruento. In: Pardini A, Freitas A. *Traumatismos da Mão*. Rio de Janeiro: Medbook; 2008:438–445
- 18 Xavier CRM, Molin DCD, Santos RMM, Santos RDT, Ferreira Neto JC. Tratamento cirúrgico das fraturas do rádio distal com placa volar bloqueada: correlação dos resultados clínicos e radiográficos. *Rev Bras Ortop* 2011;46(05):505–513
- 19 Kamano M, Koshimune M, Toyama M, Kazuki K. Palmar plating system for Colles' fractures—a preliminary report. *J Hand Surg Am* 2005;30(04):750–755
- 20 Drobetz H, Kutscha-Lissberg E. Osteosynthesis of distal radial fractures with a volar locking screw plate system. *Int Orthop* 2003;27(01):1–6
- 21 Rozental TD, Blazar PE. Functional outcome and complications after volar plating for dorsally displaced, unstable fractures of the distal radius. *J Hand Surg Am* 2006;31(03):359–365
- 22 Gruber G, Zacherl M, Giessauf C, Glehr M, Fuerst F, Liebmann W, et al. Quality of life after volar plate fixation of articular fractures of the distal part of the radius. *J Bone Joint Surg Am* 2010;92(05):1170–1178
- 23 Leung F, Zhu L, Ho H, Lu WW, Chow SP. Palmar plate fixation of AO type C2 fracture of distal radius using a locking compression plate—a biomechanical study in a cadaveric model. *J Hand Surg [Br]* 2003;28(03):263–266
- 24 Fujii K, Henmi T, Kanematsu Y, Mishiro T, Sakai T, Terai T. Fractures of the distal end of radius in elderly patients: a

- comparative study of anatomical and functional results. *J Orthop Surg (Hong Kong)* 2002;10(01):9-15
- 25 Jaremko JL, Lambert RG, Rowe BH, Johnson JA, Majumdar SR. Do radiographic indices of distal radius fracture reduction predict outcomes in older adults receiving conservative treatment? *Clin Radiol* 2007;62(01):65-72
- 26 van Eerten PV, Lindeboom R, Oosterkamp AE, Goslings JC. An X-ray template assessment for distal radial fractures. *Arch Orthop Trauma Surg* 2008;128(02):217-221
- 27 Severo LA, Mentz L, Busetto AM, Lech O, Pinto S. Fraturas da extremidade distal do rádio tratadas pela técnica de Ulson. *Rev Bras Ortop* 2003;38(08):438-445