Published online: 2019-05-08

Rheumatoid Lymphedema Successfully Treated with Lymphaticovenular Anastomosis: A Case Report

Yuko Ichinose, MD[1] Yoshichika Yasunaga, MD, PhD[1,2] Shunsuke Yuzuriha, MD, PhD[1]

[1] Department of Plastic and Reconstructive Surgery, Shinshu University School of Medicine, Matsumoto, Japan
[2] Division of Plastic and Aesthetic Surgery, Ina Central Hospital, Ina, Japan

Address for correspondence Yoshichika Yasunaga, MD, PhD, Senior Head Physician, Division of Plastic and Aesthetic Surgery, Ina Central Hospital, 1313-1 Koshiro-kubo, Ina, Nagano 396-8555, Japan (e-mail: yysng@shinshu-u.ac.jp).

J Reconstr Microsurg Open 2019;4:e24–e28.

Abstract

Background A 76-year-old woman presented with rheumatoid lymphedema (RL) distal to the left elbow after 20 years of affliction with rheumatoid arthritis (RA). Although the RA was controlled by medication, the patient could not receive full-scale compression therapy for her edema with a medium-pressure compression sleeve (pressure: 20–25 mm Hg) due to hand dysfunction caused by long-term RA.

Methods Lymphaticovenular anastomosis (LVA) was performed after compression therapy with a low-pressure sleeve (14–18 mm Hg) proved ineffective for edema relief. Two anastomoses were created in a side-to-end fashion at the cubital fossa.

Results The edema improved rapidly after LVA and was maintained with a low-pressure compression sleeve.

Conclusion LVA represents a treatment option for remaining RL in RA treatment. As some RL patients are ineligible for full-scale compression therapy due to hand dysfunction caused by RA, LVA may help to reduce RL and enable edema management using a low-pressure compression garment without concern for hand dysfunction.

Keywords
- rheumatoid arthritis
- lymphedema
- lymphaticovenular anastomosis

Secondary lymphedema in the upper extremities is frequently reported as breast cancer-related lymphedema.[1] Although compression therapy is the cornerstone of upper limb lymphedema treatment,[2] reports on the efficacy of lymphaticovenular anastomosis (LVA) for arm lymphedema have recently surfaced.[3]

Rheumatoid lymphedema (RL) of the extremities is an extra-articular manifestation rarely found in rheumatoid arthritis (RA),[4] with limited information available on its management. Some authors have reported on the effectiveness of disease-modifying antirheumatic drugs[5,6] (DMARDs) or complementary alternative medicine[7] (CAM) on RL, but the efficacy of LVA for RL remains unclear. The present study describes the clinical outcome of a patient with RL in the left arm that was successfully treated with LVA.

Case Report

A 76-year-old right-handed woman had suffered from RA for 20 years. She had no history of surgery or trauma in her upper limbs or axillae, although prior lumbar compression fracture, thoracic compression fracture, and interstitial pneumonia were considered adverse effects related to RA treatment. She was presented at our outpatient department with edema in her left arm. Her height was 144 cm, weight was 47.5 kg, and body mass index (BMI) was 22.9 kg/m^2. Intermittent edema without redness or warmth in her left arm had begun at 66 years of age and progressed to persistent edema 8 years later. Diffuse edema was observed in the left hand and forearm that did not improve by arm elevation (►**Fig. 1A, B**). Findings of connective tissue fibrosis, such as skin thickening, fat deposition, and the absence of pitting, were absent. Although her RA disease activity was well controlled with 5 mg/day prednisolone and 2 mg/day tacrolimus at the first visit, the joints of the elbow, wrist, and fingers of both arms had become deformed over time and bilateral, symmetrical hand dysfunction was evident in terms of reduced grip strength and dexterity. Measured grip strength, using a mercury

received
November 6, 2018
accepted
January 19, 2019

DOI https://doi.org/10.1055/s-0039-1688763.
ISSN 2377-0813.

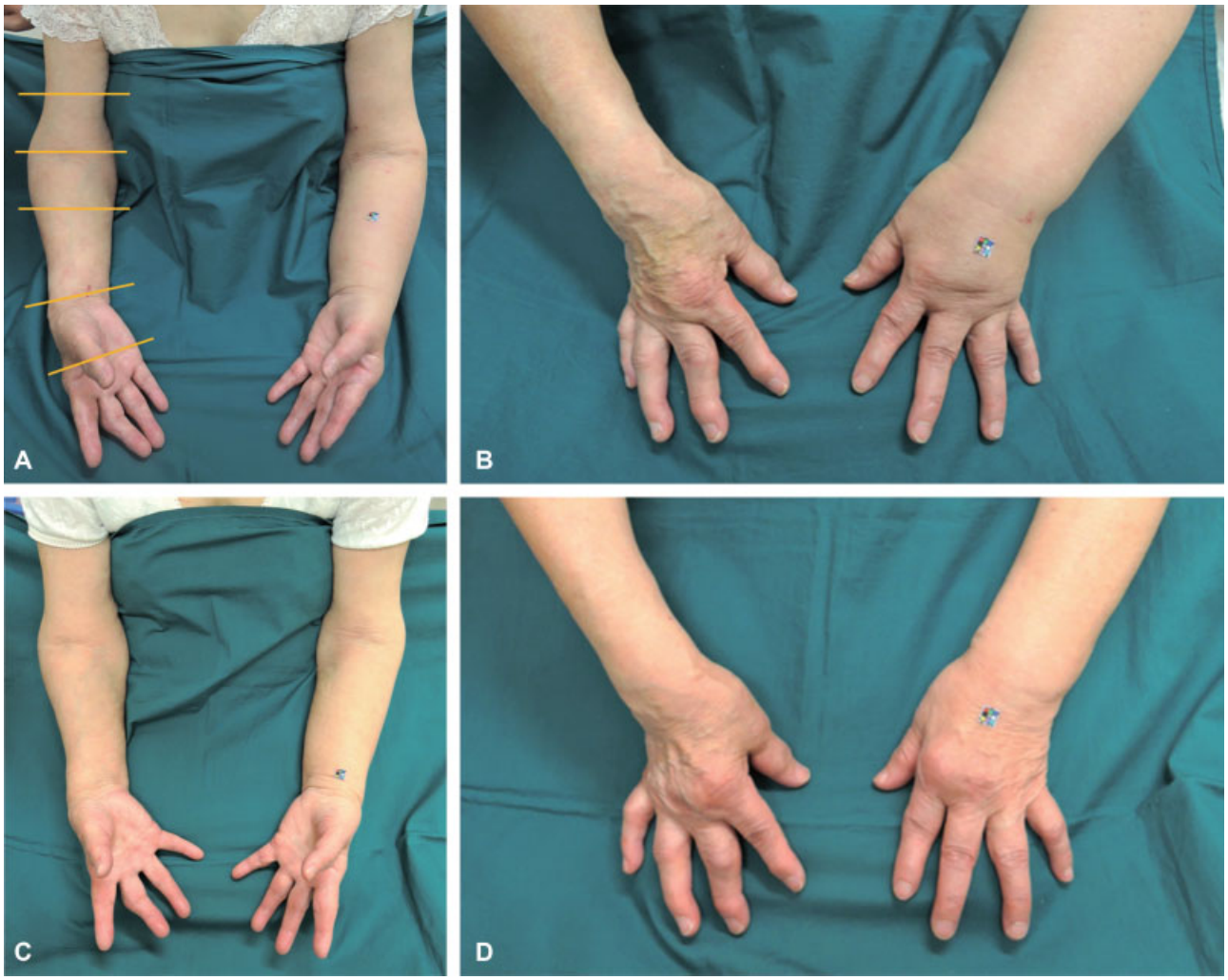

Fig. 1 Physical findings before and after LVA. Lines indicate the sites of arm circumference measurement in ►**Table 1**. (**A, B**) At first visit. Diffuse edema was apparent in the left hand and forearm. The joints of the elbow, wrist, and fingers of both arms were deformed due to rheumatoid arthritis such that the patient could not wear a prescribed medium-pressure sleeve. (**C, D**) At 20 months after LVA. The edema was improved and could be maintained with a low-pressure sleeve. LVA, lymphaticovenular anastomosis.

sphygmomanometer,[8] was 120 mm Hg in the right hand and 110 mm Hg in the left hand. Her left arm circumference at 5 cm below the elbow was 29.4 cm, which exceeded that of the unaffected right arm by 4.2 cm (►**Table 1**). We examined the edema further in suspicion of RA-associated secondary lymphedema.

Diagnosis and Compression Therapy

Segmental body water volume measurement by bioelectrical impedance analysis was according to a published method[9] that revealed arm body water volume (ABW) of 2,050 mL in the left arm which exceeded that in the right arm by 710 mL (►**Table 1**). ^{99m}Tc-human serum albumin lymphoscintigraphy

Table 1 Changes in arm circumference and water volume after LVA

	Before LVA			After LVA	
Circumference (cm)	Unaffected arm: right	Affected arm: left	Difference	Affected arm: left	Change
5 cm above elbow	24.5	28.4	3.9	24.4	−4.0
Elbow	27.5	29.1	1.6	27.0	−2.1
5 cm below elbow	25.2	29.4	4.2	24.0	−5.4
Wrist	16.4	21.1	4.7	18.0	−3.1
Hand	19.3	20.0	0.7	18.5	−1.5
ABW (mL)	1,340	2,050	710	1,250	−800

Abbreviations: ABW, arm body water volume; LVA, lyphaticovenular anastomosis.

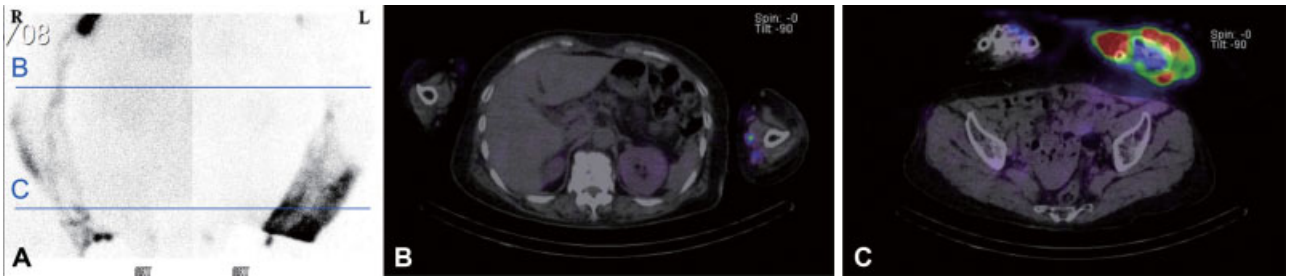

Fig. 2 Lymphoscintigraphy and SPECT at the first visit. (**A**) ^{99m}Tc-HSA lymphoscintigraphy of both arms. Anterior view at 120-minute after injection. Lymphatic congestion was evident in the left arm distal to the elbow. Lines indicate the axial slice levels in SPECT. (**B**) SPECT at the level of the upper arm. No tracer accumulation was seen in the subcutaneous tissue of the upper arms. (**C**) SPECT at the level of forearm. The tracer was detected in the left forearm. HSA, human serum albumin; SPECT, single photon emission computed tomography.

and single-photon emission computed tomography (CT) for the diagnosis of lymphedema disclosed lymphatic congestion in the left arm distal to the elbow (►**Fig. 2**). CT showed bone destruction in both elbow joints, with no evidence of lymph node enlargement in the axilla or cubital fossa on either side. Based on her history of RA along with joint destruction in both elbows and lymphatic congestion distal to the left elbow, we diagnosed the patient's edema as secondary lymphedema associated with RA, or rheumatoid lymphedema (RL), of International Society of Lymphology (ISL) early stage II.[10] Attempts at full-scale compression therapy were unsuccessful since she could not put on the necessary medium-pressure compression sleeve (pressure: 20–25 mm Hg)[11] due to poor grip and impaired finger dexterity. Switching to a low-pressure compression sleeve (14–18 mm Hg) did not improve the edema. She underwent LVA 3 months after the first visit.

LVA Procedure

According to indocyanine green lymphography (ICG-LG) at the time of operation, a diffuse pattern[12] spread from the hand to the forearm consistently with the extent of the edema and a linear pattern starting around the cubital fossa vanished proximal to the medial epicondyle of the humerus (►**Fig. 3A, B**). These findings indicated that the lymphatic flow became congested from the hand to the forearm, with normally functioning superficial lymphatic vessels around

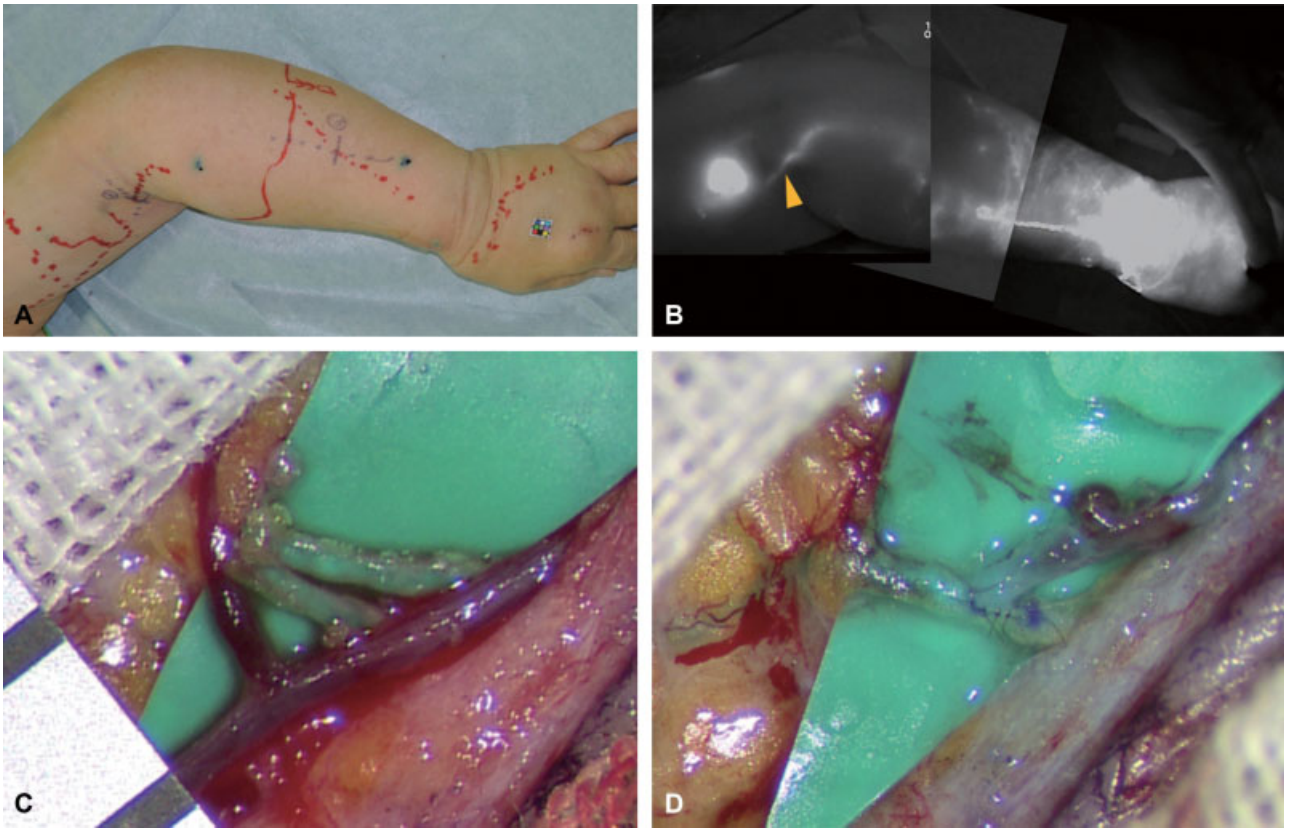

Fig. 3 Intraoperative findings of LVA. (**A, B**) ICG showed that lymphatic flow was congested from the hand to the forearm and that functioning lymphatic vessels existed around the cubital fossa. Arrowheads indicate the anastomosis site on a linear pattern. (**C**) Two lymphatic vessels of 0.55 and 0.45 mm in outer diameter classified as ectasis type by NECST classification. (**D**) Anastomosis of a 0.55 mm lymphatic vessel and 0.90 mm vein in a side-to-end fashion. ICG, indocyanine green lymphography; LVA, lymphaticovenular anastomosis. NECST, normal, ectasis, contraction, and sclerosis type.

Fig. 4 Time course of body water volume of the affected left arm. Screen capture from the InBody S10 (InBody Co., Ltd., Seoul, Korea) multifrequency bioelectrical impedance analyzer. (**A**) At the first visit. (**B**) After compression with a low-pressure sleeve. (**C**) At 6 days after LVA. (**D**) At 3 months after LVA. (**E**) At 9 months after LVA. (**F**) At 20 months after LVA. ECW, extracellular water; ICW, intracellular water; LA, left arm; LL, left leg; LVA, lymphaticovenular anastomosis; RA, right arm; RL, right leg; TBW, total body water; TR, trunk.

the cubital fossa. We located the functioning lympathic vessels at the cubital fossa as indicated by ICG-LG and created two lymphaticovenular anastomoses, both in a side-to-end fashion, using a surgical microscope under general anesthesia (►**Fig. 3C, D**). Degeneration of the anastomosed lymphatic vessels was considered mild and classified as ectasis type by NECST classification.[13] We could not confirm any obvious lymphatic vessel obstruction during surgery.

Postoperative Course

The patient resumed wearing a low-pressure sleeve after surgery. Her edema improved rapidly following LVA (►**Fig. 1C, D**), and arm circumference at 5 cm below the elbow had reduced by 5.4 cm at 20 months postoperatively (►**Table 1**). With a left-arm ABW decrease from 2,050 to 1,250 mL, the resulting difference between arms decreased from 710 to 90 mL (►**Fig. 4**). The reduction rate of edema, calculated as: (1–[difference in ABW between arms after LVA/difference in ABW between arms before LVA]) × 100%, was remarkable at 87.3%. She was able to maintain the decreased arm circumference and ABW with the low-pressure compression sleeve, although the edema relapsed without the garment.

Discussion

Extremity edema associated with RA was first pointed out as a kind of lymphedema in 1968[4] and later became known as RL. Several hypotheses have been suggested on the etiology of RL to date, including lymphangitis, lymphatic obstruction caused by fibrin, capillary permeability increase, abnormal fibrinolysis, and possible fibrosis of the superficial lymph vessels.[6] Bursitis and subsequent pressure elevation in the bursa have also been proposed to cause lymphedema in patients with RA.[14] In the present case, bone destruction of the elbow joint and localized edema distal to the elbow were observed only in the left arm and the degenerative change in the lymphatic vessels at the LVA site was mild. Judging from these findings and despite the absence of a clear obstruction intraoperatively, we presumed that the patient's RL arose secondarily from lymphatic obstruction by the deformed left elbow joint or by fibrin plugs at the left elbow. Since no edema was observed in the right arm or either leg, we considered systemic inflammation as a primary pathological change of RA to cause lymphedema to be unlikely.

According to past reports, RL occurs more frequently in the upper limbs, especially in the hands, and sometimes bilaterally.[6,7,15] RL may be an initial symptom of RA.[15] As RL does not show any consistent relationship with the duration or severity of arthritis, it is often difficult to improve RL using conventional antirheumatic drugs, such as DMARDs, corticosteroids, or methotrexate,[7] which necessitates other therapies for edema relief. Among drug treatments, etanercept[6] and a kind of CAM[7] (Juzentaihoto/TJ-48) were reported to improve RL for some patients. Otherwise, the cornerstone of RL management is compression therapy[6] as in the case of secondary lymphedema from other causes.[2]

Compression therapy for RL has a characteristic problem different from other forms of lymphedema in that arm dysfunction caused by the primary disease, such as RA in this case, renders it difficult for the patient to wear compression garments. In general, compression sleeves with medium pressure or more (i.e., above 20 mm Hg) are required for arm lymphedema with shape distortion as in this patient,[11] although many RA patients cannot put on the sleeve by themselves due to poor grip strength and impaired finger dexterity.

We typically perform LVA on lymphedema patients after at least 3 months of wearing a compression garment with medium pressure or more[9] based on the notion that sufficient LVA gains cannot be achieved without adequate compression, even after the surgery, in agreement with other authors.[16,17] Here, we prescribed a low-pressure sleeve at the first visit in view of the patient's diminished hand function, which was ultimately ineffective. Wearing the same sleeve postoperatively, however, the girth and ABW of the affected arm became sustainably decreased. We consider that the edema was controlled not only by LVA but also by the low-pressure sleeve because it relapsed without the sleeve after LVA. The present case suggests that even RL patients who have difficulty wearing a medium-pressure sleeve due to hand dysfunction can achieve good results with a low-pressure sleeve if preceded by LVA. Especially for RL in long-term RA patients with diminished hand function, LVA ahead of full-scale compression therapy may be considered.

There are several limitations to this report. First, we could not identify the precise cause of the patient's RL. Second, it was not possible to conclude whether LVA followed by compression therapy with a low-pressure garment could work for all RL patients based on this single case. Further prospective studies of larger cohorts are needed to confirm the efficacy of LVA for RL.

Conclusion

LVA represents an effective treatment option for remaining RL in RA treatment. Particularly in patients who have

difficulty with full-scale compression therapy due to hand function limitations, LVA in concert with a low-pressure compression garment may reduce RL and help edema management without concern for hand dysfunction.

Financial Disclosure
The authors have nothing to disclose.

Conflict of Interest
None declared.

References

1 Nguyen TT, Hoskin TL, Habermann EB, Cheville AL, Boughey JC. Breast cancer-related lymphedema risk is related to multidisciplinary treatment and not surgery alone: Results from a large cohort study. Ann Surg Oncol 2017;24(10):2972–2980
2 Badger CM, Peacock JL, Mortimer PS. A randomized, controlled, parallel-group clinical trial comparing multilayer bandaging followed by hosiery versus hosiery alone in the treatment of patients with lymphedema of the limb. Cancer 2000;88(12):2832–2837
3 Basta MN, Gao LL, Wu LC. Operative treatment of peripheral lymphedema: a systematic meta-analysis of the efficacy and safety of lymphovenous microsurgery and tissue transplantation. Plast Reconstr Surg 2014;133(04):905–913
4 Kalliomäki JL, Vastamäki M. Chronic diffuse oedema of the rheumatoid hand: a sign of local lymphatic involvement. Ann Rheum Dis 1968;27(02):167–169
5 Ostrov BE. Beneficial effect of etanercept on rheumatoid lymphedema. Arthritis Rheum 2001;44(01):240–241
6 Eyigor S, Karapolat H, Kirazli Y. Efficacy of etanercept and complete decongestive physical therapy in bilateral lower-limb lymphoedema associated with rheumatoid arthritis: a case report. Adv Ther 2008;25(01):23–28
7 Kogure T, Hoshino A, Ito K, et al. Beneficial effect of complementary alternative medicine on lymphedema with rheumatoid arthritis. Mod Rheumatol 2005;15(06):445–449
8 Lansbury J. Report of a three-year study on the systemic and articular indexes in rheumatoid arthritis; theoretic and clinical considerations. Arthritis Rheum 1958;1(06):505–522
9 Yasunaga Y, Yanagisawa D, Ohata E, Matsuo K, Yuzuriha S. Bioelectrical impedance analysis of water reduction in lower-limb lymphedema by lymphaticovenular anastomosis. J Reconstr Microsurg 2018. Doi: 10.1055/s-0038-1675368
10 International Society of Lymphology. The diagnosis and treatment of peripheral lymphedema: 2013 Consensus Document of the International Society of Lymphology. Lymphology 2013;46(01):1–11
11 International Lymphoedema Framework. International Consensus: Best Practice for the Management of Lymphoedema. London: MEP Ltd.; 2006
12 Yamamoto T, Yamamoto N, Doi K, et al. Indocyanine green-enhanced lymphography for upper extremity lymphedema: a novel severity staging system using dermal backflow patterns. Plast Reconstr Surg 2011;128(04):941–947
13 Mihara M, Hara H, Hayashi Y, et al. Pathological steps of cancer-related lymphedema: histological changes in the collecting lymphatic vessels after lymphadenectomy. PLoS One 2012;7(07): e41126
14 Kuroyanagi G, Yamada K, Imaizumi T, et al. Leg lymphedema caused by iliopectineal bursitis associated with destruction of a rheumatoid hip joint: A case report. Exp Ther Med 2013;6(04):887–890
15 Nagai Y, Aoyama K, Endo Y, Ishikawa O. Lymphedema of the extremities developed as the initial manifestation of rheumatoid arthritis. Eur J Dermatol 2007;17(02):175–176
16 Maegawa J, Yabuki Y, Tomoeda H, Hosono M, Yasumura K. Outcomes of lymphaticovenous side-to-end anastomosis in peripheral lymphedema. J Vasc Surg 2012;55(03):753–760
17 Campisi CC, Ryan M, Boccardo F, Campisi C. A single-site technique of multiple lymphatic-venous anastomoses for the treatment of peripheral lymphedema: long-term clinical outcome. J Reconstr Microsurg 2016;32(01):42–49