Systemic Air Embolism following CT-Guided Percutaneous Core Needle Biopsy of the Lung: Case Report and Review of the Literature

Katherine Marchak, MD[1] Michael J. Hong, MD[1] Kristofer M. Schramm, MD[2]

[1] Department of Radiology, University of Colorado | Anschutz Medical Campus, Aurora, Colorado
[2] Division of Vascular and Interventional Radiology, Department of Radiology, University of Colorado, Aurora, Colorado

Address for correspondence Kristofer M. Schramm, MD, Division of Vascular and Interventional Radiology, Department of Radiology, University of Colorado, Aurora, CO 80045 (e-mail: Kristofer.Schramm@ucdenver.edu).

Semin Intervent Radiol 2019;36:68–71

Abstract

Systemic air embolism (SAE) is a rare but serious complication of percutaneous core needle biopsy (PCNB) of the lung. Incidence of clinically apparent SAE is estimated at 0.061%, while clinically silent SAE may be as high as 3.8%. We present the complication of a small SAE during PCNB of the lung in a 78-year-old patient, which resulted in a transient myocardial ischemic event. This case highlights the importance of understanding the mechanism, frequency, and management of rare complications of PCNB of the lung; these complications should be considered in preoperative risk stratification. Regarding evaluation of postbiopsy computed tomography, operators should utilize a systematic search pattern to assess for complications.

Level of Evidence: Level 4, Case Report.

Keywords
- serious complication
- air embolism
- lung biopsy
- interventional radiology
- percutaneous biopsy
- CT guided lung biopsy

CT-guided percutaneous core needle biopsy (PCNB) of the lung is a common diagnostic procedure in interventional radiology. While pneumothorax and pulmonary hemorrhage are more frequently encountered complications, systemic air embolism (SAE) is a rare, serious complication which can result in myocardial infarction, stroke, and death. The incidence of clinically apparent SAE following PCNB is estimated between 0.02 and 0.06%,[1–3] while clinically silent SAE may be at least as high as 3.8%.[2] The following case describes a small SAE following PCNB of the lung, resulting in a transient myocardial ischemic event. This report presents an uncommon complication of a common procedure with a review of the established literature and guidelines for management. Institutional review board approval was not required for this report.

Case Report

A 78-year-old female with a history of myocardial infarction, hyperlipidemia, and non–insulin-dependent type 2 diabetes mellitus underwent a screening chest CT, demonstrating a 2.0-cm spiculated nodule in the right lower lobe (►**Fig. 1**). Subsequent positron emission tomography (PET) CT demonstrated minimally increased FDG avidity within the lesion of interest (maximum SUV 2.12). The patient was referred to interventional radiology for a diagnostic PCNB.

On the day of procedure, the patient was placed in the prone position; preoperative CT confirmed the lesion in the superior segment of the right lower lobe. Conscious and local sedation were administered. Under intermittent CT guidance, a 19-gauge coaxial biopsy needle was positioned in the lesion (►**Fig. 2a**). Two 20-gauge core needle samples were obtained; the introducer hub was manually covered during stylet and biopsy needle exchange. During biopsy acquisition, breathing instructions were provided to decrease the risk of air entry into the thorax; however, episodic coughing limited patient compliance. Intraoperative histopathologic analysis confirmed adequate tissue sample. The coaxial system was removed uneventfully. Initial review of postoperative CT demonstrated mild perilesional parenchymal hemorrhage (►**Fig. 2b**).

Issue Theme Management of Complications in IR; Guest Editor, Robert K. Ryu, MD, FSIR

DOI https://doi.org/10.1055/s-0039-1688417.
ISSN 0739-9529.

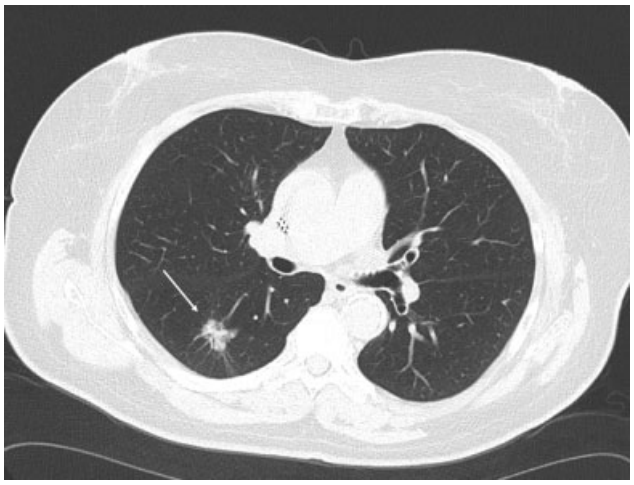

Fig. 1 Axial CT lung window demonstrating the spiculated lesion in the right lower lobe (*arrow*).

During transfer from the CT gantry, the patient experienced rapid-onset substernal chest pain and diaphoresis; both spontaneously resolved in approximately 10 minutes. Further review of the postoperative CT demonstrated small volume air within the left atrium and trace air within the descending thoracic aorta (►**Fig. 3**). There was no visible air in the coronary arteries. Blood pressure was mildly elevated (170/79); paced heart rate and rhythm were normal on electrocardiography (►**Fig. 4**). Immediate postoperative troponin-I was 0.20 and 0.23 four hours later (normal: $<$ 0.04). Full neurologic exam and head CT were within normal limits. Repeat CT chest at 6 hours postoperative demonstrated resolution of cardiosystemic air. The patient was monitored overnight and remained asymptomatic. She was discharged home with strict return precautions. Troponin levels obtained 3 months later normalized.

Fig. 2 Axial CT lung window demonstrating position of the introducer tip within the lesion and postbiopsy parenchymal hemorrhage.

Fig. 3 Axial CT lung window demonstrating air within the left atrium.

Discussion

CT-guided percutaneous lung biopsy is a common diagnostic modality of pulmonary nodules. While more frequently encountered complications such as pneumothorax and parenchymal hemorrhage are relatively minor, severe complications occur at a reported rate of 0.75%.[1] These complications include SAE, tumor seeding of the biopsy tract, severe pulmonary hemorrhage, hemothorax, and tension pneumothorax. Regarding all SAE, there are three large retrospective reviews within the current literature. Cumulatively, these reviews demonstrate the risk of clinically apparent SAE to be 0.08% (►**Table 1**).[1,2,4] In the presence of proven SAE, mortality is estimated at 0.018% and permanent morbidity at 0.009% with one patient having permanent neurologic deficits.

There are three postulated mechanisms for SAE following PCNB of the lung. These include direct communication of atmospheric air with pulmonary veins, bronchovenous fistula, and, theoretically, right-to-left arteriovenous shunt allowing air to bypass the mechanical barrier of the capillary bed.[5] Given the immediate perioperative presentation and absence of concomitant vascular anomalies, the presumed mechanism of SAE in this patient is direct intraoperative inspiration of atmospheric air into pulmonary veins from the access needle. Originally confined to the left atrium, the air embolus ultimately resulted in a transient clinical myocardial ischemic event, though air was never demonstrated within the coronary arteries.

In a retrospective analysis, Freund et al[2] identified multiple independent variables that increase the risk of SAE during

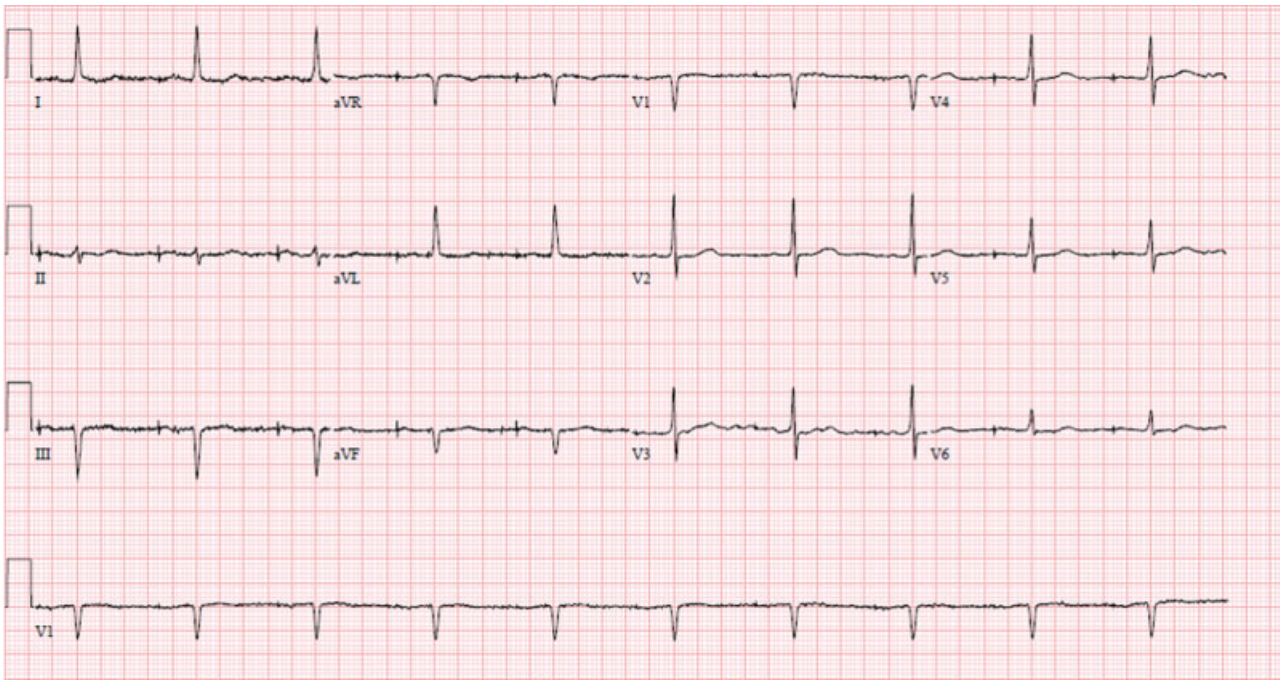

Fig. 4 Postprocedural EKG demonstrating normal sinus rhythm without QRS or T wave abnormalities.

Table 1 Review of SAE in PCNB

Article	No. of PCNB	No. of SAE	Complications
Tomiyama et al[1]	9,783	Symptomatic: 6 Asymptomatic: N/A	Permanent neurologic deficit: 1 Death: 1 Full recovery: 4
Freund et al[2]	610	Symptomatic: 3 Asymptomatic: 20	Death: 1 Full recovery: 2
Hiraki et al[4]	1,010	Symptomatic: 1 Asymptomatic: 3	Full recovery: 1
Total	**11,403 biopsies**	**10 symptomatic SAE**	**Mortality: 2/11,403** **Permanent morbidity: 1/11,403** **Full recovery: 7/11,403**

Abbreviations: PCNB, percutaneous needle biopsy; SAE, symptomatic air embolism.

PCNB of the lung. These include general anesthesia, prone position, lesion location above the left atrium during biopsy, and extralesional position of the introducer tip (this allows for multiple passes through lung–tumor interface). We postulate two, patient and procedural, variables that may have contributed to SAE in this patient. Based on lesion location and morphology, we opted for a posterior approach via prone position; this placed the lesion above the left atrium. Original considerations of an anterolateral approach via supine position were deferred due to the likelihood of traversing the minor fissure and increasing the risk of pneumothorax. Given the significantly lower incidence of SAE, risk–benefit considerations favored our selected approach.

Another potential procedural risk factor for SAE is biopsy technique and choice of air lock. Several case reports of SAE describe a water-seal technique, in which sterile saline is dripped into the introducer during stylet and biopsy needle exchange. In the event of negative intrathoracic pressure during coaxial manipulation, this theoretically substitutes sterile fluid for air.[6] Other operators utilize manual coverage of the introducer hub during exchange. Additionally, breathe-hold maneuvers may help decrease the risk of air entry.[7] In this patient, immediate exchange and breathe-hold techniques were selected, but compromised by patient discomfort and coughing. Associated decreased intrathoracic pressure during cough is suspected to have contributed to SAE.

Finally, this patient highlights the importance of careful postoperative image analysis to identify and manage complications. As little as 2 mL of air in the cerebral circulation and 0.5 to 1.0 mL of air in the coronary circulation can be fatal.[8] If arterial air is recognized, the source of air should be removed, supplemental oxygen administered, and positional techniques to decrease risk of embolization should be performed. Supplemental

oxygen can be administered conservatively via non-rebreather mask or via hyperbaric therapy.[7,9] Hyperbaric oxygen therapy has proved beneficial and may help resolve symptoms; administration of 100% oxygen for 120 minutes at 3.1 atmospheres is preferred.[4] Both approaches reduce the size of the air embolus by promoting counter-diffusion of oxygen into the nitrogen bubble and facilitating nitrogen resorption.[7,9] There is controversy regarding optimal positioning of patients with known SAE. Some investigators opt for right lateral decubitus and Trendelenburg positions to promote air retention in the left ventricular apex and prevent efflux into the left ventricular outflow tract (LVOT).[10,11] Others recommend supine position, as they believe the buoyancy of gas is not sufficient to counteract blood flow.[12,13]

In summary, SAE is a rare but serious complication of PCNB of the lung that should be considered during perioperative risk stratification and procedural planning. Regarding analysis of immediate postbiopsy chest CT, operators should utilize a detailed, systematic search pattern to identify possible complications, including rigorous evaluation of cardiac and arterial structures. In the event of SAE, operators should be familiar with appropriate clinical management.

Conflicts of Interest
No financial disclosures or conflicts of interest.

References

1 Tomiyama N, Yasuhara Y, Nakajima Y, et al. CT-guided needle biopsy of lung lesions: a survey of severe complication based on 9783 biopsies in Japan. Eur J Radiol 2006;59(01):60–64
2 Freund MC, Petersen J, Goder KC, Bunse T, Wiedermann F, Glodny B. Systemic air embolism during percutaneous core needle biopsy of the lung: frequency and risk factors. BMC Pulm Med 2012;12:2
3 Richardson CM, Pointon KS, Manhire AR, Macfarlane JT. Percutaneous lung biopsies: a survey of UK practice based on 5444 biopsies. Br J Radiol 2002;75(897):731–735
4 Hiraki T, Fujiwara H, Sakurai J, et al. Nonfatal systemic air embolism complicating percutaneous CT-guided transthoracic needle biopsy: four cases from a single institution. Chest 2007; 132(02):684–690
5 Mansour A, AbdelRaouf S, Qandeel M, Swaidan M. Acute coronary artery air embolism following CT-guided lung biopsy. Cardiovasc Intervent Radiol 2005;28(01):131–134
6 Ramaswamy R, Narsinh KH, Tuan A, Kinney TB. Systemic air embolism following percutaneous lung biopsy. Semin Intervent Radiol 2014;31(04):375–377
7 Cheng HM, Chiang KH, Chang PY, et al. Coronary artery air embolism: a potentially fatal complication of CT-guided percutaneous lung biopsy. Br J Radiol 2010;83(988):e83–e85
8 Ohashi S, Endoh H, Honda T, Komura N, Satoh K. Cerebral air embolism complicating percutaneous thin-needle biopsy of the lung: complete neurological recovery after hyperbaric oxygen therapy. J Anesth 2001;15(04):233–236
9 Leach RM, Rees PJ, Wilmshurst P. Hyperbaric oxygen therapy. BMJ 1998;317(7166):1140–1143
10 Arnold BW, Zwiebel WJ. Percutaneous transthoracic needle biopsy complicated by air embolism. AJR Am J Roentgenol 2002;178(06):1400–1402
11 MacLean CA, Bachman DT. Documented arterial gas embolism after spinal epidural injection. Ann Emerg Med 2001;38(05): 592–595
12 Undersea and Hyperbaric Medical Society Workshop Panel. Final summary of recommendations: diving accident workshop 1990. In: Bennett PB, Moon RE, eds. Diving Accident Management. Bethesda, MD: Undersea and Hyperbaric Medical Society; 1990: 366–369
13 Muth CM, Shank ES. Gas embolism. N Engl J Med 2000;342(07): 476–482