



# Bone cement for ossicular rebridging after otic capsule sparing fracture

P. Encheva<sup>1</sup>, N. Sapundzhiev<sup>2</sup>, R. Nedeva<sup>3</sup>, R. Sokiranski<sup>4</sup>, G. Davidov<sup>2</sup>

<sup>1</sup>Medical University "Prof. Dr. Paraskev Stoyanov", Varna, Bulgaria

<sup>2</sup>Department of Neurosurgery and ENT Diseases, Division of ENT Diseases, Medical University "Prof. Dr. Paraskev Stoyanov", Varna, Bulgaria

<sup>3</sup>Department of Imaging Diagnostics and Radiotherapy, Medical University "Prof. Dr. Paraskev Stoyanov", Varna, Bulgaria

<sup>4</sup>The Radiology Center of Heidelberg, Germany



## Introduction

Middle ear diseases, otologic surgical procedures and traumas can disrupt sound transmission and cause conductive hearing loss. (1) (2) Ossicular discontinuity due to head injuries is most commonly associated with temporal bone fractures and should be considered when the conductive hearing impairment persists several weeks after the trauma and exceeds 30 dB. (3) Over the past decade, a recent innovation is the application of hydroxyapatite based bone cement as another surgical approach for reconstruction of such defects. (3) (4) The purpose of this study is to present hydroxyapatite bone cement rebridging after an atypical otic capsule sparing fracture.

## Materials and methods

A 42-year-old male presented with long standing conductive hearing loss some 3 months after a head injury. The audiogram revealed an air-bone gap of 46 dB on the diseased side. Pure-tone air and bone conduction thresholds were 76 dB and 30 dB, respectively. Cone beam computed tomography (CT) detected an atypical fracture of the left temporal bone, communicating with the left external ear canal. (Fig.1) The 3D visualization with CT virtual endoscopy suggested injury in the area of the stapes.

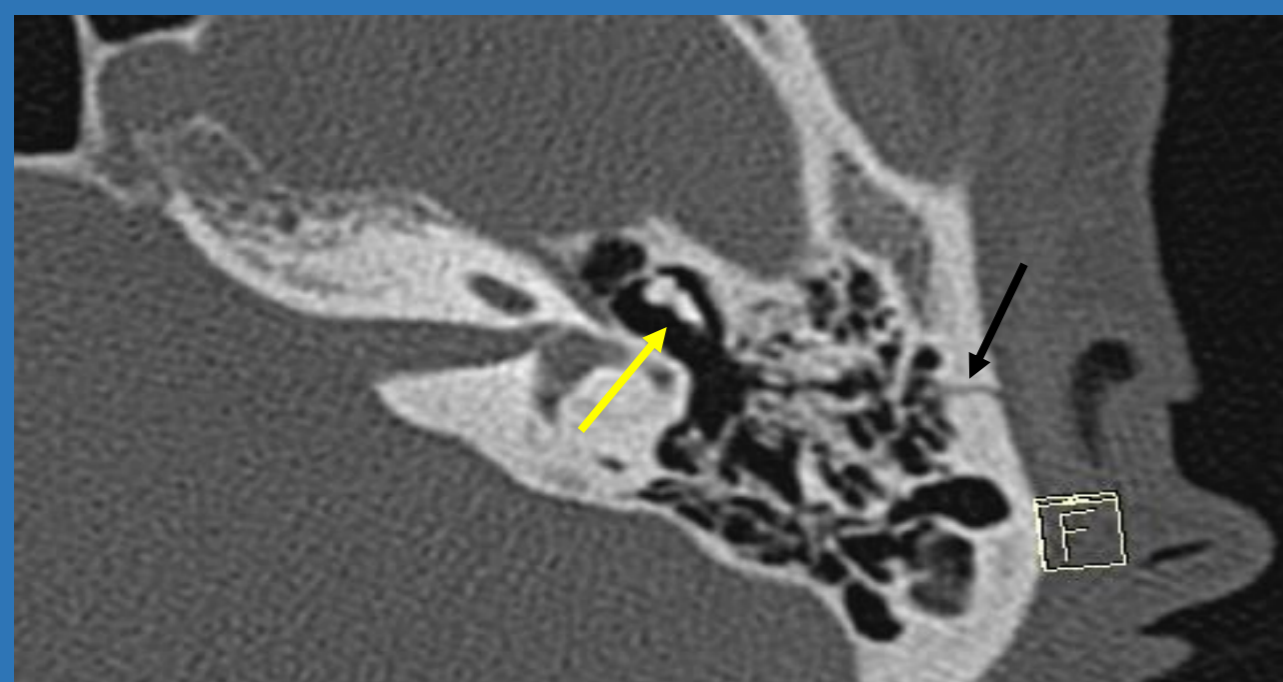

Fig.1. Cone beam computed tomography showing the fracture line of the left temporal bone (black arrow). The yellow arrow displays the incus and malleus, which normally resemble a scoop of ice cream in a cone.

Intraoperatively, disruption of the incudostapedial joint was discovered without signs of any other trauma to the ossicles. Under general anesthesia, rebridging with hydroxyapatite bone cement was undertaken. (Fig.2) Mobility of the ossicular chain was established.

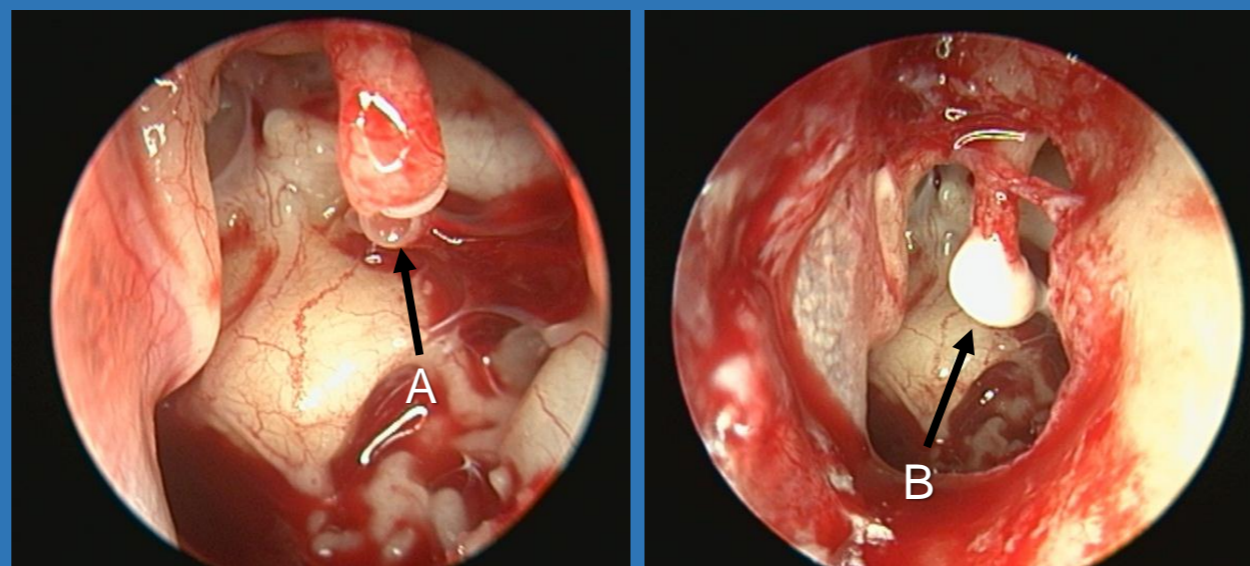


Fig. 2. Intraoperative images after elevation of tympanomeatal flap. A - disruption of the incudostapedial joint, B - bridging of the gap with hydroxyapatite bone cement.

## Results

No intra-, early or late postoperative complications or side effects were observed. The patient's hearing improved immediately upon removal of the intracanal packing on day 7 after the surgery. One month postoperatively, the air-bone gap decreased to 19 dB. Over 27 dB of hearing were regained. Follow-up CT examination revealed the incudostapedial joint without any signs of dislocation. (Fig.3)

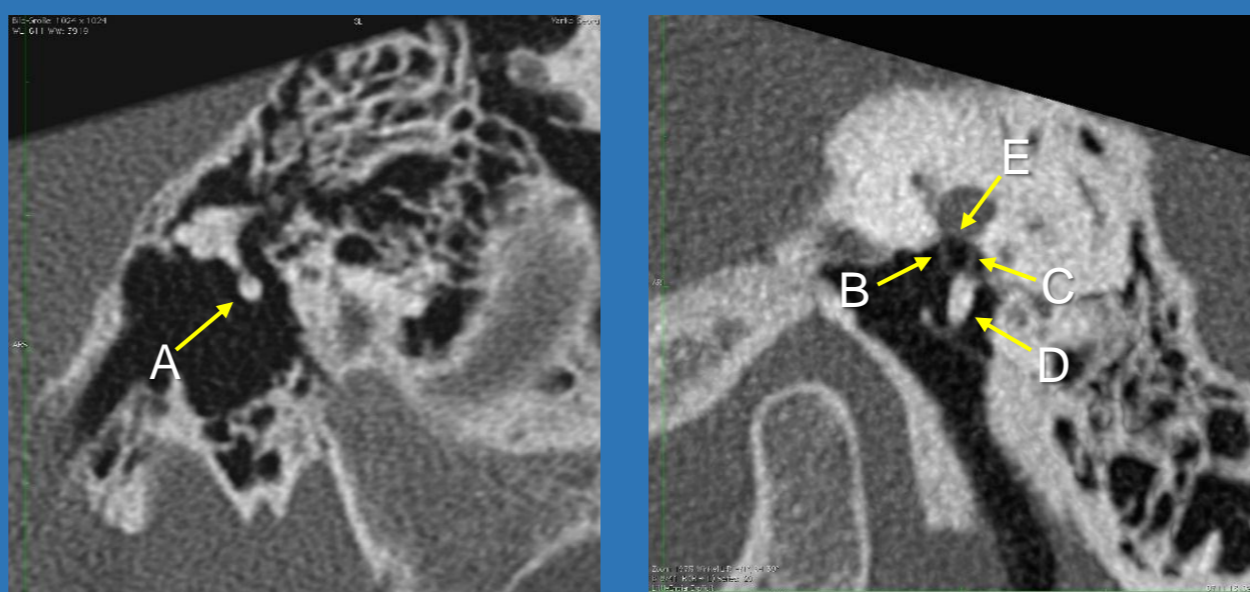


Fig. 3. Follow-up CT scan 2 months after the surgery. A - *articulatio incudostapedialis*, B - *crus anterior stapedis*, C - *crus posterior stapedis*, D - hydroxyapatite bone cement, E - *foramen ovale*.

## Discussion

Originally used in dental practice, the recent application of hydroxyapatite bone cement in otology and neurotology has offered reliable and easier surgical approach. (3) It has become a preferred material for restoring sound energy transfer, mainly used for ossicular rebridging and bone augmentation in cases of small discontinuities, but can also be used to provide additional stability to middle ear prostheses. (5) In medical literature, a lot of studied cases have shown its advantages and good hearing results. Our reported case is another demonstration of significant improvement in audiologic outcomes. Hydroxyapatite has gained popularity due to its adhesive and osseointegrative characteristics, biocompatibility, stability and easier insertion (4) (6) (7) It is also more cost-effective than other surgical methods and allows physiological reconstruction of the ossicular chain, which provides better hearing results. (6) The material is well tolerated, non-toxic and as a natural part of human bone, does not induce an inflammatory response. It congeals within 4-6 minutes which enables restoration of the ossicular defect with minimal manipulation and leads to shorter recovery period. (8) Preoperative 3D virtual endoscopy, as valuable and reliable method of diagnostic imaging, can be used to display the complex structures of the tympanum, determine the integrity of ossicular chain and also allows individualization of the surgical strategy. (9)

## Conclusion

Bone cements offer an easy to use approach for ossicular rebridging. They should be available on site to allow another option for tailored surgical approach. Preoperative CT-based virtual endoscopy may suggest the location of the ossicular chain disruption, without being conclusive.

## References:

- Hirsch JD, Vincent RL, Eisenman DJ. Surgical reconstruction of the ossicular chain with custom 3D printed ossicular prosthesis. *3D Print Med*, 27 July 2017
- Goebel JA, Jacob A. Use of Mimix hydroxyapatite bone cement for difficult ossicular reconstruction. *Otolaryngol-Head Neck Surg*. May 2005;132(5):727-34.
- Surgical Management and Hearing Outcome of Traumatic Ossicular Injuries. *ResearchGate*, Stefan Delrue et al.
- Kalcioğlu MT, Cicek T, Uzun L. Bone-Cement Usage for Ossicular Reconstruction. *Curr Pediatr Res*
- OtoMimix Bone Cement (70143266) | Olympus America | Medical
- Mahmut Tayyar Kalcioğlu, Utku Yılmaz. Should Bone Cement be Used Only in Limited Ossicular Chain Defects? *7*.
- Kalcioğlu MT, Tan M, Fleerackers J. The use of bone cement for ossicular chain defects. *Eur Arch Oto-Rhino-Laryngol Off J Eur Fed Oto-Rhino-Laryngol Soc EUFOS Affil Ger Soc Oto-Rhino-Laryngol - Head Neck Surg*. November 2013;270(11):2849-55.
- Mohamed Ali, Ahmed Shehata, Taha Mohamed. HYDROXYAPATITE IN OSSICULAR RECONSTRUCTION
- Lixin J, Zhiwen X. CT Virtual Endoscopy in Assessing Ossicular Chain Disruption Csused by Temporal Bone Fracture and Ear Trauma. *J Otol*. 01 December 2013;8(2):104-11.