

# Analysis of Surgical Outcome in Patients with Firearm Injury to Spine

Dibya Jyoti Mahakul<sup>1</sup> Ramesh Doddamani<sup>1</sup> Rajesh Meena<sup>1</sup> Deepak Agrawal<sup>1</sup>

<sup>1</sup>Department of Neurosurgery, AIIMS, New Delhi, India

**Address for correspondence** Rajesh Meena, Assistant Professor, Department of Neurosurgery, All India Institute of Medical Sciences, New Delhi 110029, India (e-mail: drrajeshmeena165@gmail.com).

Indian J Neurotrauma 2018;15:51–56

## Abstract

**Aim of Study** To see whether surgical intervention in gunshot injuries to the spine leads to recovery in neurologic status.

**Methods** It is a retrospective study conducted at the Jai Prakash Narayan Apex Trauma Centre (JPNATC), All India Institutes of Medical Sciences (AIIMS), New Delhi, where case records of 20 patients with gunshot injury to the spine, admitted between January 2013 to March 2018, were analyzed.

**Result** Out of 20 patients, 17 underwent surgical intervention. Entry wound was most common on the back, with the thoracic vertebrae being the most common segment involved. Nine patients had complete spinal cord injury (SCI) at the time of presentation and seven of them underwent surgery. However, only one of these patients showed neurologic improvement at follow-up. Seven patients with canal compromise underwent surgery, and only two of them showed improvement in neurologic status at follow-up. Early surgery was done in 8 out of 16 patients. All 16 patients underwent decompressive procedure, and 3 underwent additional stabilization procedure. Bullet was removed in nine cases. Intraoperative blood loss was minimal in 9 cases, and dural breach was noticed in 14 cases. At follow-up, 56.25% patients showed improvement in neurologic status.

**Conclusion** Surgical intervention, timing of surgery, amount of intraoperative blood loss, and dural breach had no significant impact on the overall surgical outcome. Neurologic status at the time of presentation is the single most important factor that determines the ultimate outcome. Indication and type of surgical intervention is still an ambiguous topic. Owing to lack of conclusive evidence, we believe that there is role for surgery when it is done with an intention to restore the neurologic function.

## Keywords

- ▶ gunshot injury to spine
- ▶ gunshot wound
- ▶ spinal injury
- ▶ complete spinal cord injury
- ▶ penetrating spinal injury

## Introduction

Gunshot injury to the spine, which was earlier associated predominantly with military population, is now seen increasingly in civilians due to easy availability of firearms and increase in violence in the society. With the contribution of 13 to 17%<sup>1</sup> to spinal injuries, it is now the third most common cause<sup>2</sup> of spinal injury after road traffic accident and fall. Gunshot wound (GSW) to the spine is a complex injury, with its ideal management being a matter of controversy. Medical literature is replete with studies in favor of conservative

management, thus implying that surgical intervention does not have much effect on the ultimate neurologic outcome. However, the catch lies in the fact that most of the studies are based on military population where there is a frequent use of firearms with a relatively higher muzzle velocity. Velocity of impact leading to the kinetic energy imparted by it to the surrounding tissues is the single most important factor that determines the destructive ability of projectile. Gunshot injuries are generally caused by high-velocity assault weapons of the range 2,800 to 3,800 ft/s.<sup>3</sup> Thus, GSWs received on battlefield are more destructive and carry a worse prognosis

## received

July 16, 2018

## accepted after revision

August 29, 2018

## published online

July 23, 2019

Copyright ©2018 Neurotrauma Society of India

DOI <https://doi.org/>

10.1055/s-0039-1677669

ISSN 0973-0508.

than their civilian counterparts.<sup>4</sup> Spinal cord injury (SCI) from spinal GSWs frequently presents as complete lesion with a decreased potential for neurologic recovery than with closed trauma.<sup>5</sup> Bullet damages tissues by the following mechanisms: (1) direct impact of bullet along its path, (2) pressure or shock waves created by bullet, and (3) temporary cavitation. SCI may therefore occur even without any obvious injury to the spinal canal and is termed as *spinal cord concussion*.

Commonly accepted indications for surgery include persistent cerebrospinal fluid (CSF) fistula, arteriovenous fistula, evidence of overt cervical instability, infection, and neurologic deterioration (particularly for incomplete injury) with persistent spinal cord impingement.

Current neurosurgical practice guidelines have not laid any protocol for the management of penetrating spine injuries. The most important question that a neurosurgeon encounters is whether a decompressive laminectomy can escalate the chance of regaining the neurologic function that is already lost or at least arrest the progression of the same.

## Aims and Objectives

The aim of this study was to analyze the outcome of surgical intervention in patients with firearm injury to the spine with respect to the neurologic status.

## Methods

It is a retrospective study conducted at Department of Neurosurgery, Jai Prakash Narayan Apex Trauma Centre (JPCATC), All India Institutes of Medical Sciences (AIIMS), New Delhi. Case records of patients with gunshot injury to the spine from January 2013 to March 2018, in whom surgical intervention was planned, were initially retrieved. These records were then analyzed on the basis of various clinical, radiologic, and operative parameters. At follow-up, patients were clinically examined, and radiologic status was compared with that of the preoperative variables. Assessment in the neurologic status was done using Nurick grade.

All the results were analyzed in SPSS version 22.0 (IBM Inc.). The analysis included frequency table, bar diagram, and pie chart. All quantitative variables were estimated using measures of central location (mean) and measures of dispersion (standard deviation). Pearson chi-square test and Student *t*-test were used for qualitative variables and continuous variables, respectively. For all analysis,  $p < 0.05$  was considered statistically significant.

## Results

Case records of 20 patients were analyzed. Two patients were excluded due to early mortality during the period of stabilization, and one patient refused surgery. Out of 17 patients who underwent surgery, 1 died during the hospital stay, hence was also excluded.

All the patients included in the study were males with the mean age of  $29.93 \pm 2.95$  years ranging from 16 to 56 years. Fourteen (87.5%) out of 16 patients suffered a civilian

gunshot injury whereas the mode of injury was military in the remaining 2 patients.

Entry wound was most common on the back (56.25%), with the thoracic vertebra being the most common segment involved (68.75%) followed by cervical (18.75%) and lumbar (12.5%). Exit wound was present in only 2 of the 16 patients.

Nine (56.25%) out of 16 patients had complete SCI at presentation (ASIA-A). Canal compromise was present in seven (43.75%) patients. Out of 11 patients with involvement of the thoracic vertebra, 5 showed canal compromise, and 4 of these 5 patients were ASIA-A at presentation. None of the three patients with cervical spinal injury had canal compromise, and none of them had complete SCI at presentation.

Median time from gunshot injury to surgery was 25 days. All 16 patients underwent decompressive procedures with 3 undergoing concurrent stabilization procedure as well. Bullet removal was done in 8 (50%) out of 16 patients. Dural tear was seen in 13 (81.25%) patients. Overall mean duration of postoperative hospital stay was 7 days whereas it was prolonged to 8 days in patients with dural tear.

Median period of follow-up was 3.3 years. Overall 9 (56.25%) out of 16 patients showed improvement in neurologic status at follow-up after surgery. Out of seven patients with complete SCI who underwent surgery, only one patient showed improvement in neurologic status at follow-up.

Out of seven patients with canal compromise who underwent surgery, neurologic improvement at follow-up was observed in two patients.

Out of 16 patients undergoing decompressive procedure, 8 showed improvement whereas 1 out of 3 patients undergoing combined approach showed improvement in neurologic status at follow-up.

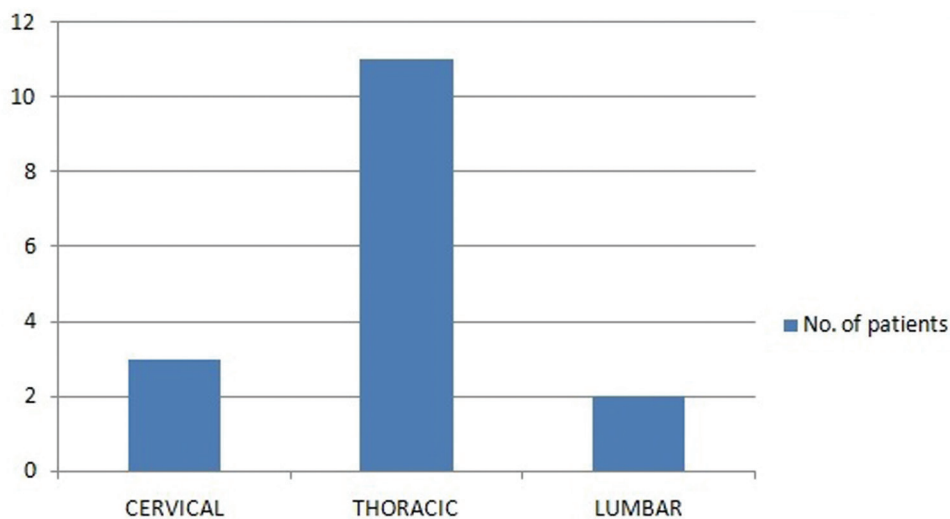
Six out of eight patients undergoing bullet removal showed improvement in neurologic status at follow-up.

All patients with involvement of the cervical and lumbar spine showed improvement in neurologic status at follow-up. However, only 6 out of 11 patients with thoracic spine involvement showed improvement in neurologic outcome.

## Discussion

The patient demographics and patterns of injury in this study correspond closely to those of prior studies. Most gunshot injuries to the spine occurred in young men with a mean age of  $29.93 \pm 2.95$  years in our population. All except two patients were victims of a handgun, involved in civilian violence. **Fig. 1** depicts the frequency distribution of gunshots according to various vertebral levels suffering ballistic injury, indicating a predominance of injury to the thoracic region. These data correspond well with findings that injuries to the thoracic spine are more common than lumbar and cervical injuries, presumably from the tendency of GSWs to congregate around the center of the body mass.<sup>6,7</sup>

In the thoracic vertebra, the canal-to-cord ratio is less compared with that in the cervical and lumbar regions. Hence, canal compromise and complete cord injury are seen more frequently in gunshot injuries to the thoracic vertebra.<sup>8</sup> Thus the level of vertebral injury is an important factor in the



**Fig. 1** The frequency distribution of patients according to various vertebral segments.

long-term outcome in cases with penetrating spinal injury. One patient with thoracic vertebra involvement and without canal compromise also showed complete SCI, thus suggesting spinal cord concussion as the reason behind such a clinical presentation.

All patients underwent decompressive procedures, and three of them also required additional stabilization procedure. One of these three patients had D10 body and pedicle fracture; thus, the patient underwent pedicle screw rod fixation along with laminectomy. The other two patients had comminuted L3 body fracture and thus required additional stabilization procedure. Civilian gunshot injuries are less likely to be unstable when compared with their military counterparts, owing to the relatively less impact velocity. We performed stabilization procedure in patients with injury to all the three columns. In cases with involvement of only two columns, especially when pedicles are involved, additional stabilization/fixation procedures should be contemplated.<sup>4,9</sup> ►Figs. 2 and 3 show the images of two cases for which surgical intervention was undertaken.

Aarabi et al and Hammoud et al recruited sufficient number of operative and nonoperative patients in each of the complete and incomplete neurologic deficit group. On analysis they did not find surgery to be associated with improved neurologic status.<sup>10,11</sup> Cybulski et al<sup>12</sup> only evaluated patients with injuries to the cauda equina and concluded that surgery was of benefit whether done early (< 72 hours) or late (> 72 hours), but there were no control data (nonoperative) to support their conclusion. Benzel et al<sup>13</sup> concluded that surgery was indicated in those patients with incomplete injury and evidence of continued compression of neurologic structures within the spinal canal. In a multicenter study, Waters and Adkins<sup>14</sup> found that bullet removal benefited those with complete or incomplete lesions between T12 and L4, but there was no effect in those between T1 and T11. ►Table 1 shows in a nutshell the surgical outcome in the aforementioned studies.

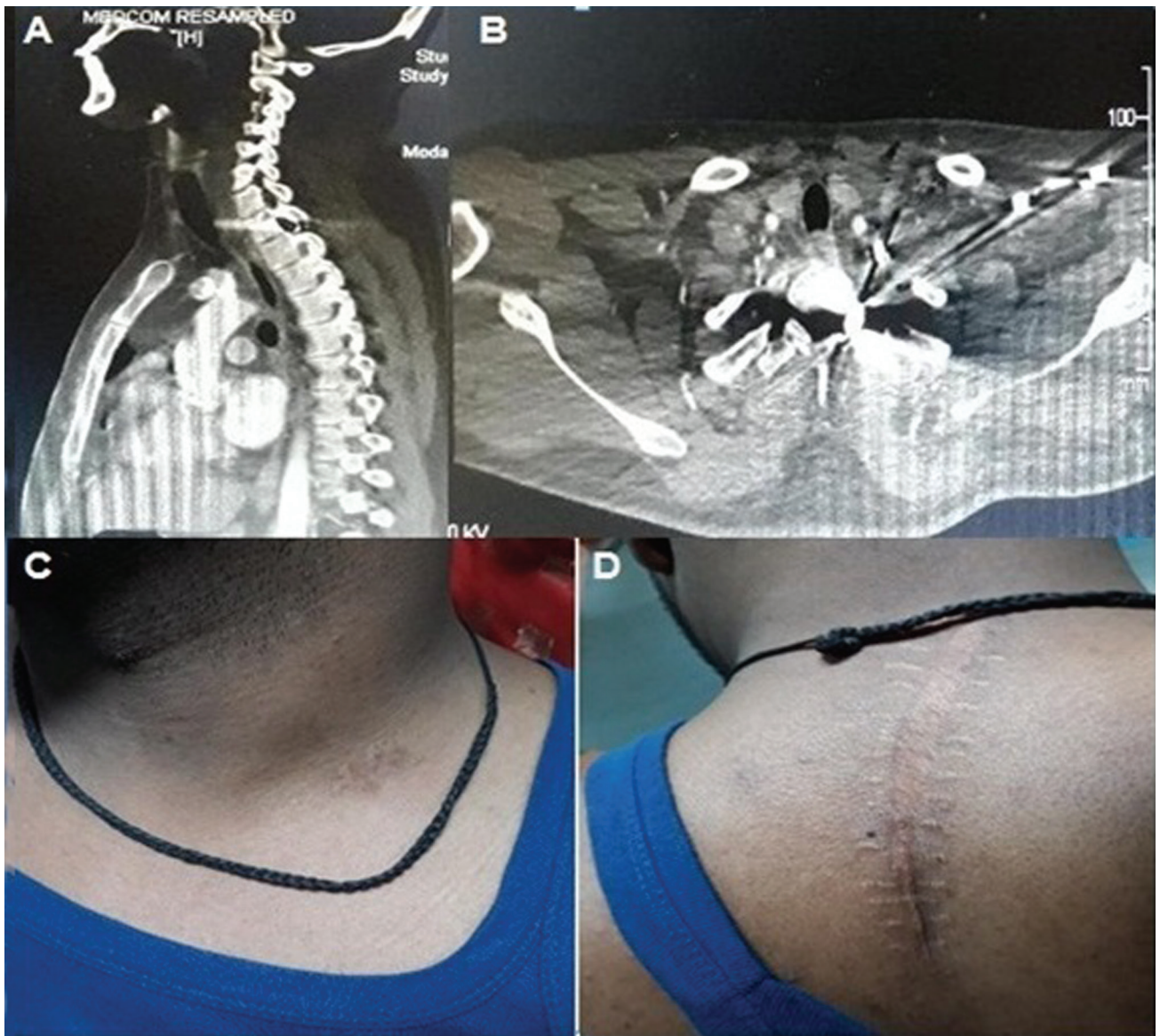In our study, at follow-up, 8 out of the 16 patients who had undergone decompressive surgery showed improvement in the neurologic status by at least one Nurick grade. Eight out

of 16 patients got the bullet removed, and 6 of them showed improvement in neurologic status at follow-up. Bullet removal during surgery was seen to be associated with better outcome. Civilian gunshot injury, involvement of the cervical region, lack of dural breach, and minimal intraoperative blood loss were associated with relatively greater percentage of patients getting benefitted from surgical intervention. However, the impact of these factors was not statistically significant enough to consider them as predictors for a better surgical outcome. The only factor that was statistically significant enough to influence the ultimate outcome was the neurologic status at the time of presentation (►Table 2).

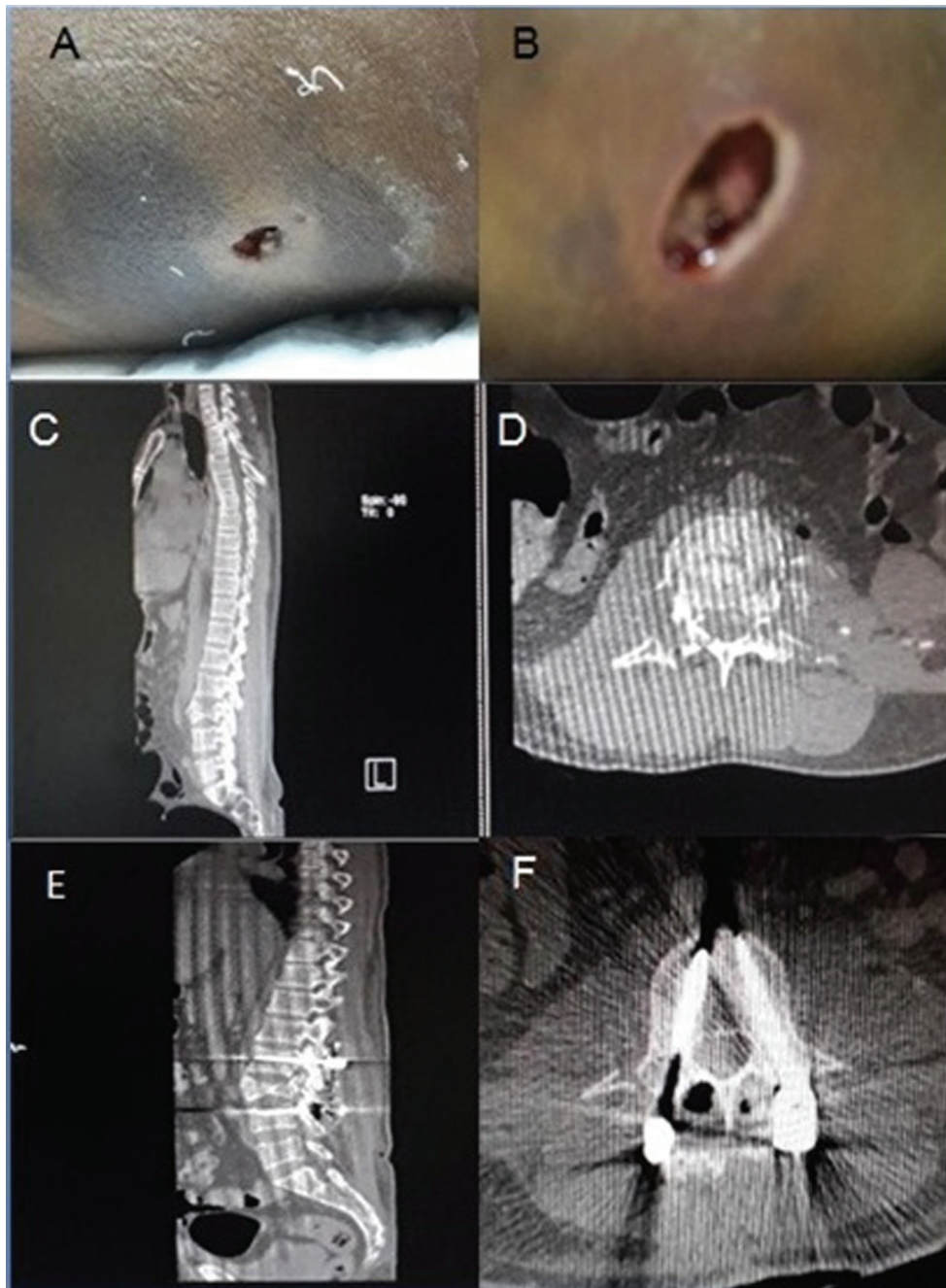
Treatment of spinal GSW requires a multidisciplinary approach with the goal of maintaining or restoring spinal stability and neurologic function and minimizing complications. Neurologic deterioration in the presence of persistent spinal cord impingement is an obvious and emergency indicator for surgical intervention. In this setting, if emergency surgery can be performed to eliminate spinal cord compression, it should be performed, particularly for epidural hematoma, empyema, bone or foreign-body compressive intrusion, or other remediable mass lesion. If mechanical forces from unstable spinal elements cause persistent compression and neurologic deterioration, cervical realignment and fusion may also be necessary.

## Conclusion

Surgical intervention, timing of surgery, amount of intraoperative blood loss, and dural breach had no significant impact on the overall surgical outcome. Mode of injury, cervical level of injury, and bullet removal were seen to be associated with improved outcome. Neurologic status at the time of presentation is the single most important factor that determines the ultimate outcome. Indication and type of surgical intervention is still an ambiguous topic. Owing to lack of conclusive evidence, we believe that there is role for surgery when it is done with an intention to restore the neurologic function.



**Fig. 2** (A, B) Preoperative CT scans of a patient showing fracture of left pedicle of D1 with the bullet in situ. (C) Healed entry wound. (D) Healed surgical wound.



**Fig. 3** (A, B) The entry (left flank) and exit (right flank) wounds, respectively. (C, D) Preoperative images of L3 vertebral body fracture. (E, F) Position of the screws that were placed during the stabilization procedure.

**Table 1** Surgical outcomes in various studies in nutshell

Author	Year	No. of patients	No. of surgeries	Percentage of improved outcome
Benzel et al <sup>13</sup>	1987	35	13	13 (100%)
Cybuiski et al <sup>12</sup>	1989	88	61	29 (47.5%)
Hammoud et al <sup>11</sup>	1995	64	23	4 (17.3%)
Aarabi et al <sup>10</sup>	1996	145	87	42 (48.27%)

This document was downloaded for personal use only. Unauthorized distribution is strictly prohibited.

**Table 2** The degree of association of various factors on the improvement of surgical outcome at follow-up.

Parameters	No. of patients	Improvement	p-value
Mode of Injury			0.88
Civilian	14	8	
Military	2	1	
Exit Wound			0.88
Yes	2	0	
No	14	9	
Complete SCI at presentation			0.006
Present	7	1	
Absent	9	8	
Vertebral level of injury			
Cervical	3	3	0.15
Lumbar	2	1	0.88
Thoracic	11	6	0.63
Canal compromise			0.07
Present	7	2	
Absent	9	7	
Associated vascular injury			0.44
Present	1	1	
Absent	15	8	
Early surgery			
Yes	7	4	0.67
No	9	5	
Bullet removal			0.15
Yes	8	6	
No	8	3	
Minimal Intraoperative blood loss			0.15
Yes	8	6	
No	8	31	
Dural tear			0.60
Yes	13	7	
No	3	2	

## References

- Farmer JC, Vaccaro AR, Balderston RA, Albert TJ, Cotler J. The changing nature of admissions to a spinal cord injury center: violence on the rise. *J Spinal Disord* 1998;11(5):400–403
- Miller CA. Penetrating wounds of the spine. In: Wilkins RH, Rengachary SS, eds. *Neurosurgery*. Vol. 2. San Francisco, CA: McGraw-Hill; 1985:1746–1748
- DeMuth WE Jr. Bullet velocity as applied to military rifle wounding capacity. *J Trauma* 1969;9(1):27–38
- Yoshida GM, Garland D, Waters RL. Gunshot wounds to the spine. *Orthop Clin North Am* 1995;26(1):109–116
- Velmahos GC, Degiannis E, Hart K, Souter I, Saadia R. Changing profiles in spinal cord injuries and risk factors influencing recovery after penetrating injuries. *J Trauma* 1995;38(3):334–337
- Schneider RC, Webster JE, Lofstrom JE. A follow-up report of spinal cord injuries in a group of World War II patients. *J Neurosurg* 1949;6(2):118–126
- Simpson RK Jr, Venger BH, Narayan RK. Treatment of acute penetrating injuries of the spine: a retrospective analysis. *J Trauma* 1989;29(1):42–46
- Koizumi M, Ueda Y, Iida J, et al. Upper thoracic spinal cord injury without vertebral bony lesion: a report of two cases. *Spine* 2002;27(21):E467–E470
- Meyer PR, Apple DF, Bohlman HH, Ferguson RL, Stauffer ES. Symposium: management of fractures of the thoracolumbar spine. *Contemp Orthop* 1988;16:57–86
- Aarabi B, Alibai E, Taghipur M, Kamgarpur A. Comparative study of functional recovery for surgically explored and conservatively managed spinal cord missile injuries. *Neurosurgery* 1996;39(6):1133–1140
- Hammoud MA, Haddad FS, Moufarrij NA. Spinal cord missile injuries during the Lebanese civil war. *Surg Neurol* 1995; 43(5):432–437, discussion 437–442
- Cybulski GR, Stone JL, Kant R. Outcome of laminectomy for civilian gunshot injuries of the terminal spinal cord and cauda equina: review of 88 cases. *Neurosurgery* 1989;24(3):392–397
- Benzel EC, Hadden TA, Coleman JE. Civilian gunshot wounds to the spinal cord and cauda equina. *Neurosurgery* 1987; 20(2):281–285
- Waters RL, Adkins RH. The effects of removal of bullet fragments retained in the spinal canal. A collaborative study by the National Spinal Cord Injury Model Systems. *Spine* 1991;16(8):934–939