

A Comparative Outcome Analysis of Two Posterior Only Approach for Thoracolumbar Fracture

Deepak Kumar Singh¹ Surendra Kumar Gupta¹ Rakesh Kumar¹ Faran Ahmad¹ Kuldeep Yadav¹ Mohammad Kaif¹

¹Department of Neurosurgery, Dr. Ram Manohar Lohia Institute of Medical Sciences, Lucknow, Uttar Pradesh, India

Address for correspondence Rakesh Kumar, MCh, Assistant Professor, Department of Neurosurgery, Dr. Ram Manohar Lohia Institute of Medical Sciences, Vibhuti Khand Gomti Nagar Lucknow 226010, Uttar Pradesh, India (e-mail: rksingh2226@gmail.com).

Indian J Neurotrauma 2018;15:106–112

Abstract

Objectives Most common surgical intervention in thoracolumbar fracture is pedicle screw fixation with posterior decompression through traditional posterior approach. Nowadays, we are doing combined anteroposterior decompression with anteroposterior fixation through posterior only approach. So, we attempt to compare these two approaches in terms of surgical and functional outcome.

Method This is a retrospective study. We included 47 patients of traumatic thoracolumbar fracture between September 2016 and January 2018. Fourteen patients were treated by three-column fixation through posterior only approach and 33 patients were treated with traditional posterior approach. In three-column fixation, transpedicular corpectomy with dynamic mesh cage placement with B/L pedicle screw fixation with 360 canal decompression was done, whereas in traditional posterior approach, only posterior decompression with B/L pedicle screw fixation was done. Parameters for comparison include patients' parameters, fracture types, operative duration, average blood loss, kyphotic correction, and neurological and functional improvement after 1 week and 3 months postoperatively.

Result The average operative time (150 ± 13.01 minutes) and blood loss (263 ± 40.84 mL) in combined decompression and fixation through posterior only approach were higher than average operative time (120.3 ± 25.43 minutes) and average blood loss (108 ± 27.32 mL) in traditional posterior approach. In traditional surgeries, there was an observed correction of $11.7^\circ \pm 3.6^\circ$ in kyphosis, while in combined surgeries the observed correction in kyphosis was $15.3^\circ \pm 4.3^\circ$. There is no statistically significant neurological and functional outcome than traditional posterior approach.

Conclusion Combined anteroposterior decompression and stabilization through posterior only approach is convenient for complete decompression of cord, stabilization, and restoration of vertebral height, and there is statistically significant kyphotic correction, pain relief (visual analogue scale), but there is no statistically significant neurological and functional outcome than traditional posterior approach. Most neurosurgeons are familiar to posterior approach; hence, they should be used in unstable thoracolumbar fracture whenever needed, while avoiding various dreaded complication of combined approach.

Keywords

- ▶ traumatic thoracolumbar fracture
- ▶ spinal injuries
- ▶ three-column fixation
- ▶ transpedicular corpectomy
- ▶ posterior only approach

Introduction

Thoracolumbar fracture is most common because it is uniquely positioned between rigid thoracic spine and

mobile lumbar spine. Most authors agreed for surgical management of unstable thoracolumbar fracture, but choice of approach is still a matter of debate. Traditional posterior

approach is preferred because of less complication rate and less complexity of surgery. Posterior approach has disadvantage of insufficient spinal canal decompression, less stable construct, and more chances of recurrent kyphosis. To overcome these disadvantages, anterior approach and later on combined anteroposterior approaches were developed. Access to thoracolumbar vertebral bodies or discs via traditional transthoracic or retroperitoneal approaches carries significant morbidity.^{1,2} Additional posterior stabilization or decompression is often required, thus further increasing the risks of the operation.^{3,4} Single-stage three-column fixation through posterior approach has been described in an attempt to simplify the surgical approach for circumferential decompression and simultaneous stabilization of the thoracolumbar spine.⁵⁻¹³ Many studies were done to compare anterior approach and combined anteroposterior approach with posterior approach but no study was done to compare combined anteroposterior decompression and stabilization through posterior only approach versus traditional posterior approach.

In the present study, we attempt to compare single stage three-column fixation through posterior approach with traditional posterior approach in terms of surgical, neurological, and functional outcome.

Method

Patients

This is retrospective study comprising 47 patients of traumatic thoracolumbar fracture admitted between September 2016 and January 2018 in neurosurgery ward of Dr. Ram Manohar Lohia Institute of Medical Sciences, Lucknow. Inclusion criteria include patients who were adult and diagnosed as a case of unstable thoracolumbar fracture, underwent either single stage three-column fixation through posterior approach or traditional posterior approach. Posterior approach includes short-segment fixation including fracture segment (SSF IFS) and long-segment fixation (LSF). Patients were undergone either of surgery depending on implant availability in the operating room.

Preoperative Assessment

Fracture was classified according to modified AO classification. Neurological assessment of all patients was done with ASIA impairment scale, assessment of pain was done with visual analogue scale (VAS), functional assessment was done with lower extremities functional score, and kyphosis was measured with Cobb's angle.

Operative Procedure

In the single-stage three-column fixation through posterior approach, under general anesthesia and prone position, midline longitudinal incision was taken. Bilateral fascia and muscle were dissected till transverse process one level above and below the fracture segment. The lamina of the fractured vertebrae and the lamina of the cranial vertebrae were removed to expose the pedicles of the fractured vertebrae. Discectomies were performed one level above and one level

below the fractured vertebrae to expose the end plates. The pedicles of the fractured vertebrae were exposed completely. Unilateral or bilateral pedicular resection was achieved based on anterior compression. We routinely performed only one side pedicular resection as optimum anterior decompression and cage placement can be achieved unilaterally. Through the resected pedicle, the posterior two-thirds of the fractured vertebra were totally removed with a high-speed drill and hand curettes. To protect the dura while drilling, a thin layer of cortex was left posteriorly which was broken with curved curette later on. Anterior decompression of the dura was achieved. Superior and inferior disc spaces were cleared with curved hand curettes and end plates prepared. Anterior part of the fractured vertebrae was kept intact, but a space for putting expandable cage was formed within the fractured vertebrae. Pedicular screws were introduced into the upper and lower vertebrae and distraction was applied to assist the entrance of the expandable cage. The expandable cage, filled with autologous bone graft, was inserted into the fractured vertebrae through the resected pedicle. The nerve root exiting through the inferior foramen was protected during placement of the cage. Cage was distracted so that it settles optimally on the end plates. The distraction of the cage was guided by preoperative anteroposterior and lateral fluoroscopic image. Finally, pedicular screws were loosened and fixed again in compression. The autologous cancellous bone chips were embedded over the decorticated posterolateral gutter to augment fusion (► Figs. 1 and 2).

For traditional pedicle screw fixation, pedicle screw was placed one level above and one level below including fracture segment and posterior decompression was done in SSF IFS method (► Fig. 3). In LSF method, pedicle screw was placed two levels above and two levels below the fracture segment (► Fig. 4).

Duration of surgery, intraoperative average blood loss is noted in each surgery.

Follow-Up

All patients were discharged on seventh day after stitch removal. Postop X-ray at 1 week and 3 months was done. Postoperatively, AIS, VAS, LEFS, and kyphotic angle was noted in all patients at seventh day and 3 months. To decrease bias in neurological and functional assessment, parameters were not measured in immediate postoperative days.

Data Analysis

Patient data were analyzed using STATA-12 Software. Unaired student *t*-test and Kruskal-Wallis nonparametric test were used for statistical analysis.

Results

Three patients had injury due to fall from height, while 17 patients had road traffic accident (► Table 1). Out of 47 patients, 33 patients were operated through traditional posterior approach and 13 patients were operated through single stage three-column fixation through posterior only approach. In traditional approach, 21 patients were

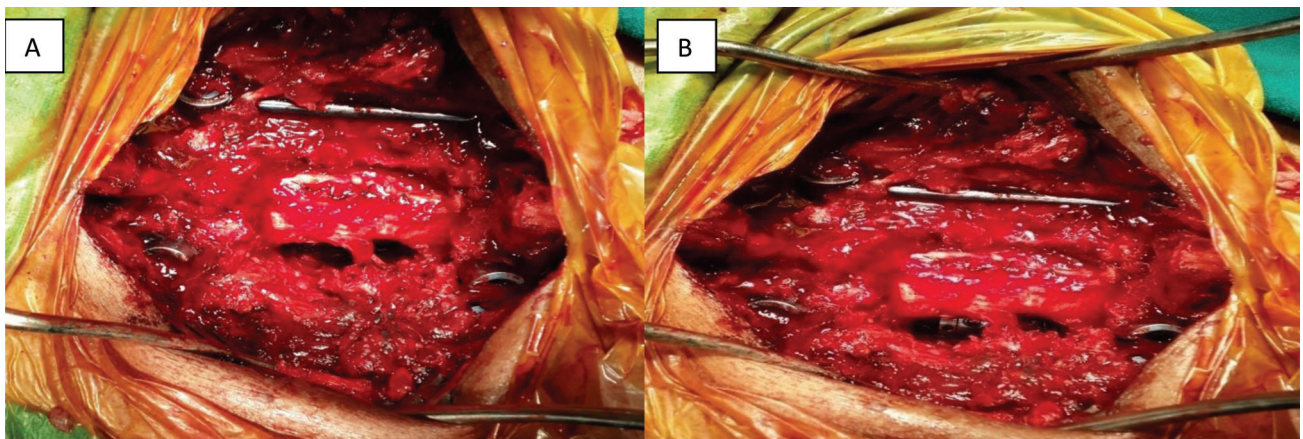


Fig. 1 (A) Posterior laminectomy with transpedicular anterior decompression of cord with placement of pedicle screw and opposite side rod fixation. Posterolateral gutter is made for distractible cage. (B) Distractible cage is placed.

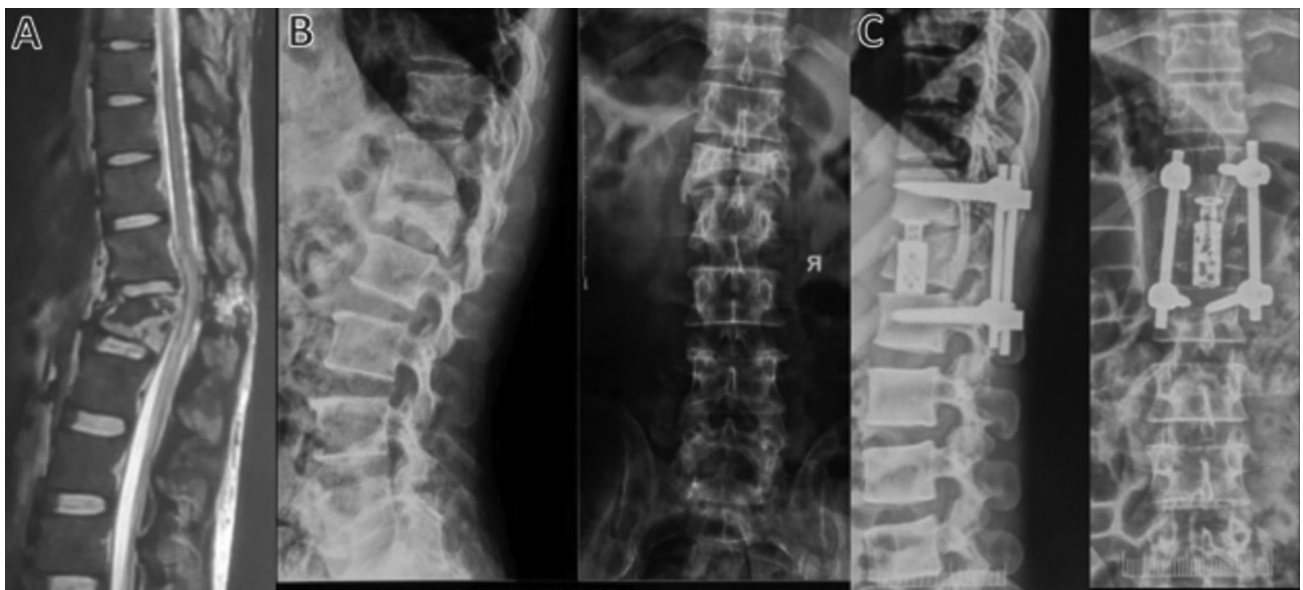

Fig. 2 Combined decompression and stabilization through posterior only approach: (A) Preoperative magnetic resonance imaging, (B) preoperative X-ray, and (C) postoperative X-ray.

operated using SSF IFS method and 12 patients were operated using LSF.

The mean age of patients treated through traditional approach is 38 ± 2.6 (standard deviation [SD]) years, whereas it is 32.9 ± 3.0 (SD) years in single-stage three-column fixation approach (combined). Out of 33 patients, those operated with traditional approach, 30 patients are male and 3 patients are female, whereas out of 14 patients operated with combined approach, 10 patients are male and 4 patients are female (**Table 2**). Overall L1 vertebrae fracture is most common in our study (**Table 1**). In traditional approach, most commonly patient with L1 fracture is operated, that is, 17 out of 33 patients, whereas patient with D12 level fracture is most commonly operated with three-column fixation approach, that is, 7 out of 14 patients (**Table 2**). Most common fracture type is AO class A4 in both approaches followed by AO class A3 in traditional approach and AO class B3 and C in combined approach (**Table 2**).

Changes in neurological and functional status of in two groups were compared at preoperative state, 1 week and 3 months postoperatively (**Table 3**). The median change in AIS score at third month observed in traditional approach is 1 (IQR 0.1) and that observed in combined approach is 1.04 (interquartile range [IQR] 0.1). This difference was found to be statistically nonsignificant ($p = 0.991$). (Kruskal–Wallis test nonparametric test) The median change in LEFS score at third month observed in traditional approach is 34 (IQR 22.46) and that observed in combined approach is 38 (IQR 32.50) (**Table 3**). This difference was found to be statistically nonsignificant ($p = 0.561$) (Kruskal–Wallis test nonparametric test).

The mean VAS score at third month in subjects treated with traditional approach was 1.8 ± 0.61 whereas in subjects treated with combined approach the mean VAS score was 1 ± 0.39 (**Table 4**). The difference in VAS scores observed at third month was found to be statistically significant ($p < 0.001$).

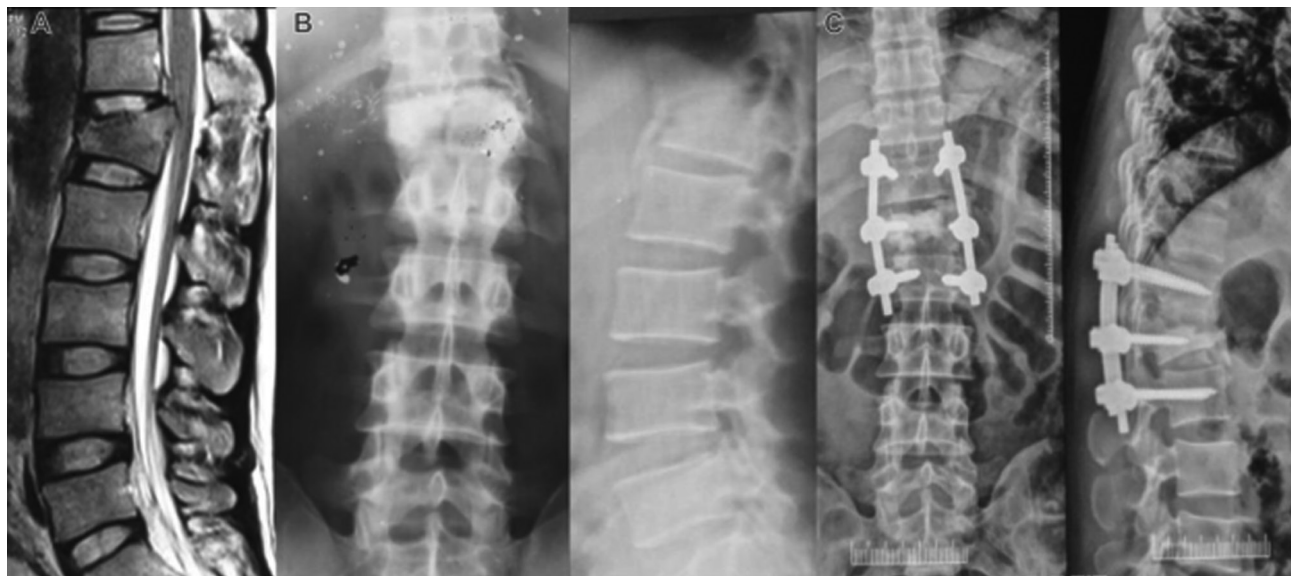

Fig. 3 Short-segment fixation including fracture segment (SSF IFS): (A) Preoperative magnetic resonance imaging, (B) preoperative X-ray, and (C) postoperative SSF IFS.

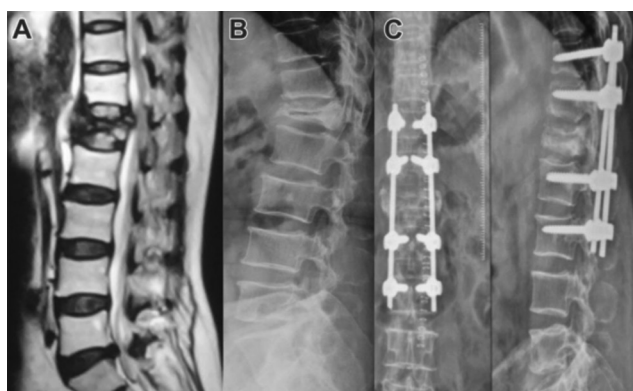


Fig. 4 Posterior approach long-segment fixation (LSF): (A) Preoperative magnetic resonance imaging, (B) preoperative X-ray, and (C) postoperative LSF.

In traditional surgeries, there was an observed correction of $11.73^\circ \pm 3.6^\circ$ in kyphosis, while in combined surgeries the observed correction in kyphosis was $15.36^\circ \pm 4.25^\circ$ (► **Table 4**). This difference was found to be statistically significant ($p = 0.004$) (unpaired student *t*-test).

In traditional approach, there was an observed average blood loss of 108 ± 27.32 mL, while in combined approach the observed average blood loss was 263 ± 40.84 mL (► **Table 5**). This difference was found to be statistically significant ($p = 0.001$).

Likewise, in traditional approach, there was an observed duration of surgery 120.3 ± 25.43 minutes, while in combined approach the observed duration of surgery was 150 ± 13.01 minutes (► **Table 5**). This difference was found to be statistically significant ($p = 0.002$).

Intraoperatively, dural tear was found in two patients which was repaired successfully. No other complications related to

Table 1 Patient-related parameters

	No of patient (%)
Age (in years)	
10–20	10 (21.3)
20–30	10 (21.3)
30–40	8 (17.0)
40–50	7 (14.9)
>50	12 (25.5)
Sex	
Male (M)	40 (85.1)
Female (F)	7 (14.9)
# Level	
D11	1 (2.1)
D12	19 (40.43)
D12, L1	2 (4.26)
L1	22 (46.81)
L2	3 (6.4)
Mode of injury	
FFH	30 (63.81)
RTA	17 (36.81)
Type of # (AO classification)	
A3	10 (21.28)
A4	21 (44.7)
B2	4 (8.6)
B3	6 (12.8)
C	6 (12.8)

Abbreviations: FFH, fall from height; RTA, road traffic accident.

Table 2 Patient-related parameters according to surgical approach

Characteristics	Surgical approach		p-Value
	Traditional	Combined	
Mean age \pm SE (in years)	41.0 \pm 2.6 years	22.9 \pm 3.0 years	$p < 0.001$
Sex (M/F)	M = 30, F = 3	M = 10, F = 4	$p = 0.086$
Fracture level			
D11	1	0	
D12	12	7	
D12, L1	2	0	
L1	17	5	
L2	1	2	
Fracture type (AO class)			
A3	10	0	
A4	12	9	
B2	3	1	
B3	4	2	
C	4	2	

Abbreviations: AO, Association for the Study of Internal Fixation; SE, standard error

Table 3 Changes in neurological and functional outcome

	Preoperative		Postoperative at 1 week		Postoperative at 3 Months	
	Traditional	Combined	Traditional	Combined	Traditional	Combined
AIS (ASIA impairment scale)						
A	2	0	1	0	2	1
B	10	7	7	5	4	2
C	6	4	10	5	5	4
D	14	3	14	4	13	6
E	1	0	1	0	9	1
VAS						
1–3 (mild pain)	0	0	26	12	33	14
3–7 (moderate pain)	1	0	7	2	0	0
7–10 (severe pain)	32	14	0	0	0	0
LEFS (changes in score)						
<10			10	6	2	1
10–20			18	4	4	2
20–30			5	4	8	0
30–40			0	0	7	6
>40			0	0	12	5

Abbreviations: AIS, Asia Impairment Scale; ASIA, American Spinal Injury Association; LEFS, Lower Extremity Functional Scale.

operative site infection or implant failure were reported in immediate postop period and at 3 months follow-up.

Discussion

The approach which gives maximum benefit to the patient of traumatic thoracolumbar fracture is still the matter of

debate. Several research article and meta-analysis were published, but no study favors one over other. Few studies were done for comparing combined approach versus posterior approach. Till date no study was done to compare combined anteroposterior decompression with stabilization through posterior only approach versus traditional posterior decompression with stabilization.¹⁴⁻¹⁸

Table 4 VAS score and Kyphosis correction observed at 3 months after surgery

	Traditional posterior	Combined posterior only	p-Value
VAS score (mean \pm SD)	1.85 \pm 0.61	1.0 \pm 0.39	0.0001
Kyphotic correction at 3 months in degree (mean \pm SD)	11.73 \pm 3.60	15.36 \pm 4.25	0.0045

Abbreviations: SD, standard deviation; VAS, visual analogue scale.

Table 5 Average blood loss and duration of surgery

	Traditional posterior	Combined posterior only	p-Value
Blood loss	108 \pm 27.32 mL	263 \pm 40.84 mL	0.0001
Duration of surgery	120.3 \pm 25.43 minutes	150 \pm 13.01 minutes	0.0002

A meta-analysis was done by Oprel et al to compare combined anteroposterior surgery versus posterior surgery for thoracolumbar fractures to identify better treatment.¹⁸ They concluded that a small significantly higher kyphotic correction and improvement in vertebral height observed for the combined anteroposterior group is cancelled out by more blood loss, longer operation time, longer hospital stay, higher costs, and a possible higher intra- and postoperative complication rate requiring reoperation. The surgeons' choices regarding the operative approach are biased: worse cases tended to undergo the combined anteroposterior approach.

A prospective multicenter study done by Knop et al and a retrospective study done by Been and Bouma to compare combined approach versus posterior approach show similar results.^{15,19} In these studies, combined method showed comparative high blood loss, longer operation time, longer hospital stay, higher costs, and a possible higher intra- and postoperative complication rate because of anterior approach. In our study, these complications and morbidity mostly associated with anterior approach are not found because combined decompression and stabilization were done through posterior only approach.

Our study shows kyphosis correction at 3 months is more in three-column fixation than traditional posterior approach. It shows that on 3-month follow-up examination, loss of correction is smaller in three-column fixation than traditional posterior approach as seen in previous studies on anterior and combined approach. Four case series on combined decompression and stabilization through posterior only approaches in patients of traumatic thoracolumbar fracture concluded that significant correction in kyphosis and nonsignificant loss of kyphotic correction.¹⁰⁻¹³

Postoperatively, pain on VAS score was significantly improved in both approaches, but it is significantly reduced in combined decompression through posterior only approach at 3 months than traditional posterior approach.

Our study showed that both traditional posterior approach and combined decompression and stabilizations through posterior only approach were equally effective when the neurological (AIS), functional (LEFS) parameters were compared. There were no differences in the neurological or functional outcome as concluded in other studies.

We found lower blood loss and shorter operation time in traditional posterior approach surgery than the three-column fixation through posterior only approach. This is expected because of additional procedure in the combined approach.

Anterior neurodecompression still remains the practice in many institutions, as experimental data have shown that early neurodecompression is crucial for regeneration of nerve tissue.⁹ Our results showed that the choice of three-column fixation through posterior only approach or posterior approach for decompression did not influence the neurological or functional outcome; however, neurological and functional improvements were seen in each patient. This might be because more severely injured and higher AIS grade patients tend to get operated through combined decompression method through posterior only approach.

The limitations of the study were the relatively small study size and unusual allocation of the patients into groups. Patients were divided into two trial groups according to the implants available in the operating theater at the time of the patient's admission. The lack of funds was the reason why implants for combined surgery (expandable cage) were rarely available. On the other hand, these circumstances favor traditional posterior approach fixation, which is preferred technique in our institution.

The next step should be a prospective randomized controlled trial of longer follow-up with proper supply of needed implants.

Conclusion

Combined anteroposterior decompression and stabilization through posterior only approach is convenient for complete decompression of cord, stabilization, and restoration of vertebral height, and there is statistically significant kyphotic correction, pain relief (VAS) but there is no statistically significant neurological and functional outcome than traditional posterior approach. Most neurosurgeons are familiar to posterior approach; hence, it should be used in unstable thoracolumbar fracture whenever needed, while avoiding various dreaded complication of combined approach.

Conflicts of Interest

There are no conflicts of interest.

Acknowledgment

Dr. Arvind Kumar Singh from the Department of PSM has done statically data analysis.

References

- 1 Wood KB, Li W, Lebl DR, Ploumis A. Management of thoracolumbar spine fractures. *Spine J* 2014;14(1):145–164
- 2 el-Khoury GY, Whitten CG. Trauma to the upper thoracic spine: anatomy, biomechanics, and unique imaging features. *AJR Am J Roentgenol* 1993;160(1):95–102
- 3 McDonnell MF, Glassman SD, Dimar JR II, Puno RM, Johnson JR. Perioperative complications of anterior procedures on the spine. *J Bone Joint Surg Am* 1996;78(6):839–847
- 4 Lu DC, Lau D, Lee JG, Chou D. The transpedicular approach compared with the anterior approach: an analysis of 80 thoracolumbar corpectomies. *J Neurosurg Spine* 2010;12(6):583–591
- 5 Akeyson EW, McCutcheon IE. Single-stage posterior vertebrectomy and replacement combined with posterior instrumentation for spinal metastasis. *J Neurosurg* 1996;85(2):211–220
- 6 Cahill DW, Kumar R. Palliative subtotal vertebrectomy with anterior and posterior reconstruction via a single posterior approach. *J Neurosurg* 1999;90(1, Suppl):42–47
- 7 Johnston FG, Uttley D, Marsh HT. Synchronous vertebral decompression and posterior stabilization in the treatment of spinal malignancy. *Neurosurgery* 1989;25(6):872–876
- 8 Magerl F, Coscia MF. Total posterior vertebrectomy of the thoracic or lumbar spine. *Clin Orthop Relat Res* 1988;(232):62–69
- 9 Steffee AD, Sitkowski DJ, Topham LS. Total vertebral body and pedicle arthroplasty. *Clin Orthop Relat Res* 1986;(203):203–208
- 10 Rahman Md A, Das S, Amin R, Hossain M, Barua KK. Transpedicular screw fixation for the treatment of thoracolumbar spine fracture. *Bangabandhu Sheikh Mujib Medical University Journal* 2017;10(2):112
- 11 Singh DK, Singh N, Kumar R, Mewara D, Malviya D. Thoracolumbar fractures: Three column stabilization through posterior only approach. *Interdisciplinary Neurosurgery* 2016;4:1–5
- 12 Ayberk G, Ozveren MF, Altundal N, et al. Three column stabilization through posterior approach alone: transpedicular placement of distractable cage with transpedicular screw fixation. *Neurol Med Chir (Tokyo)* 2008;48(1):8–14, discussion 14
- 13 Wong ML, Lau HC, Kaye AH. A modified posterolateral transpedicular approach to thoracolumbar corpectomy with nerve preservation and bilateral cage reconstruction. *J Clin Neurosci* 2014;21(6):988–992
- 14 Gertzbein SD, Scoliosis Research Society. Scoliosis Research Society. Multicenter spine fracture study. *Spine* 1992;17(5):528–540
- 15 Knop C, Reinhold M, Roeder C, et al. Internet based multicenter study for thoracolumbar injuries: a new concept and preliminary results. *Eur Spine J* 2006;15(11):1687–1694
- 16 Rajaraman V, Vingan R, Roth P, Heary RF, Conklin L, Jacobs GB. Visceral and vascular complications resulting from anterior lumbar interbody fusion. *J Neurosurg* 1999;91(1 Suppl):60–64
- 17 Kim MS, Eun JP, Park JS. Radiological and clinical results of laminectomy and posterior stabilization for severe thoracolumbar burst fracture: surgical technique for one-stage operation. *J Korean Neurosurg Soc* 2011;50(3):224–230
- 18 Opriel P, Tuinebreijer WE, Patka P, den Hartog D. Combined anterior-posterior surgery versus posterior surgery for thoracolumbar burst fractures: a systematic review of the literature. *Open Orthop J* 2010;4:93–100
- 19 Been HD, Bouma GJ. Comparison of two types of surgery for thoraco-lumbar burst fractures: combined anterior and posterior stabilisation vs. posterior instrumentation only. *Acta Neurochir (Wien)* 1999;141(4):349–357