

Trigeminal Cave Brain Metastasis from Prostate Adenocarcinoma: Case Report and Review of the Literature

Metástase cerebral em cavo trigeminal de um adenocarcinoma de próstata: relato de caso e revisão de literatura

João Pedro Zanatta¹ Laisa Zanella¹ Guilherme Soldatelli Teixeira Kurtz¹ Bárbara Biffi Gabardo²
Alex Roman³ Júlia Pastorello⁴

¹ Faculty of Medicine, Universidade de Passo Fundo, Passo Fundo, RS, Brazil

² Faculty of Medicine, Centro Universitário Assis Gurgacz, Cascavel, PR, Brazil

³ Department of Neurosurgery, Hospital da Cidade de Passo Fundo, Passo Fundo, RS, Brazil

⁴ Department of Oncology, Hospital da Cidade de Passo Fundo, Passo Fundo, RS, Brazil

Address for correspondence João Pedro Zanatta, Av Barão do Rio Branco, 260, Marau, RS, CEP 99150-000 (e-mail: jp_zanatta@hotmail.com).

Arq Bras Neurocir 2018;37:330–333.

Abstract

The present study presents the case of a 66-year-old patient diagnosed with prostate adenocarcinoma 4 years earlier and treated with prostatectomy, radiotherapy, chemotherapy and hormone therapy but still displaying high prostate-specific antigen (PSA) levels. The patient complaints were double vision and headaches. Upon physical examination, he displayed 6th cranial nerve paresis and 5th cranial nerve paresthesia. A magnetic resonance imaging (MRI) exam was performed, which revealed a mass on the right trigeminal cave. The patient underwent surgical removal of the tumor, and the pathological analysis of the specimen established metastatic prostate cancer as the diagnosis.

Brain metastases from prostate cancer are extremely rare and mark advanced disease, with immune system failure and blood-brain barrier breach. Prostate-specific antigen levels do not correlate with the possibility of metastatic disease. Prostate adenocarcinoma is the histologic type most commonly associated with brain metastases, with the meninges being more frequently affected, followed by the brain parenchyma. The neurological symptoms more often displayed are non-focal, such as headaches and mental confusion. Surgery associated with radiotherapy is the most validated treatment.

Keywords

- meckel cave
- metastatic prostate cancer
- skull base tumor

Resumo

O presente estudo apresenta o caso de um paciente de 66 anos, há 4 anos diagnosticado com adenocarcinoma de próstata e tratado com prostatectomia, radioterapia, quimioterapia e hormonioterapia, porém mantendo elevados níveis de antígeno específico de próstata (PSA, na sigla em inglês). Inicialmente, o paciente se queixou de diplopia e cefaléia. Ao exame físico, apresentava paresia do 6° nervo craniano e parestesia do 5° nervo craniano. Foi realizada uma ressonância magnética,



Palavras-chave

- cavo de meckel
- câncer de próstata metastático
- tumor de base de crânio

em que foi observado um tumor no cavo trigeminal do lado direito. O paciente foi submetido a uma neurocirurgia e a análise anatomopatológica evidenciou carcinoma prostático metastático.

As metástases cerebrais de câncer de próstata são extremamente raras e indicam doença avançada, com falha do sistema imune e da barreira hematoencefálica. O valor de PSA não está relacionado com a ocorrência de metástases. O tipo histológico mais comum às metástases cerebrais é o adenocarcinoma, e o principal sítio de acometimento são as meninges, seguidas pelo parênquima cerebral. Os sintomas neurológicos mais comuns são não focais, como cefaleia e confusão mental. O tratamento mais validado é cirurgia associada à radioterapia.

Introduction

Brain metastasis occurs in 25% of cancer patients, most commonly from melanoma, lungs, breast or kidney carcinoma.¹ Metastatic disease in the central nervous system (CNS) is rare in cases of prostate cancer. The frequency of brain metastasis seen in autopsies from patients diagnosed with prostate cancer is very low,² and *in vivo* intracranial metastases are diagnosed only 0.1% of the time, with the trigeminal cave impairment being even rarer.

Case Presentation

A 66-year-old patient diagnosed with prostate adenocarcinoma 4 years earlier and treated with prostatectomy, radiotherapy, chemotherapy and hormone therapy but still displaying high prostate-specific antigen (PSA) levels (2,396 ng/ml) presented new symptoms of double vision and holocranial headache. Upon examination, the patient displayed 6th cranial nerve paresis and 5th cranial nerve paresthesia. The remaining cranial nerves did not display any alteration. A head magnetic resonance imaging (MRI) revealed a contrast-enhanced expanding lesion on the right trigeminal cave, measuring 2.3 × 1.5 cm, seemingly infiltrating the meninges, probably representing a meningioma. (–Fig. 1)

The lesion was removed through right cerebellopontine angle microsurgery, and the immunohistochemistry analysis of the surgical specimen revealed positive pan cytokeratin and PSA antibody stain metastatic carcinoma, thus establishing the diagnosis. The patient recovered well from the procedure, with resolution of the neurological symptoms.

Discussion

According to the National Cancer Institute (INCA, in the Portuguese acronym), prostate cancer is the second most common type of cancer among men in Brazil, with an estimation of 68,220 new cases in 2018.⁴ Roughly 80% of patients receive a diagnosis through tissue biopsy, performed due to high PSA levels in the absence of symptoms. Prostate cancer metastasis occurs mainly in the bones, lungs and liver, with the brain being a rare site of dissemination.⁵ Prostate cancer CNS metastases have a 0.6 to 4.4% prevalence in autopsies, and in most cases comprise meningeal involve-

ment (67%), followed by brain (25%) and, to a lesser degree, cerebellar disease (8%).^{5,6} In living subjects, CNS prostate cancer metastases account for less than 0.1% of cases.³ The longer life-expectancy due to new treatments for patients with prostate carcinoma, associated with a rising incidence of this kind of cancer, indicate a likely increase in cases of CNS metastases related to the disease.⁷

The rising PSA levels of our patient do not correlate with the development of CNS metastasis;^{6,8} however, adenocarcinoma histologic type, as presented in this report, has a greater rate of incidence of this kind of dissemination compared with the small-cell carcinoma type.

Concerning the pathophysiology of CNS prostate cancer dissemination, it is known that the prostate neoplastic cells have little affinity to brain tissue. Thus, the occurrence of metastasis in this site is believed to take place in the late-stage disease context of immunological failure and blood-brain barrier breaching.^{5,9} Our patient had a late-stage prostate cancer, diagnosed 4 years before the metastasis that was resistant to sequential lines of treatment.

The distribution of brain metastases in prostate cancer is similar to other neoplastic diseases, with the supratentorial region being more frequently inflicted than the infratentorial, on a 3:1 ratio. This may be thanks to greater blood supply to the supratentorial compartment.¹⁰ Late-stage prostate cancer CNS dissemination routes include direct involvement through a cranial lesion expansion, lymphatic or hematologic dissemination.¹⁰ In our case, the patient presented with a metastatic lesion in the supratentorial region on the right cerebellopontine angle, making it possible to infer that the metastatic disease developed through hematologic dissemination.

The trigeminal cave impairment due to neoplastic disease arises mainly from meningiomas, schwannomas and metastasis.¹¹ Reports from Soni CR et al show a subtle clinical differentiation between them. Malignant tumors involving Meckel's Cave displayed greater trigeminal motor and sensitive involvement, which manifests itself as pain (76% of the time) and paresthesia (67%), while benign neoplasms displays less pain (23%) and also less paraesthesia (36%). Nevertheless, only anatomopathological analysis can confirm the diagnosis.¹²

Neurological manifestations vary, with non-focal symptoms being the most common presentation. Headaches, altered mental status, memory deficits, double vision associated to 3rd, 4th and 6th cranial nerve palsy, motor deficit and

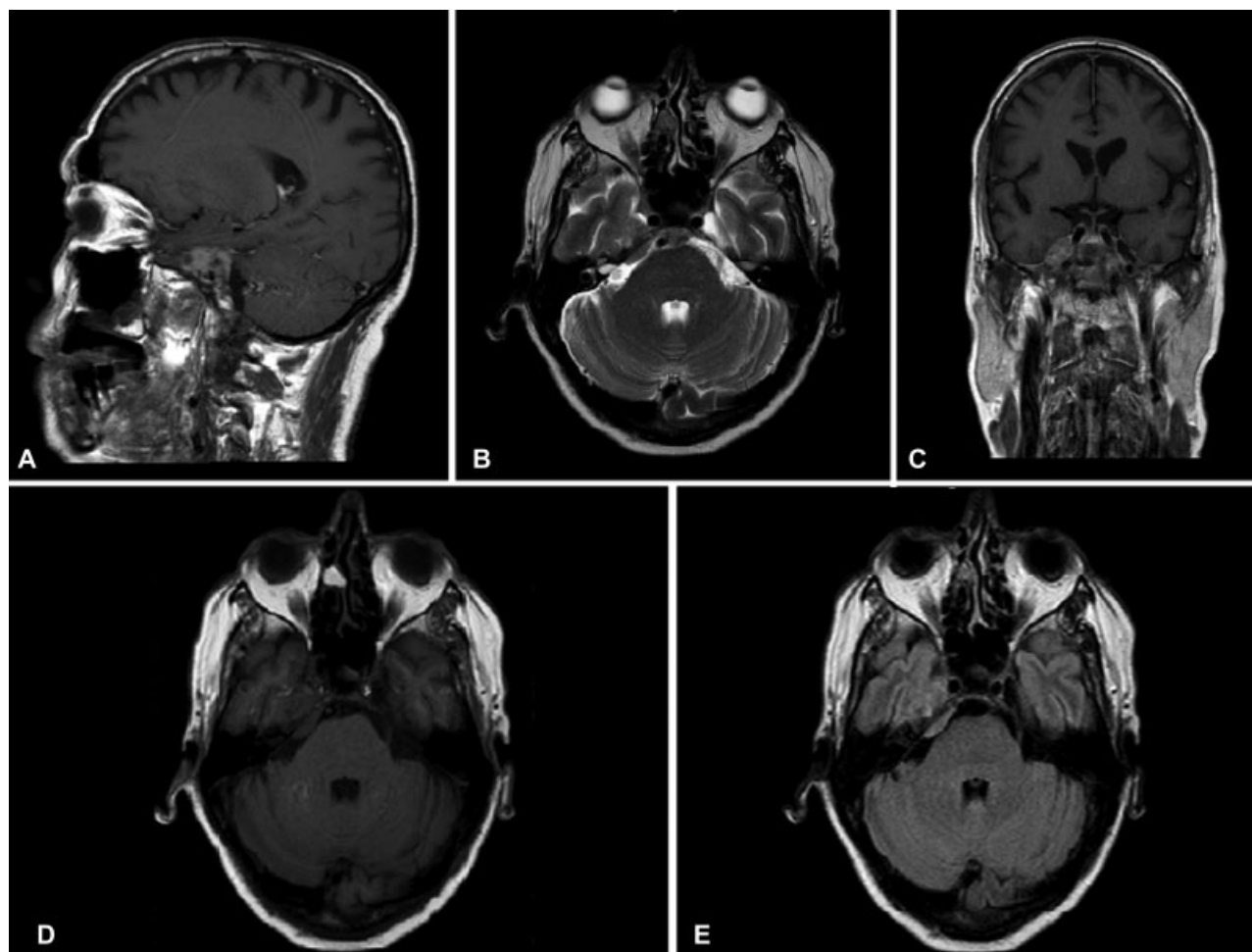


Fig. 1 Preoperative magnetic resonance imaging (MRI) evaluation. In this, we observed an expansive lesion at the root of the trigeminal nerve, in the trigeminal cave. (A) T1 weighted imaging (T1WI) postgadolinium MRI, sagittal view; (B) T2 weighted imaging postgadolinium, axial view; (C) T1WI postgadolinium MRI, coronal view; (D) T1WI MRI, axial view; (E) Axial fluid-attenuated inversion recovery (FLAIR).

intracranial bleeding are the main symptoms.^{1,2,6,13} Our patient, due to the trigeminal cave extension of the disease, displayed, initially, headache, double vision, 6th cranial nerve paresis and 5th cranial nerve paresthesia.

Validated treatments for intracranial metastasis include neurosurgery, radiotherapy and hormone therapy. Besides these, Kohri et al¹⁴ reported good results with administration of estramustine phosphate sodium. Currently, there is a lack of clinical trials suggesting the best therapeutic scheme for prostate cancer brain metastasis. However, there is a greater propensity to opt for surgery in conjunction with radiotherapy, as in other kinds of metastasis.^{2,13}

Untreated patients have a 1, up to 2, months life expectancy, and, taking into account the available evidence, the combination of surgery and radiotherapy seems to ensure the greatest increments in patient longevity, even in a poor prognosis multiple metastasis scenario. Patients treated this way die predominantly from systemic illness, and the brain impairment seems controlled.¹³ The patient presented in this case received optimized treatment with chemotherapy and hormone therapy and underwent neurosurgery to resect the metastatic disease and is still being followed up.

Conclusion

The possibility of CNS metastatic disease should be considered in patients with late-stage prostate carcinoma that present neurological symptoms. The best treatment for metastasis is still debatable; however, the association of surgery and radiotherapy seems to be the best option at present.

References

- 1 Chiang P-H, Lee T-C, Huang C-C. Intracranial metastasis of prostate cancer: report of two cases. *Chang Gung Med J* 2004;27(10): 770–776
- 2 Tremont-Lukats IW, Bobustuc G, Lagos GK, Lolas K, Kyritsis AP, Puduvalli VK. Brain metastasis from prostate carcinoma: The M. D. Anderson Cancer Center experience. *Cancer* 2003;98(02):363–368
- 3 Zhang X, Tsukuda F, Yamamoto N, Takenaka I. Brain metastasis from prostate cancer: a case report. *Int J Urol* 1997;4(05):519–521 <http://www.ncbi.nlm.nih.gov/pubmed/9354958> [Internet]
- 4 MINISTÉRIO DA SAÚDE, Instituto Nacional de Câncer José Alencar Gomes da Silva. Estimativa 2018-Incidência de câncer no Brasil. 2017. 130 p.
- 5 Sutton MA, Watkins HL, Green LK, Kadmon D. Intracranial metastases as the first manifestation of prostate cancer. *Urology* 1996; 48(05):789–793

- 6 Fervenza FC, Wolanskyj AP, Eklund HE, Richardson RL. Brain metastasis: an unusual complication from prostatic adenocarcinoma. *Mayo Clin Proc* 2000;75(01):79–82. Doi: 10.4065/75.1.79 [Internet]
- 7 McCutcheon IE, Eng DY, Logothetis CJ. Brain metastasis from prostate carcinoma: antemortem recognition and outcome after treatment. *Cancer* 1999;86(11):2301–2311<http://www.ncbi.nlm.nih.gov/pubmed/10590371>[Internet]
- 8 Erasmus CE, Verhagen WIM, Wauters CA, van Lindert EJ. Brain metastasis from prostate small cell carcinoma: not to be neglected. *Can J Neurol Sci* 2002;29(04):375–377
- 9 Delattre JY, Krol G, Thaler HT, Posner JB. Distribution of brain metastases. *Arch Neurol* 1988;45(07):741–744<http://archneur.jamanetwork.com/article.aspx?articleid=587837>[Internet]
- 10 Kunkler RB, Cooksey G, Millac P. Carcinoma of the prostate presenting with a cerebral metastasis. *Br J Urol* 1993;71(01):103–104
- 11 Gasco J, Kew Y, Livingston A, Rose J, Zhang YJ. Dissemination of prostate adenocarcinoma to the skull base mimicking giant trigeminal schwannoma: anatomic relevance of the extradural neural axis component. *Skull Base* 2009;19(06):425–430
- 12 Soni CR, Kumar G, Sahota P, Miller DC, Litofsky NS. Metastases to Meckel's cave: report of two cases and comparative analysis of malignant tumors with meningioma and schwannoma of Meckel's cave. *Clin Neurol Neurosurg* 2010;112(10):927–932<http://www.sciencedirect.com/science/article/pii/S0303846710002337>
- 13 Salvati M, Frati A, Russo N, et al. Brain metastasis from prostate cancer. Report of 13 cases and critical analysis of the literature. *J Exp Clin Cancer Res* 2005;24(02):203–207<http://www.embase.com/search/results?subaction=viewrecord&from=export&id=L41039603>[Internet]
- 14 Kohri K, Yamate T, Tsujihashi H, Nahao Y, Katayama Y, Hara Y, Morikawa Y, Kurita T. Effect of endocrine therapy on a brain metastatic lesion of prostatic carcinoma.