

# Bronchopulmonary Sequestration with Fetal Hydrops in a Monochorionic Twin Successfully Treated with Multiple Courses of Betamethasone

Radovan Pock, MD<sup>1,2,\*</sup> Zbyněk Straňák, MD, PhD<sup>1,2,\*</sup> Jiří Vojtěch, MD<sup>1,2</sup> Lubomír Hašík, MD<sup>1,2</sup>  
Jaroslav Feyereisl, MD, PhD<sup>1,2,3</sup> Ladislav Krofta, MD, PhD<sup>1,2</sup>

<sup>1</sup> Department of Gynaecology and Obstetrics, Third Faculty of Medicine, Charles University, Prague, Czech Republic

<sup>2</sup> Department of Gynaecology and Obstetrics, Fetal Medicine Center, Institute for the Care of Mother and Child, Prague, Czech Republic

<sup>3</sup> Department of Gynaecology and Obstetrics, Institute for Postgraduate Medical Education, Prague, Czech Republic

Address for correspondence Zbyněk Straňák, MD, PhD, Institute for the Care of Mother and Child, Podolské nábřeží 157, 147 00 Prague 4, Czech Republic (e-mail: z.stranak@seznam.cz).

Am J Perinatol Rep 2018;8:e359–e361.

## Abstract

**Aim** We present a case of severe bronchopulmonary sequestration (BPS) and fetal hydrops in one of the monochorionic twin successfully treated with multiple courses of betamethasone.

**Case Report** A 21-year-old gravida 2 para 1 was referred to our hospital for suspected twin-to-twin transfusion syndrome (TTTS) at 28<sup>0/7</sup> weeks of gestational age. However, prenatal ultrasound of the larger twin revealed a chest lesion that was associated with significant ascites, massive hydrothorax, scant hepatomegaly, subcutaneous edema, and severe polyhydramnios. Magnetic resonance imaging confirmed the diagnosis of BPS and fetal hydrops. The estimated fetal weight discrepancy between the fetuses was 39% but the criteria for TTTS were not met. Repeated courses of betamethasone (3 courses, each with 2 × 14 mg of betamethasone intramuscularly/week) were administered with subsequent recovery from hydrops and reduction in BPS parameters. Amniocentesis was performed twice to reduce the amniotic fluid amount in affected twin. Postnatally, surgery of BPS was not required and follow-up at 6 months of corrected age revealed no side effects of antenatal steroids in either twin.

**Conclusion** Antenatal steroids might be considered for noninvasive therapy in high-risk fetal patients with BPS especially when fetal intervention is unsuitable or not available.

## Keywords

- ▶ bronchopulmonary sequestration
- ▶ hydrops
- ▶ monochorionic twins
- ▶ antenatal steroids
- ▶ neonatal outcome

Bronchopulmonary sequestration (BPS) is a congenital anomaly consisting of a nonfunctioning mass of lung tissue that lacks normal communication with the tracheobronchial tree and receives its blood supply from the systemic circulation. Severe BPS is associated with swallowing impairment, polyhydramnios, cardiac, and mediastinal shift causing cardiac failure and nonimmune hydrops. The prognosis of

untreated severe BPS with hydrops is highly unfavorable, with a 95% risk of intrauterine fetal demise.<sup>1,2</sup>

Prenatal treatment options include the use of antenatal steroids, minimally invasive procedures (i.e., radiofrequency ablation, laser coagulation, thrombogenic coil embolization, and thoraco-amniotic shunt), or highly invasive open fetal surgery. The choice of appropriate prenatal management depends on the size of BPS, the presence or absence of hydrops, the presence of associated congenital anomalies

\* These authors contributed equally to this work.



and other specific variables (multiple pregnancy, gestational age, maternal status, etc.).<sup>3-5</sup>

We describe a case of a monochorionic diamniotic twin pregnancy where one of the fetuses was affected with severe BPS and fetal hydrops. Unfavorable access to the affected fetus ruled out potential fetal interventions and accentuated the indication for administering antenatal steroids.

### Case

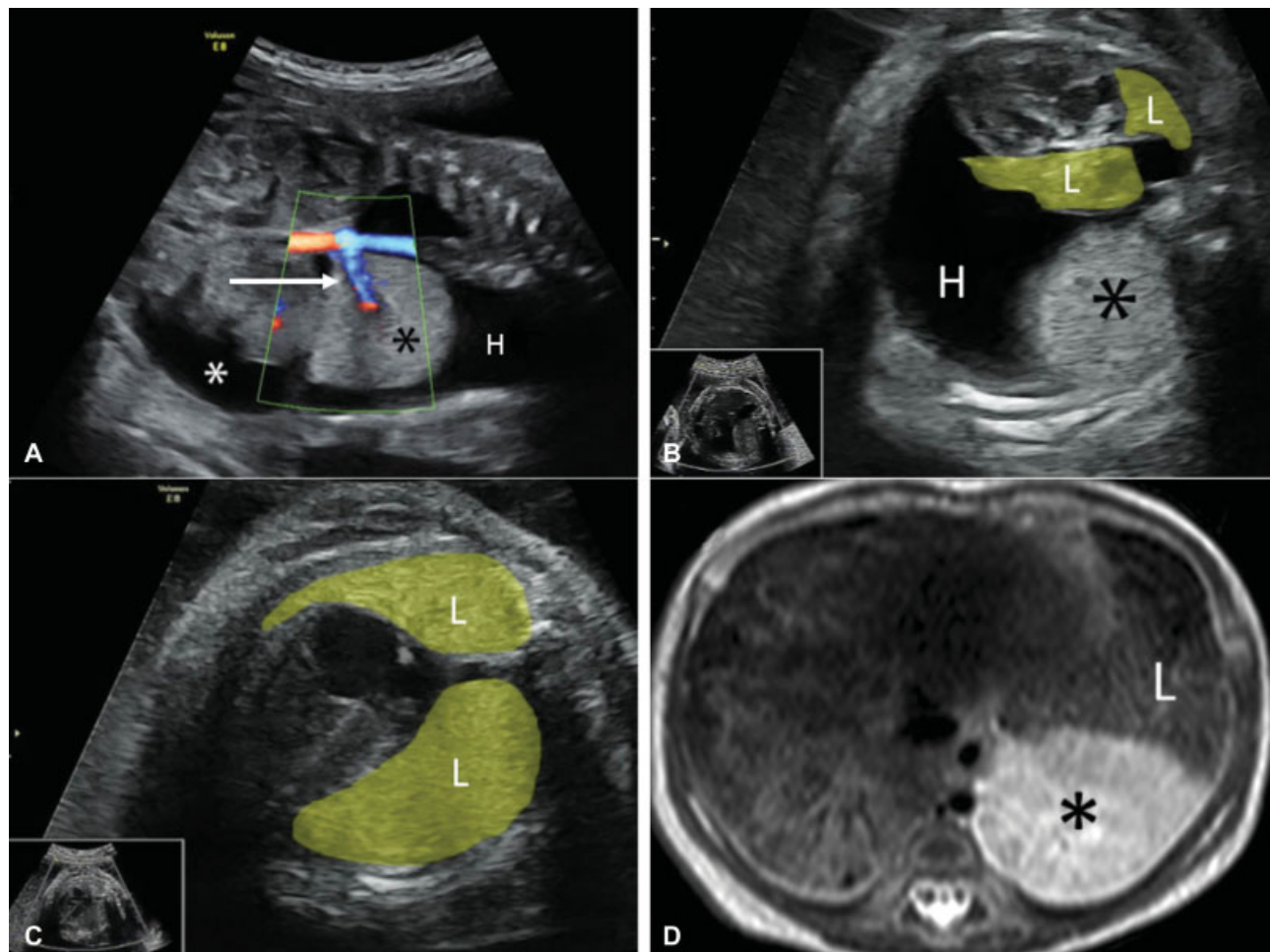
A 21-year-old gravida 2 para 1 was referred to our hospital for suspected twin-to-twin transfusion syndrome (TTTS) at 28<sup>0/7</sup> weeks of gestational age. However, prenatal ultrasound (US) of the larger twin revealed a chest lesion that was associated with significant ascites, massive hydrothorax, scant hepatomegaly, subcutaneous edema, and severe polyhydramnios. Targeted US of the thoracic cavity identified a solid mass (33 × 40 × 30 mm) on the left side with blood supply from the thoracic aorta, collapse of lung tissue, and mediastinal shift to the right (►Fig. 1A and B). Magnetic resonance imaging (MRI) confirmed the diagnosis of BPS and fetal hydrops.

The smaller fetus was not found to have any anomalies. The estimated fetal weight discrepancy between the fetuses was 39%; however, the criteria for TTTS were not met.

In our case, laser coagulation of the feeding vessel was contraindicated for technical reasons (inaccessibility due to anterior placenta). Repeated courses of betamethasone (three courses, each with 2 × 14 mg intramuscularly/week) followed by amniodrainage of 1,000 mL were indicated.

There was remarkable improvement in the affected fetus after the third administration of steroids: no pleural effusion, no mediastinal shift, and a normal size of both lungs (►Fig. 1C). Moreover, the size of the mass decreased to 23 × 28 × 21 mm after antenatal steroids, and it was less distinguishable on US. Among the persisting findings of the affected fetus were discrete ascites, slight myocardial hypertrophy, and polyhydramnios. Thus another amniodrainage was performed after 10 days with removal of 1,300 mL of amniotic fluid.

The twins were delivered by elective cesarean section at 30<sup>2/7</sup> weeks of gestation, due to spontaneous onset and progression of labor.



**Fig. 1** (A) Prenatal ultrasound scan demonstrates extralobar bronchopulmonary sequestration (black.) with feeding vessel (white arrow), hydrothorax (H), and ascites (white.) before treatment. (B) Collapse of lung tissue and mediastinal shift are visible in transverse thoracic image. (C) Expanded lungs (L) are detected after treatment. (D) Magnetic resonance imaging at 3 weeks of age confirmed the presence of bronchopulmonary sequestration (black .).

The birth weight of the affected twin A was 1,340 grams, while that of the smaller twin B was 980 grams, with a discrepancy of 27%. The affected twin A developed severe respiratory distress syndrome (RDS), further complicated by pulmonary hemorrhage and pulmonary hypertension that was successfully treated with inhaled nitric oxide. Shortly after birth, the diagnosis of BPS was confirmed by MRI (► **Fig. 1D**). Targeted neonatal echocardiography confirmed hypertrophic cardiomyopathy that showed spontaneous regression with time. No other congenital abnormalities were found. Later on, twin A suffered from moderate bronchopulmonary dysplasia that required oxygen therapy. The twins were discharged from the hospital on the 68th day of life. So far, twin A has not required surgery for BPS and findings on follow-up were age appropriate. Twin B was doing well throughout the hospitalization, suffering only from mild RDS due to prematurity. No side effects of the treatment with antenatal steroids have been reported in either of the twins at the age of 12 months.

## Discussion

Several studies have described a positive effect of betamethasone treatment in the management of severe congenital pulmonary airway malformation (CPAM) with or without nonimmune hydrops. The administration of antenatal steroids led to resolution of hydrops and reduction of mass size.<sup>6–8</sup> The mechanism of the effect of steroids on CPAM is still not very well understood. We assume that steroids could either stimulate the maturation of lung cells or affect cell proliferation and apoptosis, thus reducing CPAM growth. Current evidence suggests a single course of steroids appears to be a reasonable first-line therapy in cases of large CPAM with hydrops. Moreover, multiple courses of antenatal betamethasone may facilitate stabilization or even regression of CPAM in high-risk patients that do not adequately respond to single dose treatment.<sup>9,10</sup> In contrast, the role of antenatal steroids in BPS fetuses has not yet been explored in detail. Due to the common embryologic basis for CPAM and BPS, we may expect a similar effect of steroids in the reduction of BPS.

Our case is unique in that severe BPS affected one of the monozygotic twins. Unfortunately, limited data are available regarding prenatal management of BPS and hydrops in monozygotic twins specifically. Thus, we opted for the less invasive approach and administered multiple courses of antenatal steroids. Furthermore, we had to consider the risk/benefit ratio of multiple courses of steroids on the unaffected fetus. A recent study demonstrated that repeated courses of steroids may cause reduction in weight, length, and head circumference at birth. However, the risk of death or disability at 5 years of age is similar when compared with a single course.<sup>11,12</sup> Although the unaffected twin had the lower birth weight, it is unclear whether this finding is associated with the multiple courses of antenatal steroids or may have resulted from other intrauterine factors.

The affected infant was born without any clinical signs of hydrops and suffered severe respiratory insufficiency and moderate bronchopulmonary dysplasia more likely due to

prematurity than BPS. Postnatal MRI confirmed extralobar BPS between the inferior lobe and diaphragm in the left thoracic cavity but no signs of generalized edema were found. The infant was discharged with bronchopulmonary dysplasia requiring oxygen therapy and follow-up at 6 months of corrected age showed no respiratory complications, no neurosensory impairment, and confirmed normal growth in both twins. Follow-up will continue to assess their long-term neurodevelopment.

This case suggests the potential positive role of multiple courses of antenatal steroids in the management of BPS and hydrops under very specific circumstances.

## Conflict of Interest

The authors state that there are no conflicts of interest regarding the publication of the article. Informed consent from the legal guardian of the patient was obtained for manuscript submission.

This study was supported by the OPPK CZ.2.16/3.1.00/25015 project (Operational Program Prague, an European Union funding mechanism).

## References

- 1 Khalek N, Johnson MP. Management of prenatally diagnosed lung lesions. *Semin Pediatr Surg* 2013;22(01):24–29
- 2 Cavoretto P, Molina F, Poggi S, Davenport M, Nicolaides KH. Prenatal diagnosis and outcome of echogenic fetal lung lesions. *Ultrasound Obstet Gynecol* 2008;32(06):769–783
- 3 Mathis J, Raio L, Baud D. Fetal laser therapy: applications in the management of fetal pathologies. *Prenat Diagn* 2015;35(07):623–636
- 4 Witlox RS, Lopriore E, Oepkes D. Prenatal interventions for fetal lung lesions. *Prenat Diagn* 2011;31(07):628–636
- 5 Baud D, Windrim R, Kachura JR, et al. Minimally invasive fetal therapy for hydropic lung masses: three different approaches and review of the literature. *Ultrasound Obstet Gynecol* 2013;42(04):440–448
- 6 Morris LM, Lim FY, Livingston JC, Polzin WJ, Crombleholme TM. High-risk fetal congenital pulmonary airway malformations have a variable response to steroids. *J Pediatr Surg* 2009;44(01):60–65
- 7 David M, Lamas-Pinheiro R, Henriques-Coelho T. Prenatal and postnatal management of congenital pulmonary airway malformation. *Neonatology* 2016;110(02):101–115
- 8 Peranteau WH, Wilson RD, Liechty KW, et al. Effect of maternal betamethasone administration on prenatal congenital cystic adenomatoid malformation growth and fetal survival. *Fetal Diagn Ther* 2007;22(05):365–371
- 9 Derderian SC, Coleman AM, Jeanty C, et al. Favorable outcomes in high-risk congenital pulmonary airway malformations treated with multiple courses of maternal betamethasone. *J Pediatr Surg* 2015;50(04):515–518
- 10 Peranteau WH, Boelig MM, Khalek N, et al. Effect of single and multiple courses of maternal betamethasone on prenatal congenital lung lesion growth and fetal survival. *J Pediatr Surg* 2016;51(01):28–32
- 11 Murphy KE, Hannah ME, Willan AR, et al; MACS Collaborative Group. Multiple courses of antenatal corticosteroids for preterm birth (MACS): a randomised controlled trial. *Lancet* 2008;372(9656):2143–2151
- 12 Asztalos EV, Murphy KE, Willan AR, et al; MACS-5 Collaborative Group. Multiple courses of antenatal corticosteroids for preterm birth study: outcomes in children at 5 years of age (MACS-5). *JAMA Pediatr* 2013;167(12):1102–1110