

Black-Colored Ligamentum Flavum Due to Alkaptonuria

Seyho Cem Yucetas¹ Necati Ucler¹

¹Department of Neurosurgery, Adiyaman University, Education and Research Hospital, Adiyaman, Turkey

J Neurol Surg A 2019;80:131–133.

Address for correspondence Necati Ucler, MD, Department of Neurosurgery, Adiyaman University, Education and Research Hospital, 02200, Adiyaman, Turkey (e-mail: necati_ucler@yahoo.com).

Abstract

Alkaptonuria is a rare metabolic disease caused by deficiency of homogentisic acid oxidase and characterized by bluish-black discoloration of cartilages and skin (ochronosis). Defective production of this enzyme results in the accumulation of homogentisic acid (HGA), a tyrosine degradation product, in the bloodstream. Accumulation of HGA and its metabolites in tissues causes ochronosis. The word *ochronosis* refers to the dark bluish-black discoloration of connective tissues including the sclera, cornea, auricular cartilage, heart valves, articular cartilage, tendons, and ligaments. Neurogenic claudication resulting from focal hypertrophy of the ligamentum flavum in the lumbar spine due to ochronotic deposits has only been previously reported once in the literature. In this article, we present a 71-year-old male patient with alkaptonuria-associated degenerative L3–L4–L5 stenosis, diagnosed after lumbar decompressive laminectomy.

Keywords

- ▶ black colored
- ▶ ligamentum flavum
- ▶ alkaptonuria

Introduction

Ochronosis is a syndrome caused by the accumulation of homogentisic acid (HGA) in connective tissues. The phenomenon was first described by Rudolf Virchow in 1865. Defective production of homogentisate 1,2-dioxygenase results in the accumulation of HGA, a tyrosine degradation product, in the bloodstream. This enzyme deficiency causes homogentisate polymers to accumulate and results in urine darkening, brown black pigmentation of connective tissue, articular cartilage pathology, osteoporosis, and pathomorphological changes in internal organs. Spinal involvement in alkaptonuria is common, with the lumbar spine the most typical site in the form of early degenerative changes with disk space involvement.¹

Reddy et al first reported ligamentum flavum hypertrophy with an ochronotic deposit.² This report will be the second one on the subject. We present the clinical, radiologic, and histologic manifestations of an ochronosis case with a brief review of the literature.

Case Report

A 71-year-old male patient was admitted with a complaint of low back pain for 8 years with progressively worsening neurogenic claudication in the last 2 years. Neurologic exam-

ination revealed a positive straight leg raise test at 30 degrees. No past history of bowel and bladder disturbances or of surgery or trauma to the spine were reported. Routine laboratory examination of the patient was normal. He had no family history of metabolic abnormalities. Lumbar computed tomography showed calcifications of the lumbar vertebrae, especially L3–L4–L5 vertebra, with narrowed intervertebral disk spaces, intervertebral foramina, and vertebral canal (▶Fig. 1a, b). Magnetic resonance imaging showed lumbar L3–L4, L4–L5 lateral recess stenosis, foraminal stenosis, and narrowed intervertebral disk spaces (▶Fig. 2a, b).

The patient was operated on under general anesthesia. He underwent decompressive laminectomy for management of focal canal stenosis and foraminotomy at L3–L4 and L4–L5. The ligamentum flavum was degenerated and black in color (▶Fig. 3a, b). During the operation, in addition to the calcified and thickened ligamentum flavum, we also observed that the dura mater was degenerated and thinned. There was no complaint of pain or any neurologic deficits after the operation.

Histologic examination under light microscopy showed pigmentation and degeneration of the ligamentum flavum tissue (▶Fig. 3c–e). After the histologic diagnosis, the patient was reexamined, and black ochronotic pigmentation of the sclera, cornea, and skin was found (▶Fig. 4a, b). On examination of the urine, a high level of HGA was found, and the patient was

received
December 17, 2017
accepted after revision
May 14, 2018
published online
November 26, 2018

© 2019 Georg Thieme Verlag KG
Stuttgart · New York

DOI <https://doi.org/10.1055/s-0038-1675784>.
ISSN 2193-6315.

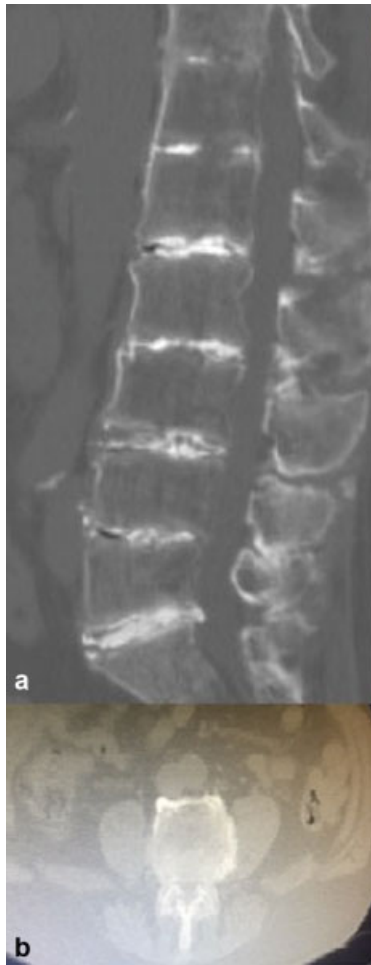


Fig. 1 (a, b) Lumbar computed tomography showing calcifications of the lumbar vertebrae, especially L3, L4, and L5, with narrowed intervertebral disk spaces, intervertebral foramina, and vertebral canal.

diagnosed with alkaptonuria. The patient was informed that data concerning his case would be submitted for publication.

Discussion

Alkaptonuria is the result of loss of function, missense mutations of the gene on chromosome 3q that codes for homogentisate 1, 2 dioxygenase (HGA). Scribonius first described the urinary manifestations of the disease in 1584, and Boedeker in 1858 recognized the presence in urine of a reducing substance (alkapton) with an affinity for oxygen in an alkaline medium.² Large quantities of HGA are excreted daily in the urine, where it oxidizes to benzoquinones, which in turn form the melanin-like polymers that cause the discoloration of urine. Accumulation of HGA and its metabolites in tissues causes ochronosis.^{1,2}

The embedded pigments also form cross-linkages with pigment deposition in adjacent fibers, stabilizing and reducing the elastic recoil of the fibers. This results in hardening of elastic structures, increasing their rigidity and brittleness. Once ruptured, the exposed pigments cause a foreign body reaction and inflammation. This pigment deposition also invokes deposition of hydroxyapatite, the mineral responsible for bone calcifica-

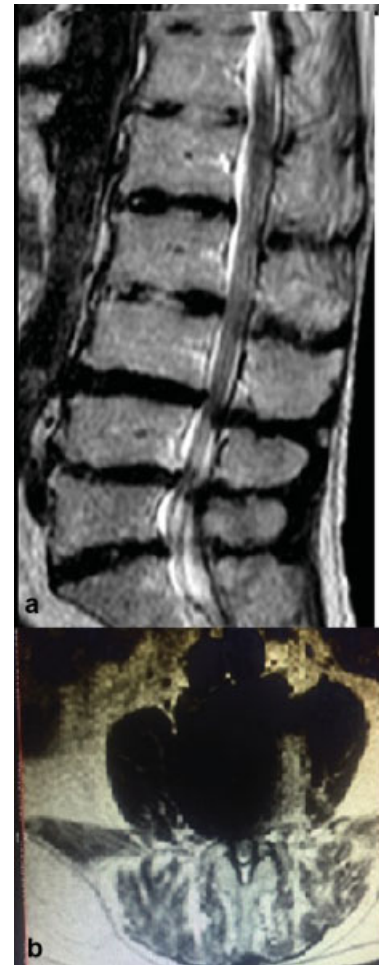


Fig. 2 (a, b) Magnetic resonance imaging showing lumbar L3-L4, L4-L5 lateral recess stenosis, foraminal stenosis, and narrowed intervertebral disk spaces.

tion, further hardening the connective tissue. The condition is most often associated with alkaptonuria but can occur from exogenous administration of phenol complexes like hydroquinone.^{3,4} The pathogenesis of alkaptonuria includes chronic inflammation, degeneration, and eventually osteoarthritis.

Characteristic radiographic findings of ochronotic arthropathy in the spine include vertebral osteopenia, loss of normal lumbar lordosis, widespread disk calcification, vacuum disk phenomenon, and progressive narrowing of intervertebral spaces. The thoracic and lumbar spinal segments are involved first; cervical spine involvement tends to occur later. Disk calcification occurs primarily in the annulus fibrosus and is thought to be due to dystrophic calcification of the abnormal connective tissue.⁵ The axial loading of body weight is maximal at the lower lumbar spine, which is why it undergoes early and accelerated age-related degenerative changes. This disrupts the integrity of the spinal stabilizing systems: passive (disk, ligament, bone, and passive muscle), active (tendons and active muscle), and neural (the nervous system and neural components within the passive and active structures), causing a transfer in unfavorable loads onto other spinal structures.⁶ The ochronotic deposits accelerate further calcium deposition in the ligaments and enhances their stiffness.²

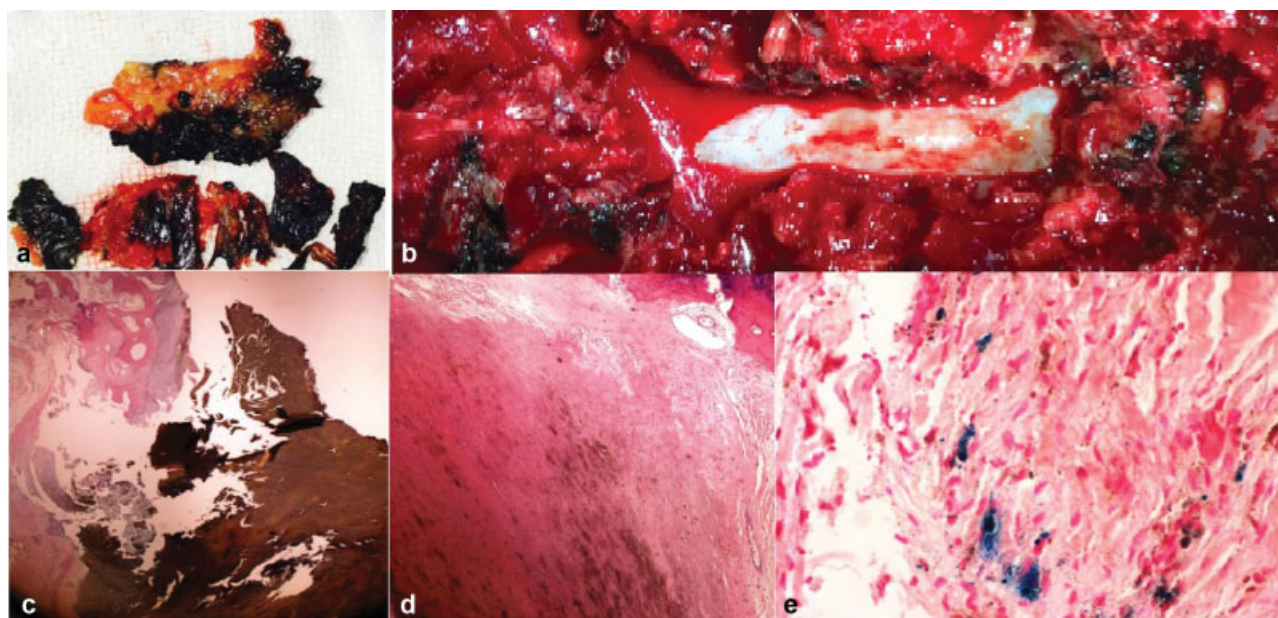


Fig. 3 (a, b) Intraoperative excised black-colored ligamentum pieces. (c–e) Histologic examination under light microscopy showing pigmentation and degeneration of the ligamentum flavum tissue.

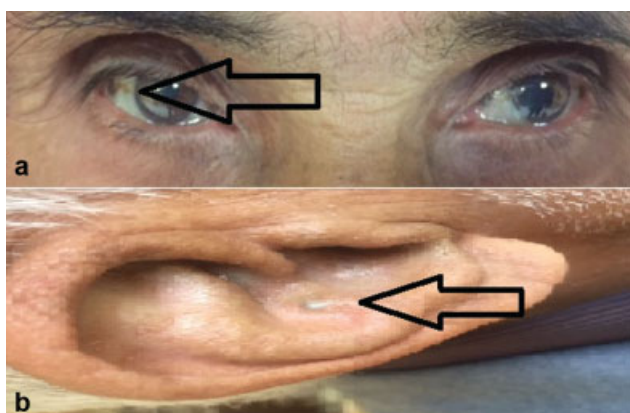


Fig. 4 (a, b) Patient's sclera and ear showing black ochronotic pigmentation.

Patients with mild alkaptonuria may remain asymptomatic and the condition unrecognized throughout life, like our patient. However, more commonly patients are recognized in the 4th or 5th decade.^{7,8} This case is also unusual because the patient's presentation was very mild. Patients usually begin complaining of progressive low back pain in their 30s, and many patients require joint replacement by 50 years of age. Our patient began to have back pain in his 60s.

The diagnosis of alkaptonuria is usually based on the detection of degenerative joint disease, ochronosis of the connective tissue, and darkening of urine after alkalization. Clinical findings include pigmentation of the ear cartilage and the sclera of the eyes that occurs after 30 years of age and vary in appearance. Almost all patients experience arthritis of the knee and hip, and occasionally the shoulder. Retrospective examination of our patient revealed only pigmentation of ear cartilage. Confirmatory tests for diagnosis are chromatographic, enzymatic, or spectrophotometric determinations of HGA.

Conclusion

In all the published case reports of lumbar and dorsal disk prolapse in ochronotic patients, ours was the second one after Reddy et al described the first case of ligamentum flavum hypertrophy with ochronosis.² Our patient with this metabolic disease had very thin dura mater, which might have been unique to our case. We suggest that ochronotic patients may have more spinal pathologies, and these patients and their complaints of pain should be considered more carefully with respect to their metabolic pathology.

References

- 1 Kalevski SK, Haritonov DG, Peev NA. Alcaptonuria with lumbar disc prolapse: case study and review of the literature. *Spine J* 2007;7(04):495–498
- 2 Reddy R, Vijayaradhi M, Biswal D. Focal ligamentum flavum hypertrophy with ochronotic deposits: an unusual cause for neurogenic claudication in alkaptonuria. *Asian Spine J* 2012;6(02):148–151
- 3 Osun A, Korkmaz M, Temiz P, Samancioglu A, Atay B. Black colored intervertebral disc; ochronosis: a case report. *Turk J Phys Med Rehab* 2017;63(01):78–81
- 4 Aydeniz A, Karşilgil T, Gursoy S. Associations between low back pain, disability, functional status, and serum interleukin-1 β level. *Turk J Med Sci* 2009;39(04):613–617
- 5 Robbani I, Kak S, Mohan V, Sharma R. Ochronosis or alkaptonuric arthropathy. *JK Science* 2000;2:102–104
- 6 Panjabi MM. The stabilizing system of the spine. Part I. Function, dysfunction, adaptation, and enhancement. *J Spinal Disord* 1992; 5(04):383–389; discussion 397
- 7 Pratibha K, Seenappa T, Ranganath K. Alkaptonuric ochronosis: report of a case and brief review. *Indian J Clin Biochem* 2007;22(02):158–161
- 8 Collins E, Hand R. Alkaptonuric ochronosis: a case report. *AANA J* 2005;73(01):41–46