

A Case of Inferior Vena Cava Thrombosis Induced by Left Iliac Vein Stents

Wei Wei^{1,*} Xuemei Jiang^{2,*} Bo Xu³ Yikuan Chen¹

¹Department of Vascular Surgery, Second Affiliated Hospital, Chongqing Medical University, Chongqing, China

²Department of Hematology, Second Affiliated Hospital, Chongqing Medical University, Chongqing, China

³Department of Cardiothoracic Surgery, Second Affiliated Hospital, Army Medical University, Chongqing, China

Address for correspondence Yikuan Chen, MD, Department of Vascular Surgery, Second Affiliated Hospital, Chongqing Medical University, Lingjiang Road 76, Yuzhong District, Chongqing 400010, China (e-mail: 1737962164@qq.com).

Thorac Cardiovasc Surg Rep 2018;7:e39–e42.

Abstract

Keywords

- ▶ deep vein thrombosis
- ▶ post-thrombotic syndrome
- ▶ iliac vein stent
- ▶ inferior vena cava thrombosis

Stents have been widely used to restore the patency of the iliac vein in the treatment of its obstruction. However, various complications related to those stents have been reported. This case report covers a 67-year-old male who was diagnosed with left iliofemoral venous post-thrombotic syndrome with recurrent acute deep venous thrombosis. Thrombosis of the inferior vena cava was induced by pronounced extension of left iliac vein stents. Extending stents in this way covers the outlet of the contralateral common iliac vein and may induce thrombosis in the inferior vena cava.

Introduction

Clinicians have increasingly come to favor stents to restore and maintain venous patency in patients with iliac vein obstruction.¹ However, stent-related complications, including thrombosis within the stent, contralateral iliac vein and veins of the lower extremities, and stent migration into the right ventricle,² have been reported. They have several causes. Extending of iliac vein stents far into the inferior vena cava could induce contralateral deep venous thrombosis of the lower extremities.³ This case is the first report to describe inferior vena cava thrombosis induced by this degree of extension of a left iliac vein stent.

Case Report

A 67-year-old male was admitted to our hospital with a 1-year history of left lower extremity pain and swelling and a 1-week history of worsened symptoms. Anticoagulation treatment with subcutaneous low molecular weight heparin was initiated when the patient was admitted. A venogram with loperamide showed that the common femoral, external iliac,

and common iliac veins were occluded. New thrombi were founded in the common femoral and external iliac veins (▶ Fig. 1A). A 4F Uni*Fuse infusion catheter (Angiodynamics, Queensbury, New York, United States) with multiple sideholes covering the thrombi was introduced with 0.035-inch hydrophilic guide wire (Boston Scientific, Natick, MA, United States) under fluoroscopic guidance. After thrombolysis with urokinase (Tianjin Biochemical Pharmaceutical, China) at a rate of 200,000 IU/8 h for 36 hours, the new thrombi were resolved, and large lateral branches joining the contralateral common iliac vein were observed, while the external iliac and common iliac veins were still occluded (▶ Fig. 1B). The level of protein C, protein S, and antithrombin III were normal, and no other coagulation disorder were detected. The patient was diagnosed with left iliofemoral venous post-thrombotic syndrome (PTS) with recurrent acute deep venous thrombosis.

A self-expanding 14 × 120 mm Luminexx stent (Bard Inc., United States) was implanted in the left external iliac and common iliac veins. The patient accepted warfarin therapy after discharge, with the international normalized ratio adjusted to maintain at 2 to 3. Swelling in the left lower extremity reoccurred 50 days later, and venography showed full thrombosis in stent and common femoral vein (▶ Fig. 1C). Thrombolysis with urokinase at a rate of 200,000 IU/8 h for

* Both authors contributed equally to the article.

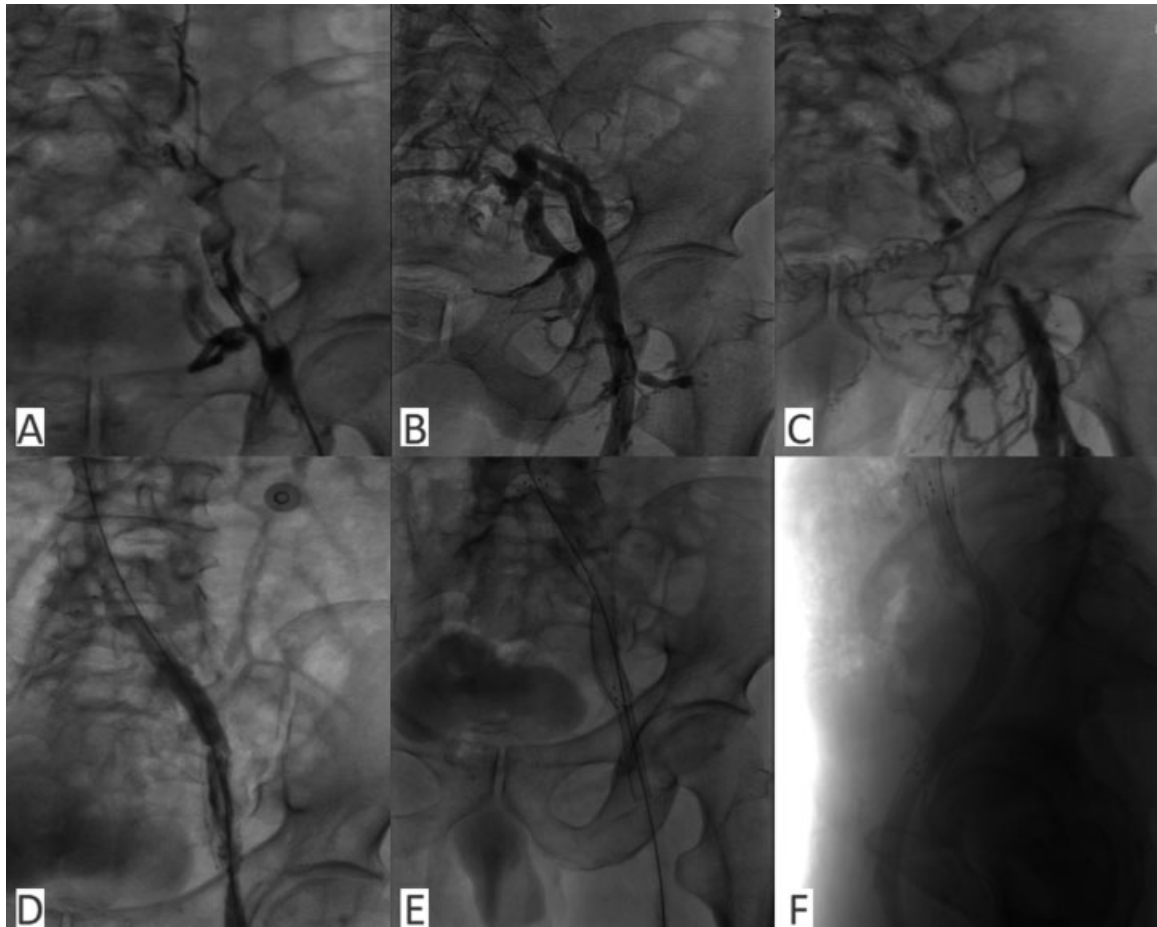


Fig. 1 Venogram before and after stent placement. (A) New thrombi in the common femoral and external iliac veins. (B) Thrombolysis resolved new thrombi, while external iliac and common iliac veins were still occluded. (C) A 14 × 120 mm Luminexx stent was implanted, but thrombosis occurred in this stent 50 days later. (D) Thrombolysis partially resolved the thrombi. (E) A second 14 × 120 mm Luminexx stent was implanted to restore the patent of the first stent and a 12 × 90 mm WALLSTENT to restore the patency of the common femoral vein. (F) Left lateral venogram showing the long-curve stents.

42 hours, the thrombi in stent were partially resolved, and the stent partially recanalized (►Fig. 1D). A self-expanding 14 × 120 mm Luminexx stent was implanted again to restore the patent of stent, and a self-expanding 12 × 90 mm Wallstent (Boston Scientific, United States) was used to restore the patent of common femoral vein (►Fig. 1E). Left lateral venogram showed that the implanted long stents in left iliofemoral vein were S-shaped curve (►Fig. 1F).

Despite continual anticoagulation with warfarin, swelling in the left lower extremity reoccurred 60 days later, and full thrombosis occurred in the distal inferior vena cava and stents (►Fig. 2A). The proximal end of the stent was extended far into the inferior vena cava and covered the outlet of the right common iliac vein (►Fig. 2B and C). Thrombolysis with urokinase resolved the thrombi in stents for 3 days (►Fig. 2D) and in inferior vena cava for 5 days (►Fig. 2E). The follow-up had been performed for 1-year anticoagulation with warfarin, and the patient remained free of recurrence.

Discussion

Post-thrombotic syndrome is a chronic condition with a set of clinical symptoms and signs that occur in a limb months to

years after an acute deep venous thrombosis. These include daily limb pain or aching, fatigue, heaviness, swelling, or some combination of these, which worsen when the patient assumes an upright position or engages in more than moderate activity.⁴ The treatment of iliofemoral venous PTS with balloon angioplasty and stenting is a minimally invasive, highly effective, and safe approach.⁵ The guidelines of both the Society for Interventional Radiology and the Society of Vascular Surgery recommend iliac vein stenting in the context of PTS.⁶ However, no common view has emerged regarding the choice of stent type, stent size, or position of the implant. Complications, such as stent thrombosis and iliac stent-induced contralateral deep venous thrombosis of the lower extremities, have been reported. Murphy et al found that contralateral deep venous thrombosis incidence was significantly higher in Wallstent with 3- to 5-cm extension into the inferior vena cava than in Gianturco Z-stent with extension ~2 cm into the inferior vena cava. Furthermore, all three contralateral deep venous thromboses in Gianturco Z-stent have high placement of stent across the ilio caval confluence.³ This report is the first to describe thrombosis of the inferior vena cava induced by pronounced extension of left iliac vein stents. Because the stents covered

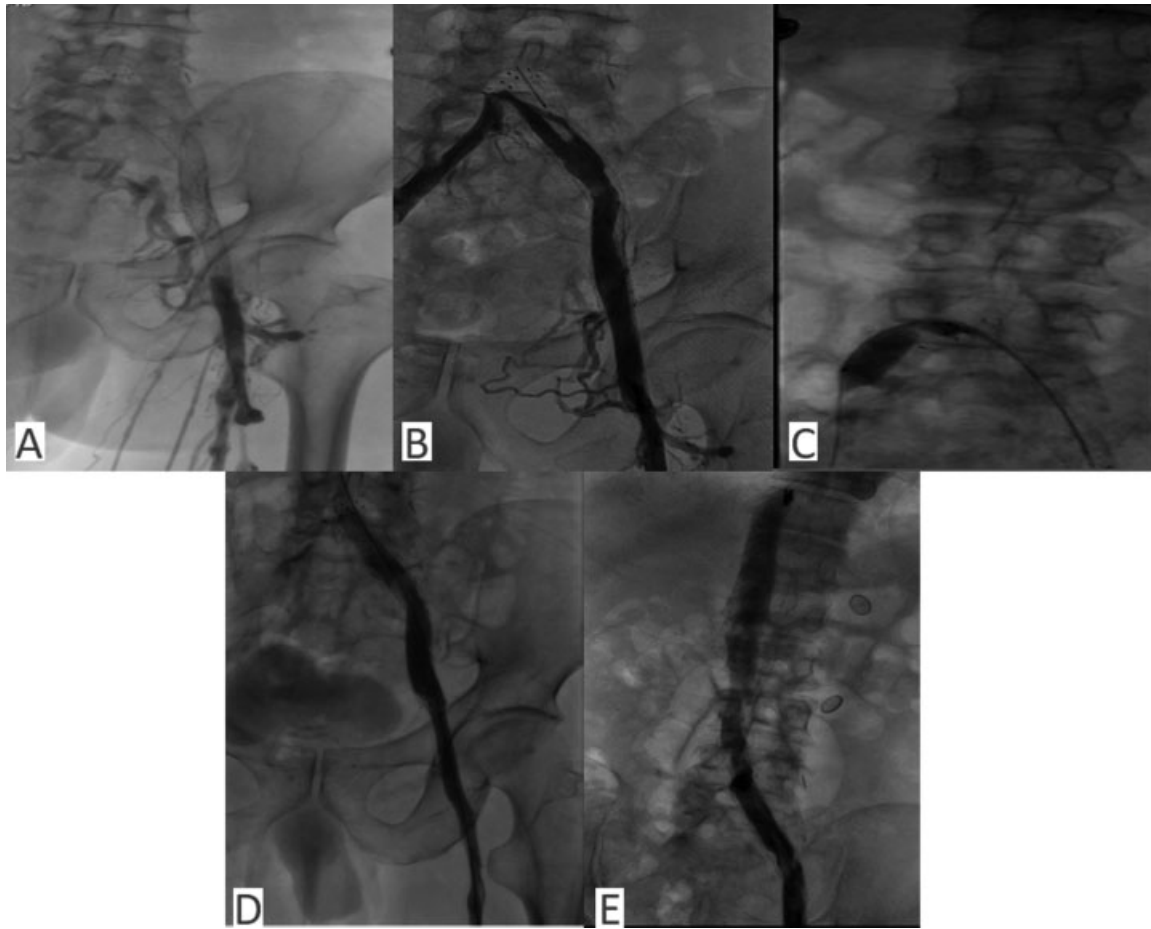


Fig. 2 The left iliac vein stent induced inferior vena cava thrombosis. (A) The third stent implantation 60 days later, thrombosis occurred in the inferior vena cava, and the left iliac vein stents. (B) The proximal end of the stents extended far into the inferior vena cava and covered the outlet of the right common iliac vein. (C) The proximal end of the stent depressed the balloon at the outlet of the right common iliac vein. (D) Thrombolysis resolved the thrombi in the stents. (E) Thrombolysis resolved the thrombi in the inferior vena cava.

the outlet of the right common iliac vein, the thrombosis within stents in the left iliac vein not only occluded the blood flow of the left common iliac vein, but also the blood flow of the right common iliac vein. Then the blood flow of the distal inferior vena cava stopped, and thrombosis in the distal inferior vena cava occurred. If the stents did not extend far into the inferior vena cava and fully cover the outlet of the right common iliac vein, no thrombosis developed in the inferior vena cava. Even if it did develop in the left iliac vein stents, specially designed dedicated venous stents that are oblique at the caval end might prevent such problems. Herein we contradict the idea that iliac vein stents should extend far into the inferior vena cava. Because thrombosis can form in stents, we consider that 12-cm long laser-carved Luminexx stents, which are not very flexible and have large side holes, might not be appropriate for the treatment of PTS with long occluded left common iliac and external iliac veins. No endothelial cell overlaid sub-intima tissue of the left iliac vein, which was exposed to the inner surface of the stent due to the large side holes in the Luminexx stents, was prone to inducing thrombosis. The venogram showed that the inner surface of the flexible woven stent was smoother than that of the laser-carved stent. Raju and colleagues used

multiple flexible, self-expanding stents to recanalize the long occluded iliofemoral veins in most patients.⁷ For the long occluded iliac vein, it might be reasonable to implant a short laser-carved stent in the common iliac vein and be followed by a woven flexible stent in the external vein. Inappropriate stents might increase the potential risk of thrombogenesis in iliac vein stents and further induce inferior vena cava thrombosis.

Conclusions

This case highlights potential consequences of extending stents far into the inferior vena cava in patients with iliac vein long obstruction. It is reasonable to accurately position a laser-carved stent to restore the patency of occluded common iliac vein.

Conflict of Interest Statement

None declared.

Ethical Approval Statement

This study was in accordance with the ethical standards of the institutional review board of the Medical University

and with the 1964 Helsinki Declaration and its later amendments or comparable ethical standards.

Note

Informed consent was obtained from the patient.

Acknowledgement

Wei Wei and Xuemei Jiang are 2 equally contributing authors. The explanation is as follows:

Wei Wei was responsible for writing the article.

Xuemei Jiang was responsible for conception and data collection.

References

- 1 Schleimer K, Barbati ME, Gombert A, Wienert V, Grommes J, Jalaie H. The treatment of post-thrombotic syndrome. *Dtsch Arztebl Int* 2016;113(50):863–870
- 2 Holst T, Großwendt T, Laham MM, Roosta-Azad M, Zandi A, Kamler M. Acute stent migration into the right ventricle in a patient with iliac vein stenting. *Thorac Cardiovasc Surg Rep* 2018; 7(01):e7–e8
- 3 Murphy EH, Johns B, Varney E, Buck W, Jayaraj A, Raju S. Deep venous thrombosis associated with caval extension of iliac stents. *J Vasc Surg Venous Lymphat Disord* 2017;5(01):8–17
- 4 Jain A, Cifu AS. Prevention, diagnosis, and treatment of post-thrombotic syndrome. *JAMA* 2016;315(10):1048–1049
- 5 Vedantham S. Venous clot lysis and stenting. *Hematology (Am Soc Hematol Educ Program)* 2015;2015:210–214
- 6 Meissner MH, Gloviczki P, Comerota AJ, et al; Society for Vascular Surgery; American Venous Forum. Early thrombus removal strategies for acute deep venous thrombosis: clinical practice guidelines of the Society for Vascular Surgery and the American Venous Forum. *J Vasc Surg* 2012;55(05):1449–1462
- 7 Raju S, McAllister S, Neglen P. Recanalization of totally occluded iliac and adjacent venous segments. *J Vasc Surg* 2002;36(05): 903–911