

# Suboccipital Lateral Approach for Resection of Cerebellopontine Angle Meningioma: Operative Video and Technical Nuances

Mateus Reghin Neto<sup>1</sup> Heros Henrique Melo Almeida<sup>1</sup> João Paulo Almeida<sup>2</sup> Ygor Peçanha Alexim<sup>1</sup>  
Matheus Merula de Almeida<sup>1</sup> Rodrigo Lima Tavares<sup>1</sup> Antonio Carlos Corrêa<sup>1</sup> Evandro de Oliveira<sup>1</sup>

<sup>1</sup>Department of Neurosurgery, Hospital Beneficência Portuguesa de São Paulo, Institute of Neurological Science of São Paulo, Bela Vista, São Paulo, Brasil

<sup>2</sup>Division of Neurosurgery, Toronto Western Hospital, University of Toronto, Toronto, ON, Canada

**Address for correspondence** Heros Henrique Melo Almeida, MD, Department of Neurosurgery, Hospital Beneficência Portuguesa de São Paulo, Institute of Neurological Science of São Paulo, Praça Amadeu Amaral, 27, 5 andar, Bela Vista, São Paulo, 01327-010, Brasil (e-mail: heroshm@gmail.com).

J Neurol Surg B 2018;79(suppl S5):S397–S398.

## Abstract

We present the case of a 34-year-old woman, who presented to our department with a 4 months history of dizziness, hearing loss, and tinnitus on the right side. MRI (magnetic resonance imaging) scan demonstrated a large extra-axial lesion, suggestive of a meningioma, with dural attachments to the petrosal bone surface and tentorium, closely related with the trigeminal, abducens, facial, vestibulocochlear, and lower cranial nerves in the right side. Treatment options were discussed with the patient, and surgical resection was selected to remove the lesion, and decompress the cranial nerves and brainstem. The surgery was performed with a patient in a semi-seated position with head placed in a flexed, nonrotated position. A right lateral suboccipital approach was performed, exposing the right transverse and sigmoid sinuses. After dura opening, microsurgical dissection was used to open the cisterna magna, and obtain cerebellum relaxation. That was followed by identification of cranial nerves VII–XII and then identification of the tumor itself. Tumor debulking was then performed with use of suction and ultrasonic aspirator. After extensive resection, the tumor margins were dissected away from brainstem, cerebellum, and cranial nerves. Finally, the tumor attachment to the tentorium was coagulated and cut and the tumor was completely removed. Postoperative MRI confirmed complete resection of the tumor. The patient was discharged on the 1st week after surgery, with no additional postoperative deficits or complications.

The link to the video can be found at: <https://youtu.be/aZ3jhZTAA>.

## Keywords

- ▶ skull base
- ▶ meningioma
- ▶ cerebellopontine angle
- ▶ suboccipital lateral approach
- ▶ operative video

## Conflict of Interest

None.



[www.thieme.com/skullbasevideos](http://www.thieme.com/skullbasevideos)

[www.thieme.com/jnlsvideos](http://www.thieme.com/jnlsvideos)

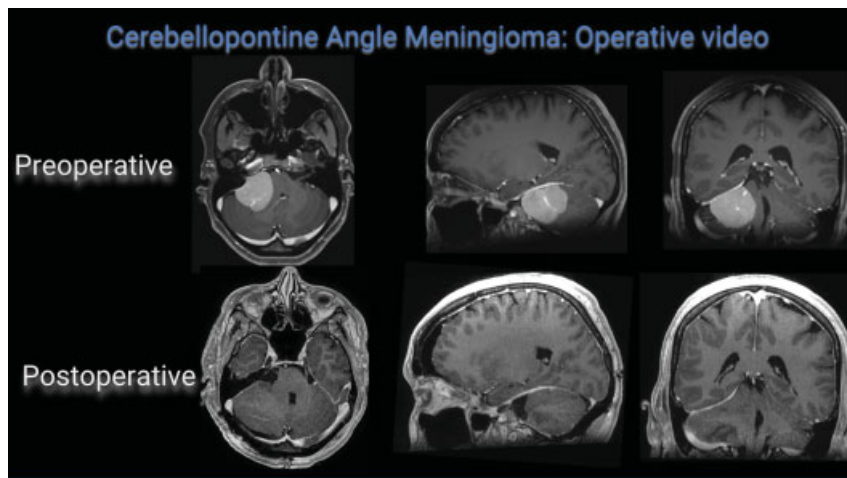
received  
June 1, 2018  
accepted  
August 11, 2018  
published online  
October 9, 2018

DOI <https://doi.org/10.1055/s-0038-1669982>.  
ISSN 2193-6331.

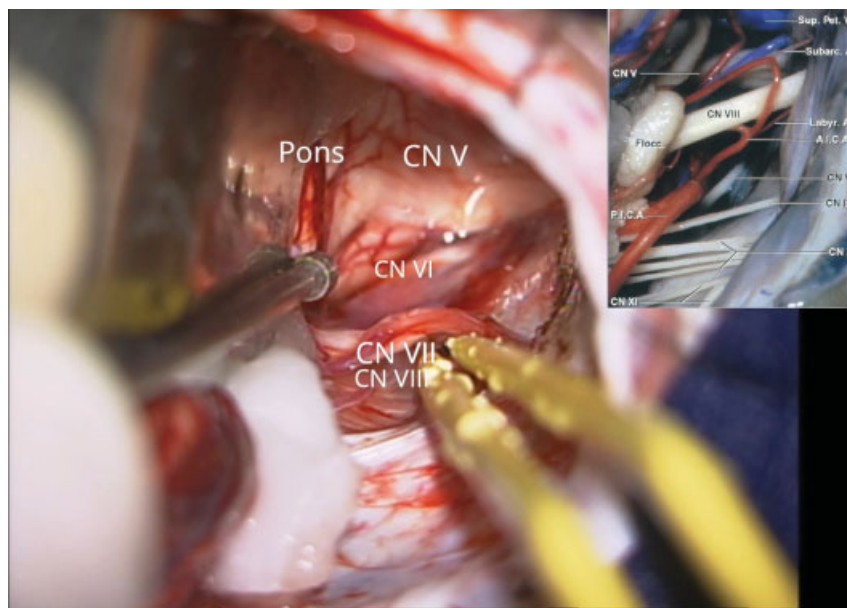
© 2018 Georg Thieme Verlag KG  
Stuttgart · New York

License terms





**Fig. 1** MRI (magnetic resonance imaging) images—Preoperative and Postoperative.



**Fig. 2** Intraoperative image.