

# Trochlear Nerve Repair during Retrosigmoid Suprameatal Approach for Petrotentorial Meningioma: Operative Video

Ken Matsushima<sup>1</sup> Michihiro Kohno<sup>1</sup> Nobuyuki Nakajima<sup>1</sup> Norio Ichimasu<sup>1</sup>

<sup>1</sup>Department of Neurosurgery, Tokyo Medical University, Tokyo, Japan

J Neurol Surg B 2018;79(suppl S5):S404–S406.

Address for correspondence Michihiro Kohno, MD, PhD, Department of Neurosurgery, Tokyo Medical University, 6-7-1 Nishi-Shinjuku, Shinjuku-ku, Tokyo 160-0023, Japan (e-mail: mkouno-nsu@umin.ac.jp).

## Abstract

When operating on difficult skull base lesions, it is essential to be able to handle unexpected intraoperative findings or troubles, while achieving maximal lesion removal and minimal functional deficit. This video demonstrates a case of trochlear nerve repair that was performed during the retrosigmoid suprameatal approach for treatment of a petrotentorial meningioma, extending into the Meckel's cave. The patient is a 47-year-old woman with a right petrotentorial meningioma, extending into the Meckel's cave. The retrosigmoid suprameatal approach was performed with preservation of the superior petrosal vein. However, a divided trochlear nerve was incidentally found during tumor resection. We hence carefully dissected both nerve ends from the tumor without shortening their lengths, and repaired them by end-to-end anastomosis, using fibrin glue without any graft materials. The tumor was removed completely and the patient's preoperative facial sensory impairment disappeared after the surgery. The patient's facial sensory impairment disappeared completely, but she had transient diplopia after the surgery. However, the newly developed diplopia resolved completely, and she had no neurological deficits or tumor recurrence during the follow-up period of 1-year.

The link to the video can be found at: [https://youtu.be/g-B-w\\_zDudg](https://youtu.be/g-B-w_zDudg).

## Keywords

- ▶ cerebellopontine angle
- ▶ cranial nerve anastomosis
- ▶ nerve reconstruction
- ▶ nerve regeneration
- ▶ skull base surgery



[www.thieme.com/skullbasevideos](http://www.thieme.com/skullbasevideos)

[www.thieme.com/jnlsbvideos](http://www.thieme.com/jnlsbvideos)

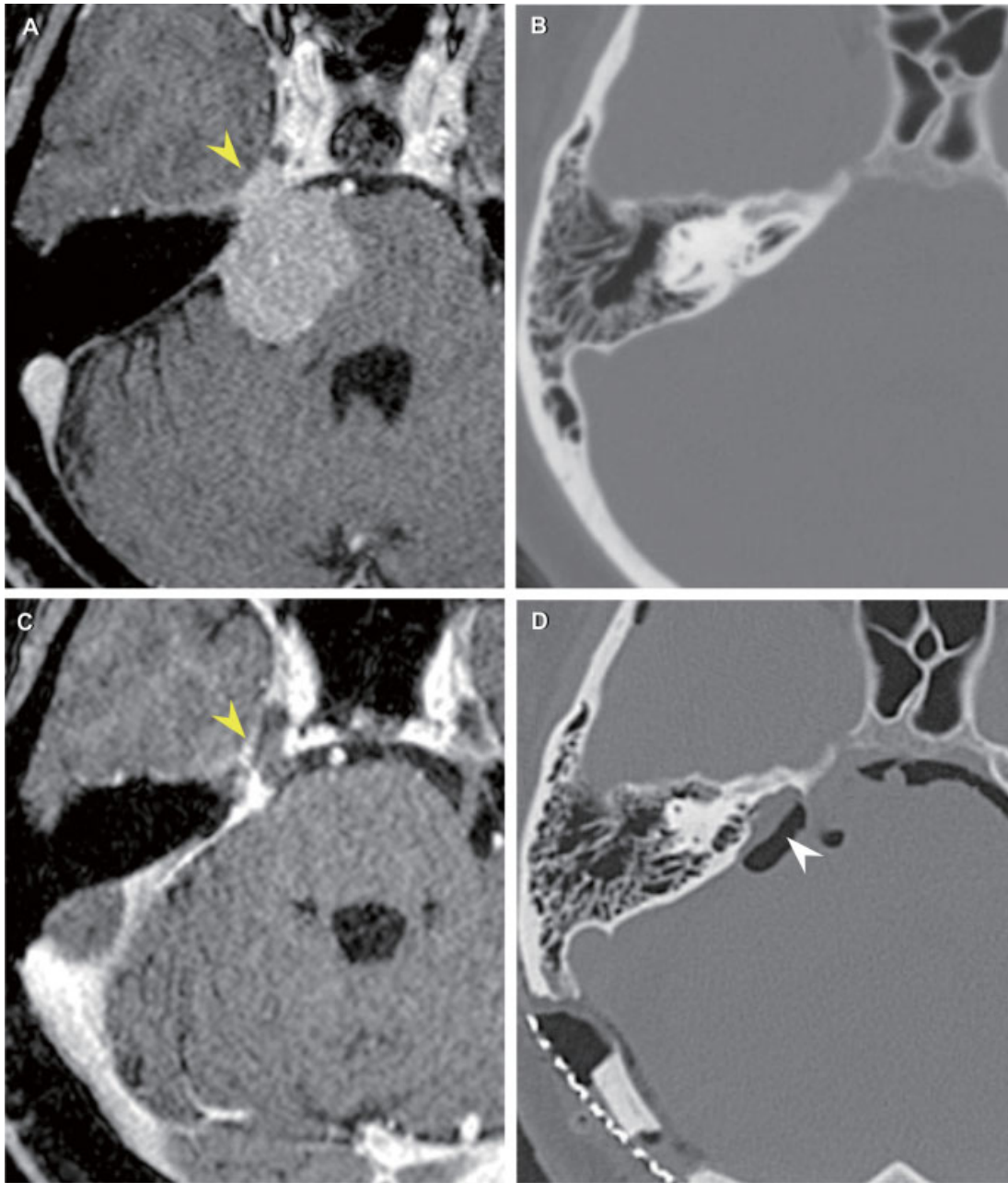
received  
May 23, 2018  
accepted  
August 12, 2018  
published online  
October 1, 2018

DOI <https://doi.org/10.1055/s-0038-1669967>.  
ISSN 2193-6331.

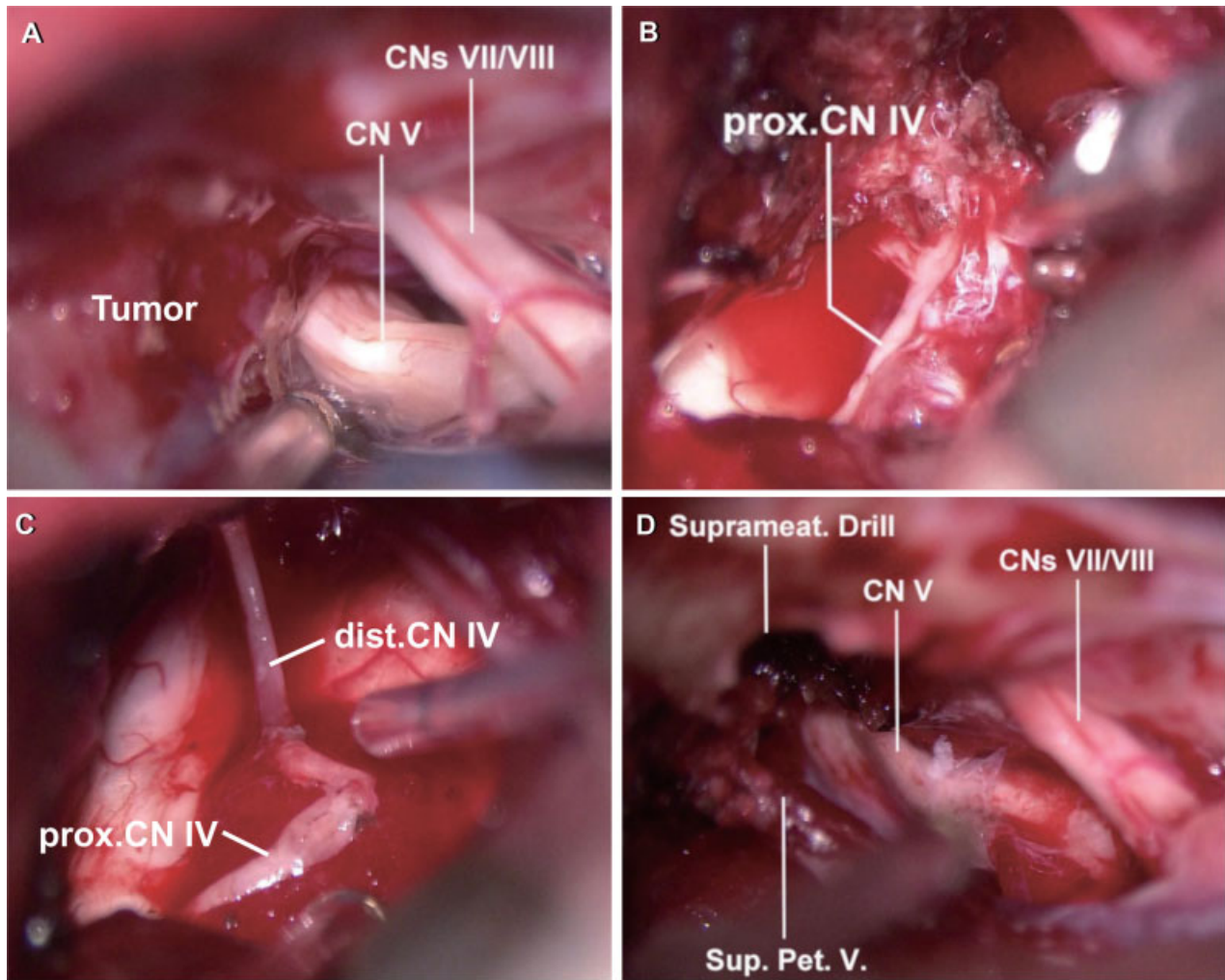
© 2018 Georg Thieme Verlag KG  
Stuttgart · New York

License terms





**Fig. 1** (A and B) Preoperative and (C and D) postoperative; (A and C) postgadolinium T1-weighted magnetic resonance imaging and (B and D) computed tomography scans of a right petrotentorial meningioma extending into the Meckel's cave (yellow arrowhead in A), which was removed through the retrosigmoid suprameatal approach.



**Fig. 2** (A) A right petrotentorial meningioma displaced the facial/vestibulocochlear nerve complex and trigeminal nerve caudally. (B) A divided trochlear nerve was incidentally found during tumor resection. (C) The trochlear nerve was end-to-end reconstructed using fibrin glue without any graft materials. (D) After drilling the suprameatal area that was limited by the superior petrosal vein, the tumor inside the Meckel's cave was completely removed. CN, cranial nerve; dist., distal; Pet., petrosal; prox., proximal; Sup., superior; Suprameat., suprameatal; V., vein.

**Conflict of Interest**

None.

**Acknowledgments**

We thank Ms. Asa Otonari and Ms. Kaori Noda for their assistance in preparing this video.

**References**

- 1 Grimson BS, Ross MJ, Tyson G. Return of function after intracranial suture of the trochlear nerve. Case report. *J Neurosurg* 1984;61(01): 191-192
- 2 Menovsky T, van Overbeeke JJ. Intracranial nerve repair: a review of experimental and clinical studies. *Neurosurg Focus* 1996;1(02):e2