Osteophytic Iliac Venous Compression: Technical Considerations for a Bony May-Thurner Syndrome Variant

David S. Shin[1] Mahati Mokkarala[1] Stephen Allison[1,2] Eric J. Monroe[1,3]

[1]Section of Interventional Radiology, Department of Radiology, University of Washington, Seattle, Washington, United States
[2]Department Imaging Service, Veterans Affairs Puget Sound Health Care System, Seattle, Washington, United States
[3]Department of Radiology, Section of Interventional Radiology, Seattle Children's Hospital, Seattle, Washington, United States

Address for correspondence Eric J. Monroe, MD, Department of Radiology, Seattle Children's Hospital, 4800 Sand Point Way NE, M/S R-5417, Seattle, WA 98105, United States (e-mail: eric.monroe@seattlechildrens.org).

J Clin Interv Radiol ISVIR 2018;2:95–100

Abstract

May-Thurner syndrome (MTS) results in compression of the left common iliac vein between the spine and right common iliac artery leading to symptomatic venous outflow obstruction. The authors depict a classic case of MTS followed by four variant cases in which the primary culprit lesions causing compression were degenerative vertebral osteophytes. The osteophytic variant of MTS poses distinct diagnostic and therapeutic challenges.

Keywords
- May-Thurner syndrome
- venous compression
- osteophyte
- thrombolysis
- stent

Introduction

May-Thurner syndrome (MTS) classically refers to symptomatic venous outflow obstruction of the left lower extremity, with or without venous thrombosis, due to external compression of the left common iliac vein (LCIV) by the right common iliac artery (RCIA).[1,2] Chronic compression and pulsatile biomechanics lead to venous intimal injury, which in turn causes obstruction and stenosis and can precipitate deep vein thrombosis (DVT).[1,2] This article presents an MTS variant in which prominent vertebral osteophytes compress the involved iliac veins with or without contribution from the RCIA and LCIA. We highlight the importance of considering different clinical and technical aspects when diagnosing and treating this distinct MTS variant.

Classic Presentation and Treatment

Patients with MTS are typically teenagers or young adults and more commonly female. They may present acutely with left lower extremity pain and swelling or with signs of chronic venous insufficiency. When suspected, the presence and extent of DVT are often initially assessed with Duplex ultrasound (US). Additional imaging can be considered to confirm any underlying anatomic compression, including computed tomographic venography (CTV), magnetic resonance venography (MRV), and/or catheter venography.[3] Pulmonary arterial phase computed tomographic arteriography (CTA) or magnetic resonance arteriography (MRA) may be added if pulmonary embolism is suspected. Management of patients with MTS with DVT includes anticoagulation, catheter-directed thrombolysis, and/or angioplasty and stent placement at the obstructed site[4] (►**Fig. 1**). Axial intravascular ultrasound (IVUS) is a useful adjuvant to plan stent placement and subsequently evaluate treatment.

Clinical Consideration: Variant Demographics

Multiple studies have shown that classic MTS occurs more often in women of reproductive age.[5,6] Although the relative frequency of osteophytic MTS variant across different demographic groups is unknown, its incidence is expected to be higher in older patients, who are more likely to experience degenerative spondylosis. When an older adult presents with the first episode of unprovoked unilateral lower extremity

received
April 12, 2018
accepted after revision
June 11, 2018
published online
July 31, 2018

DOI https://doi.org/10.1055/s-0038-1667208.
ISSN 2457-0214.

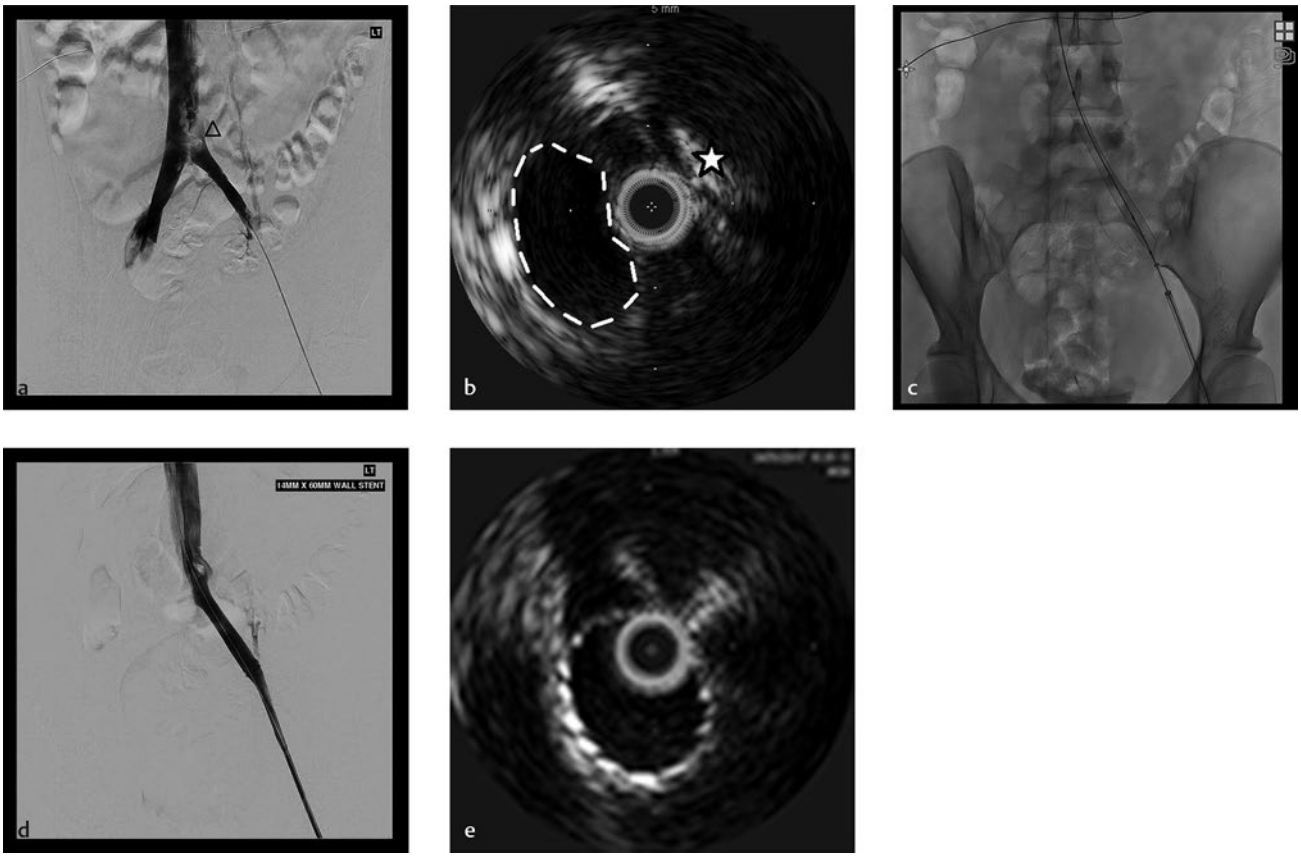

Fig. 1 A 16-year-old girl presented with acute left iliofemoral deep vein thrombosis. Iliac digital subtraction venography (DSV) following thrombolysis demonstrated **(A)** extrinsic compression of the central aspects of the left common iliac vein (LCIV) (arrowhead). Intravascular ultrasound (IVUS) (Volcano Corporation) confirmed **(B)** compression between the right common iliac artery (RCIA) (dashed outline) and lumbar vertebral body (open star). Following angioplasty and placement of a 14 × 60-mm self-expanding bare metal stent (Wallstent, Boston Scientific) **(C)**, DSV demonstrated **(D)** reestablished in-line outflow. Completion intravascular ultrasound confirmed **(E)** venous expansion between the RCIA and lumbar vertebral body.

DVT, particularly if iliofemoral in distribution, an osteophytic MTS variant should be considered (►**Fig. 2**).

Clinical Consideration: Variant Laterality

Outside of *situs inversus* anatomy, classic MTS occurs on the left side due to the midline crossing of the RCIA and LCIV. Because of variable patterns of degenerative spondylosis, right-sided presentation of iliofemoral venous occlusion does not exclude a variant of MTS. The clinical features may be otherwise indistinguishable from classic MTS (►**Fig. 3**).

Technical Consideration: "Pseudothrombus"

Bulky osteophytes may cause marginal extrinsic compression, mimicking mural thrombus on digital subtraction venography (►**Fig. 2**). Alternatively, a central impression on the vein may mimic the appearance of nearly occlusive thrombus (►**Fig. 4**). Failure to recognize the nature of this problem may result in delayed IVC filter removal or prolonged anticoagulation therapy. When suspected, comparison to unsubtracted images and/or repeat imaging in various obliquities may be clarifying. If those tactics are insufficient, intravascular ultrasound or cone-beam CTV are useful problem-solving tools.

Technical Consideration: Stent Construct Reinforcement

Stent placement across the area of occlusion is widely considered a standard therapy for MTS. The bony projections associated with the osteophytic MTS variant create a smaller surface area of compression and fulcrum effect. As a result, the compressive lesion may not respond as well to the same endovascular techniques. Despite initial apparent technical success, excessive extrinsic compression may promote early stent failure (►**Fig. 5**). A stent or stent construct with higher radial force may be required to achieve durable patency. Alternatively, analogous to stent failures seen in venous thoracic outlet syndrome, the underlying musculoskeletal compressive etiology may need to be addressed surgically.[3,7]

Conclusion

We present a classic case of MTS as well as four examples of osteophytic variants with various clinical manifestations. In all cases, catheter venography confirmed hemodynamically significant iliac venous stenosis or occlusion with visualization of prominent collateral channels. Correlation with

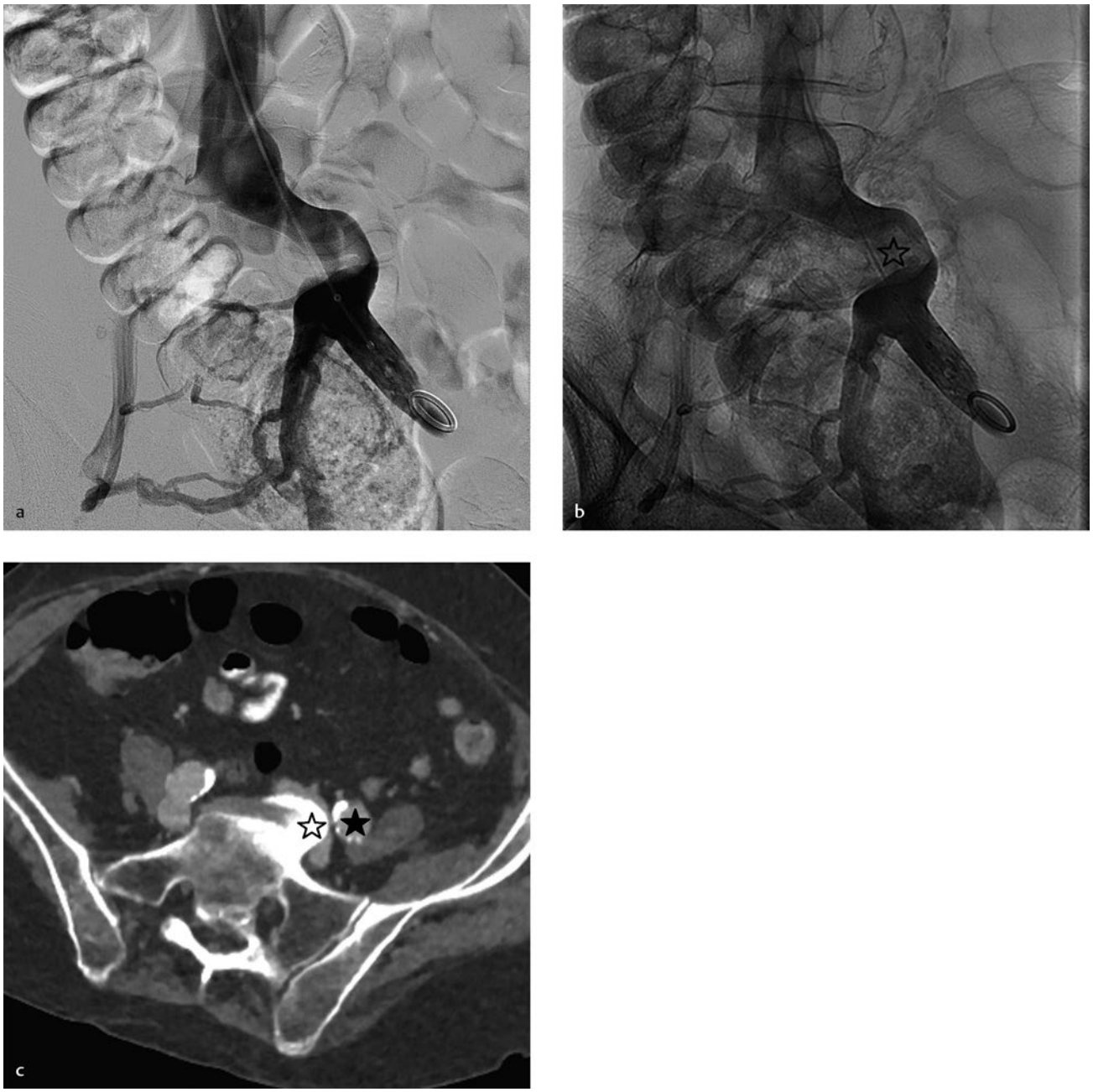

Fig. 2 A 68-year-old man with a history of left lower extremity deep vein thrombosis presented for inferior vena cava (IVC) filter placement given the need to withhold anticoagulation prior to his spine surgery for thoracic compression fractures. During initial venography, an obvious displacement and compression of the left common iliac vein (LCIV) by a bulky lumbosacral osteophyte (open star) was noted along with transpelvic collaterals **(A, B)**. Retrospective review of a prior CT confirmed **(C)** compression of the LCIV between the osteophyte (open star) and the left common iliac artery (LCIA) (black star).

cross-sectional imaging demonstrated degenerative vertebral osteophytes disc herniation as the culprit compressive lesions.

Various causes of iliac vein compression leading to MTS have been reported, including gravid uterus,[5] ectopic kidney,[8] right iliac artery stent,[9] and orthopaedic hardware.[10] To the best of our knowledge, this variant of MTS in which bony structures are primarily responsible for the iliac vein compression is underreported. This underrecognized entity presents distinct diagnostic and therapeutic challenges compared with classic MTS.

Main Points

- MTS classically refers to symptomatic venous outflow obstruction of the left lower extremity, with or without venous thrombosis, due to external compression of the LCIV by the RCIA.
- Typical treatment of MTS involves thrombolysis (when applicable) and placement of a self-expanding bare metal stent across the compressive lesion.
- An osteophytic variant of MTS may affect common iliac veins on either side, result in venographic pseudolesions,

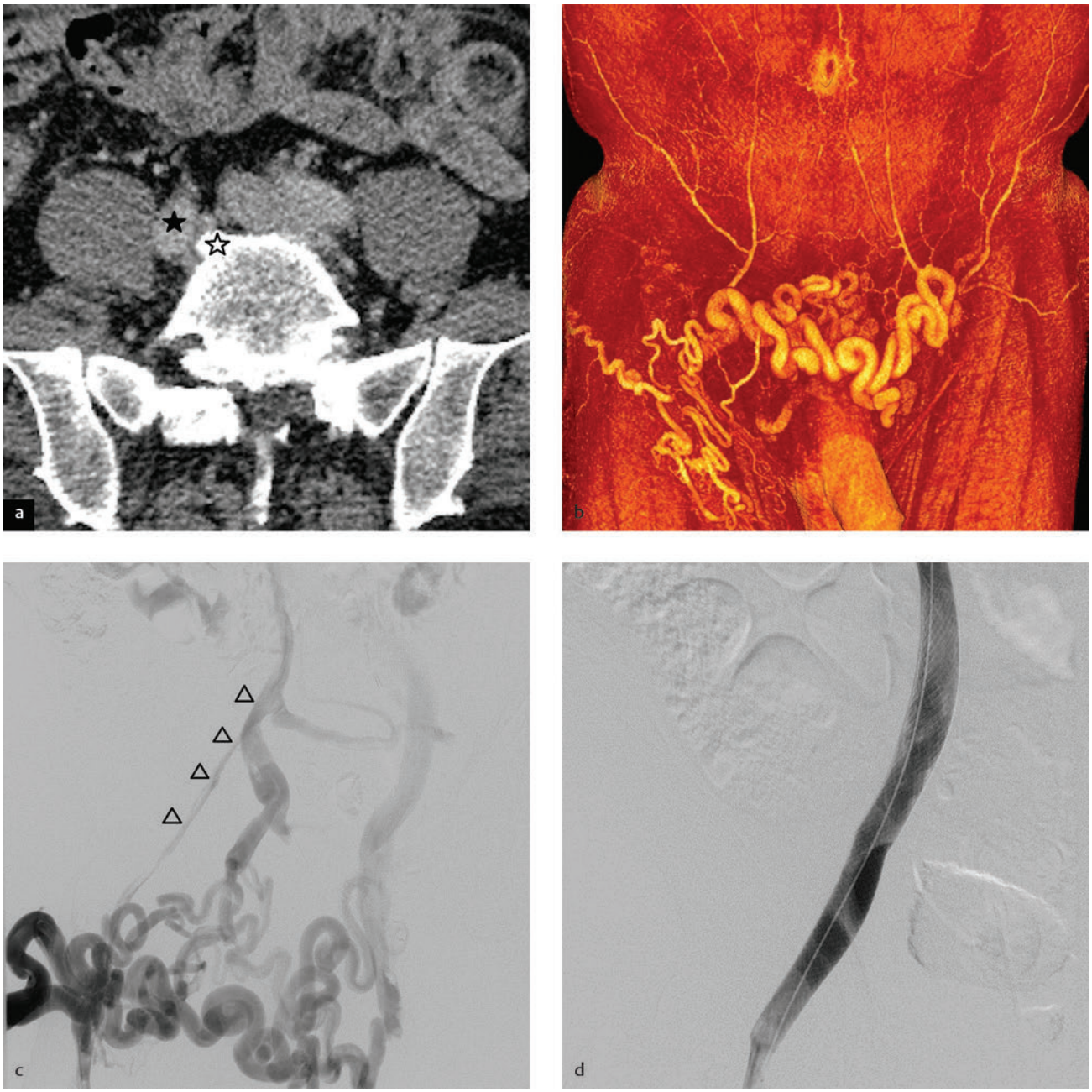

Fig. 3 A 67-year-old man with a remote history of right lower extremity deep vein thrombosis presented with symptomatic progressive right lower extremity varicose veins. Doppler ultrasound demonstrated chronic occlusion of the right external iliac vein with valvular incompetence of the right great saphenous vein. Physical examination showed diffuse varicosities in the right lower extremity, groin, and pubic regions. Axial image from the computed tomography (CT) venogram demonstrated **(A)** focal compression of the right common iliac vein (RCIV) between a bulky osteophyte (open star) and the right common iliac artery (black star). Coronal 3DRA image from a CT venogram demonstrated **(B)** inguinal and pubic varicosities as seen on physical examination. Initial catheter venography demonstrated **(C)** near occlusion of the entire RCIV (open arrows) with a small residual channel and abundant pubic collaterals. Digital subtraction venogram image post angioplasty and stent placement demonstrated **(D)** reestablished in-line outflow.

and require placement of stent constructs with additional radial force.

Ethical Approval and Conflict of Interest

All procedures performed in studies involving human participants were in accordance with the ethical standards of the institutional and/or national research committee and with the 1964 Helsinki declaration and its later amendments or comparable ethical standards with waiver of consent. Each author declares that he/she has no conflict of interest.

D. S. S., M. M., S. A., and E. J. M. have no financial disclosures or conflicts of interest.

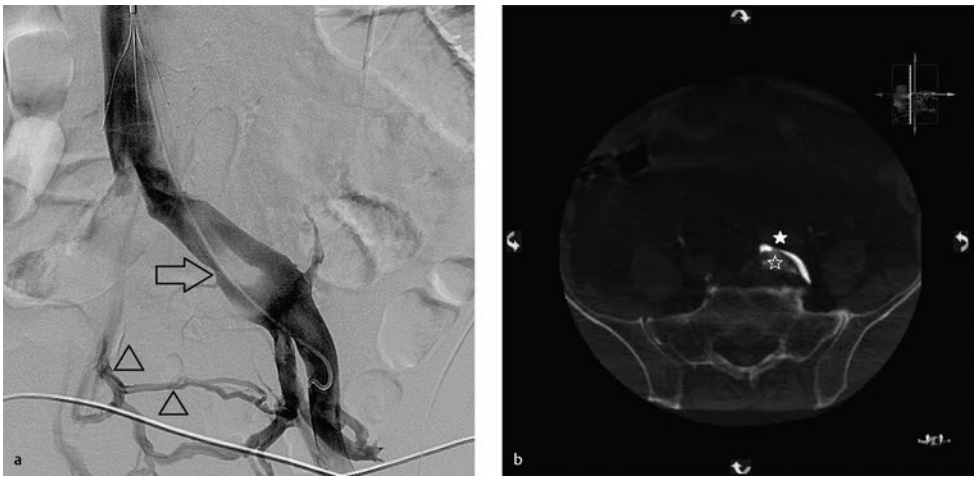

Fig. 4 A 77-year-old man presented in cardiac arrest and was found to have pulmonary embolism. Anticoagulation was complicated by intra-abdominal hemorrhage and an inferior vena cava (IVC) filter was placed. One month later, the patient subsequently tolerated oral anticoagulation and returned for filter removal. Venography prior to planned filter removal demonstrated **(A)** an apparent filling defect within the left common iliac vein (LCIV) (open arrow) with transpelvic collaterals (open arrowheads). This was interpreted as a residual thrombus and the filter was left in place. He presented 1 month later for possible filter removal at which time venography demonstrated the same finding. Intraprocedural cone-beam computed tomography venography confirmed **(B)** compression and fenestration of the LCIV by a bulky vertebral osteophyte (open star) and left common iliac artery (white star) causing a "pseudothrombus" appearance. The filter was removed.

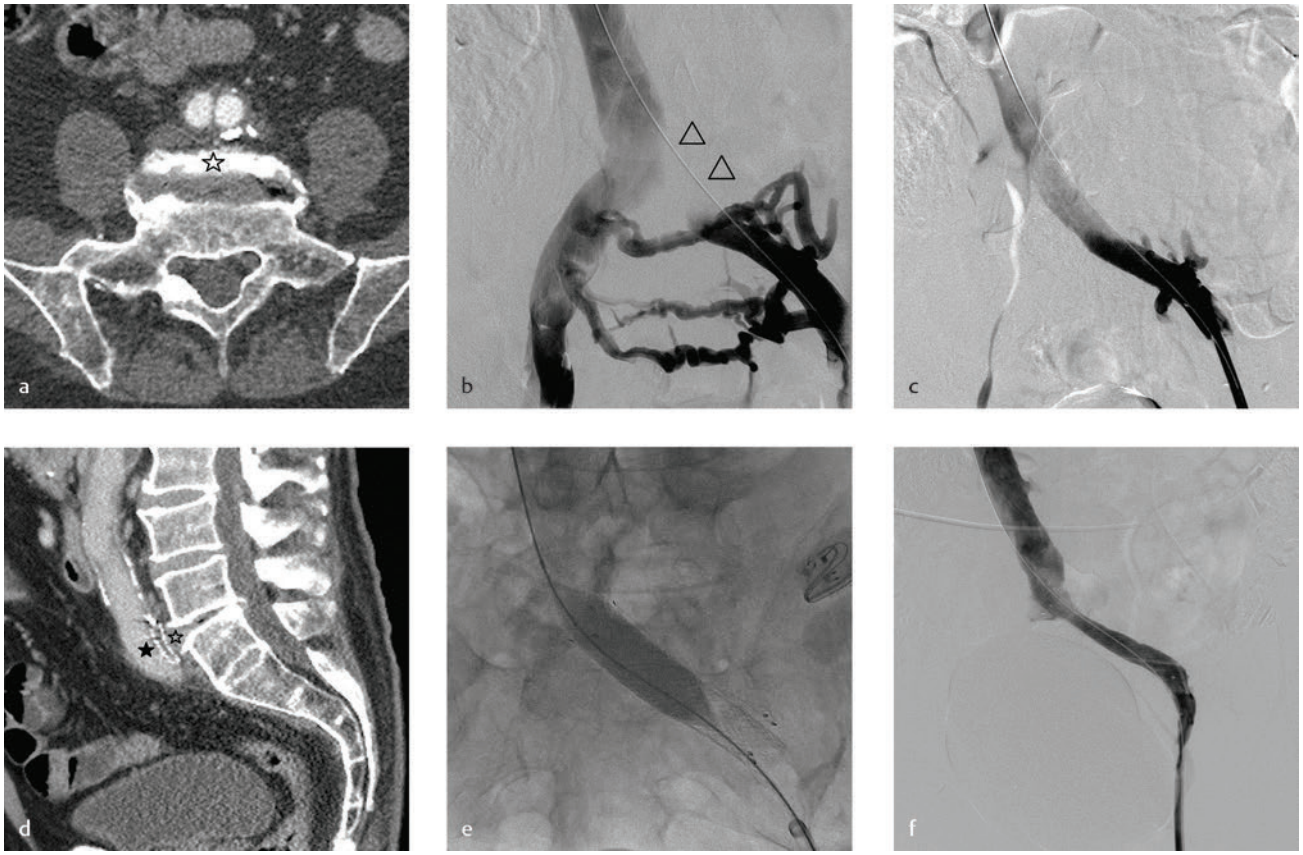

Fig. 5 A 75-year-old man with a history of peripheral artery disease status post aortobifemoral graft placement presents with chronic left lower extremity swelling. Prior axial computed tomography (CT) image demonstrated **(A)** compression of the left common iliac vein (LCIV) by a prominent lumbar disc-osteophyte complex (open star). Initial venogram demonstrated **(B)** LCIV occlusion (open arrowheads) and prominent transpelvic collaterals. Venogram post angioplasty and placement of a self-expanding bare metal stent (LifeStar Vascular Stent, C. R. Bard, Inc.) demonstrated **(C)** restoration of in-line flow but thinning of the contrast column. On Doppler ultrasound examination 1 week later, however, the LCIV stent was noted to be thrombosed. Sagittal image from a subsequent CT venogram demonstrated **(D)** severe compression of the stent between a prominent lumbar disc-osteophyte complex (open star) and the aortobifemoral bypass graft (black star). Following successful pharmacomechanical thrombolysis, the stent was relined with a larger diameter self-expanding bare metal stent (Wallstent, Boston Scientific) **(E)**. Subsequent venogram demonstrated (**F**) restoration of in-line outflow. The stent complex remained patent on a follow-up ultrasound at 5 months.

Acknowledgments
No acknowledgments.

References

1 May R, Thurner J. The cause of the predominantly sinistral occurrence of thrombosis of the pelvic veins. Angiology 1957;8(5):419–427
2 Cockett FB, Thomas ML, Negus D. Iliac vein compression—its relation to iliofemoral thrombosis and the post-thrombotic syndrome. BMJ 1967;2(5543):14–19
3 Butros SR, Liu R, Oliveira GR, Ganguli S, Kalva S. Venous compression syndromes: clinical features, imaging findings and management. Br J Radiol 2013;86(1030):20130284
4 Kim JY, Choi D, Guk Ko Y, Park S, Jang Y, Lee DY. Percutaneous treatment of deep vein thrombosis in May-Thurner syndrome. Cardiovasc Intervent Radiol 2006;29(4):571–575
5 Wax JR, Pinette MG, Rausch D, Cartin A. May-Thurner syndrome complicating pregnancy: a report of four cases. J Reprod Med 2014;59(5-6):333–336
6 Murphy EH, Davis CM, Journeycake JM, DeMuth RP, Arko FR. Symptomatic ileofemoral DVT after onset of oral contraceptive use in women with previously undiagnosed May-Thurner Syndrome. J Vasc Surg 2009;49(3):697–703
7 Urschel HC Jr, Patel AN. Surgery remains the most effective treatment for Paget-Schroetter syndrome: 50 years' experience. Ann Thorac Surg 2008;86(1):254–260, discussion 260
8 Nwoke F, Picel AC. May-Thurner syndrome and horseshoe kidney. J Vasc Interv Radiol 2016;27(3):369
9 Young L, Kwon J, Arosemena M, Salvatore D, DiMuzio P, Abai B. Symptomatic compression of right iliac vein after right iliac artery stent placement. J Vasc Surg Venous Lymphat Disord 2017;5(5):735–738
10 Woo EJ, Ogilvie RA, Krueger VS, Lundin M, Williams DM. Iliac vein compression syndrome from anterior perforation of a pedicle screw. J Surg Case Rep 2016;2016(2):rjw003