Blood Coagulation as a Continuous Process *)

From the Medical Department, University Hospital, Utrecht, Holland

J. Roos

In general, blood coagulation is considered one of the reactions which permit the organism to adapt to pathological conditions. When the continuity of a blood vessel is broken, blood coagulation is invaluable in preventing blood loss.

There are a number of arguments, however, which indicate that blood coagulation is more than only this mechanism of adaptation to pathology. In the first place there is the phenomenon of what might be called "purpura hypocoagulabilica". Whenever any one factor required in the normal development of blood coagulation is lacking, spontaneous hemorrhages may occur. This purpura hypocoagulabilica is seen in the presence of a deficiency of any of the coagulation factors, no matter in which part of the coagulation process it is located. Spontaneous hemorrhages are seen even among those patients in whom the normal coagulation factors are present, but whose serum contains abnormal proteins, which prevent the conversion of fibrinogen into fibrin (11, 12, 22, 32). Purpura hypocoagulabilica has also been observed among patients with normal coagulation factors, whose plasma exhibits a high fibrinolytic activity (1, 4, 6, 8, 31).

These clinical observations have led to the assumption of a causal relationship between deficient blood coagulation and spontaneous hemorrhage. There are only two factors common to all these coagulation disturbances: decreased fibrin formation occurring in them all, eventually, and a tendency to spontaneous hemorrhage. It could be concluded from the above that a shortage of fibrin is responsible for purpura hypocoagulabilica.

Comparing these pathological conditions with the normal situation, one arrives at the hypothesis that a non-deficient fibrin formation contributes to the normal impermeability of the blood vessels for erythrocytes. This fibrin is probably formed by the continuously active blood coagulation process which in this way would become a physiological function.

This assumption is supported by the observation that the proteins involved in the coagulation mechanism are normally more intensively consumed by the body than other proteins (2, 13, 24). In addition, several investigators claim to have demonstrated that coagulation factors (thrombin [30], convertin [15], heparin [25], fibrinolysin [10]) appear in circulating blood in an active phase.

*) This investigation was supported by a grant from Eli Lilly and Compagny, Indianapolis U.S.A.

This document was downloaded for personal use only. Unauthorized distribution is strictly prohibited.

There are thus a number of arguments which tend to indicate that blood coagulation takes place continually under normal conditions and that this process is partly responsible for the impermeability of vascular walls for erythrocytes. A defect in this continuous process would explain the appearance of spontaneous bleeding in cases of hypocoagulability. Several investigators in the field of coagulation have mentioned this hypothesis (2, 6, 16, 19, 20, 23, 29, 34), while Duguid (7) connected coagulation with the origin of atherosclerosis. However, there is no morphological proof of this hypothesis to be found in the literature. Certainly, Levene (21) was able to demonstrate that fibrin fibres are present in the intima of normal human aorta, but it is not clear from his investigation from which level of the intima these fibres originate.

For these reasons we have carried out a number of experiments with the object of comparing the morphology of the inner surface of rabbit aortae under conditions of normal coagulability with that obtained during decreased coagulability after the administration of dicumarol or heparin. Since the diameter of fibrin fibres (360 A — 2000 A [33]) falls below the resolving power of the light microscope, our experiments were carried out with the aid of the electron-microscope. We expected to gather most of the desired information, concerning the coherence of endothelial cells and concerning substances, if any, lying thereon, by studying the unfolded inner surface of vascular walls. For examination under the electron-microscope it was necessary to make an impression of this surface. We made this impression or replica in perspex, which was brought upon the endothelial surface, fixed in 10% formalin, in a solution in chloroform. The chloroform evaporates in 1 or 2 minutes so that the impression in perspex is made before the endothelium becomes desiccated. Since this perspex replica is not suitable for use with the electron-microscope, we made an impression of it on a very thin hydrocarbon film (König und Helwig [18]), which thus became a positive with respect to the endothelium. After removing the original perspex replica in chloroform and aceton and after shadowing the hydrocarbon membrane with gold-manganese at an angle of 4 : 1, the latter was examined in the electron-microscope. For reasons of comparison we also made impressions in perspex of fibrinclots which were handled in the same way as the aorta preparations.

However, the aorta is not a blood vessel through which red blood cells penetrate under conditions of diminished clotting power. We therefore carried out a supplementary experiment concerning the appearance of capillary endothelium, which does permit the passage of erythrocytes in such cases. We chose the glomeruli of rabbits as study material, which was fixed in 1% osmium-tetroxide in a isotonic buffer of pH 7,3 (Palade [26], modification Rhodin [27]). After embedding in methacrylate the specimens are cut in the micro-

This document was downloaded for personal use only. Unauthorized distribution is strictly prohibited.

tome constructed by Elbers (9). The electron-microscope used was a Philips type 75. Our experimental methods are fully described elsewhere (28).

A comparison of aorta impressions made under conditions of normal- and hypocoagulability revealed two points of discrepancy:

1. In all eleven normal rabbits we observed fibrils lying on the endothelium (fig. 1 and 2). These were always seen lying perpendicular to the axis of the blood vessel, usually between two nuclei. For a number of reasons it is unlikely that these fibrils were artefacts: they always had the same arrangement, they were never seen in impressions of other surfaces (glass, fixed gelatin or cellophane) and in contrast to real impurities the fibres always had a shadow. Their form and size did not differ from those of fibrin fibres (fig. 3 and 4). The most important argument, however, for equating these filaments with fibrin, is that we found them only among 4 of the 14 rabbits with a decreased coagulability, and then only sporadically. The preparation of specimens in the normal and hypocoagulable groups differed in only one respect, namely, in the treatment of the rabbits in the second group with anticoagulants. The difference between normal and decreased coagulability amounts to a diminished fibrinforming ability in the latter condition. For this reason it is probable that the infrequent appearance of fibrils on the internal vascular walls in our hypocoagulable group corresponds with the presence of fibrin in lesser amounts.

We cannot definitely prove these fibrils to be fibrin. Our replicatechnique does not reproduce the axial periodicity characteristic of fibrin (33) (fig. 4). Supplementary experiments in this area are deemed desirable. We possibly succeeded in producing an increase in the number of fibres by means of an intravenous thrombin infusion following Jürgens and Studer (17).

2. In normal rabbits the majority of endothelial cell nuclei appeared distinctly to protrude into the lumen (fig. 5). Although, through in illusionary interpretation, the nuclei in the photos sometimes appear as indentations, it is very probable that in the blood vessel they protrude into the lumen. In rabbits with a decreased coagulability most of the nuclei were flat (fig. 6). There were no differences between the rabbits treated with dicumarol and those treated with heparin. This level appearance need not indicate that the nuclei became flattened. Anatomicopathologically it is known that in the area of an inflammatory process the cytoplasm of endothelial cells can become swollen (Boyd [5]). There is in this condition, as well as in the case of hypocoagulability, evidence of increased permeability of the endothelial layer. It is therefore probable that the flattened appearance of the nuclei in hypocoagulability is the result of a swelling of the cytoplasm of the endothelial cells.

The observations discussed above indicate the probability that normal blood coagulation contributes in at least two ways to the impermeability of endothelium for red blood cells: by the deposition of fibrin fibres, and by the

This document was downloaded for personal use only. Unauthorized distribution is strictly prohibited.



Fig. 1: Aorta rabbit, normal clotting power. 3700×, 80 KV. Fibres lying on the endothelium.

Fig. 2: Aorta rabbit, normal clotting power. 3700×, 80 KV. The fibres are lying perpendicular to the axis of the nuclei and to the borderlines of the endothelial cells.

This document was downloaded for personal use only. Unauthorized distribution is strictly prohibited.

Fig. 3 : Aorta rabbit, normal clotting power. 12 000 ×, 80 KV. The fibres seen at a higher magnification.

Fig. 4 : Replica fibrinclot. 12 000 ×, 80 KV.

This document was downloaded for personal use only. Unauthorized distribution is strictly prohibited.

Fig. 5 : Aorta rabbit, normal clotting power. 3700×, 80 KV. The nuclei of the endothelial cells protrude into the vascular lumen.

Fig. 6 : Aorta rabbit, diminished clotting power. 3700×, 80 KV. The nuclei are less prominent into the lumen.

This document was downloaded for personal use only. Unauthorized distribution is strictly prohibited.

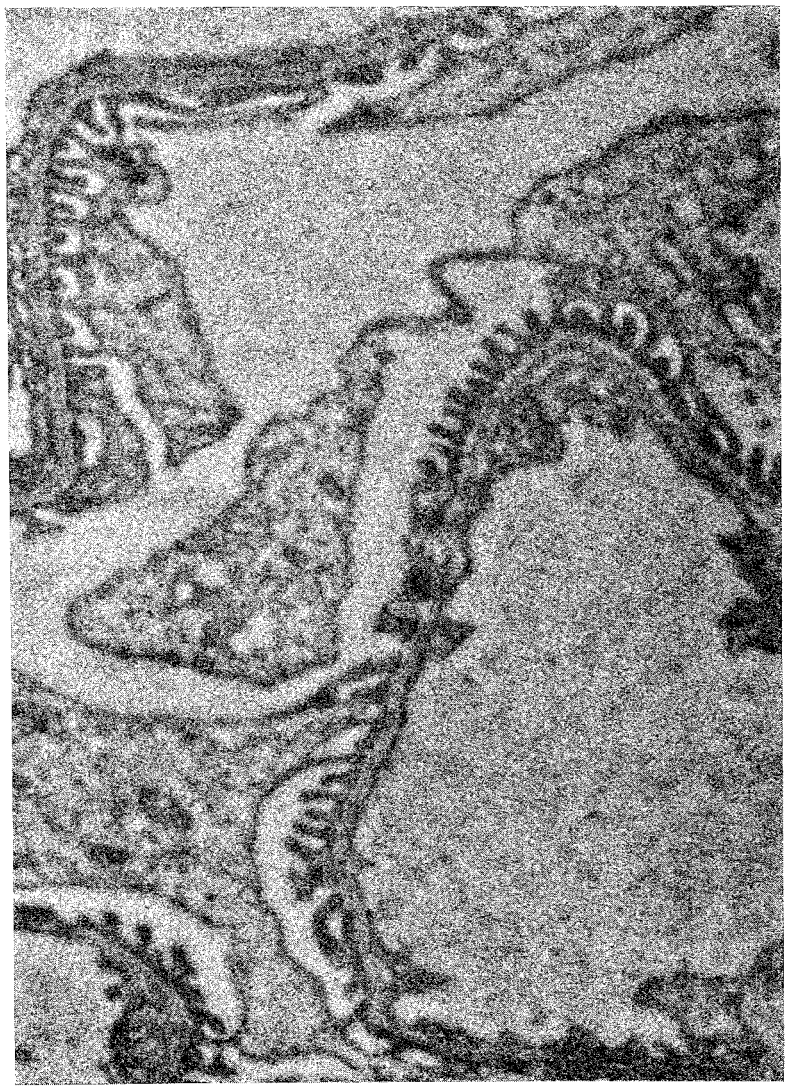

Fig. 7: Glomerulus rabbit, normal clotting power. 18000×, 60 KV. Bottom right and top left a capillary.

influencing of the degree of swelling of endothelial cell cytoplasm. How this influence is brought to bear, and why erythrocytes can penetrate endothelium during decreased coagulability remain hypothetical.

To obtain more information concerning the latter problem, we have carried out the experiment concerning the morphology of glomeruli under conditions of normal coagulability (5 rabbits) and dicumarol-induced hypocoagulability (4 rabbits). The latter animals all had a more or less severe hematuria. We noted

This document was downloaded for personal use only. Unauthorized distribution is strictly prohibited.

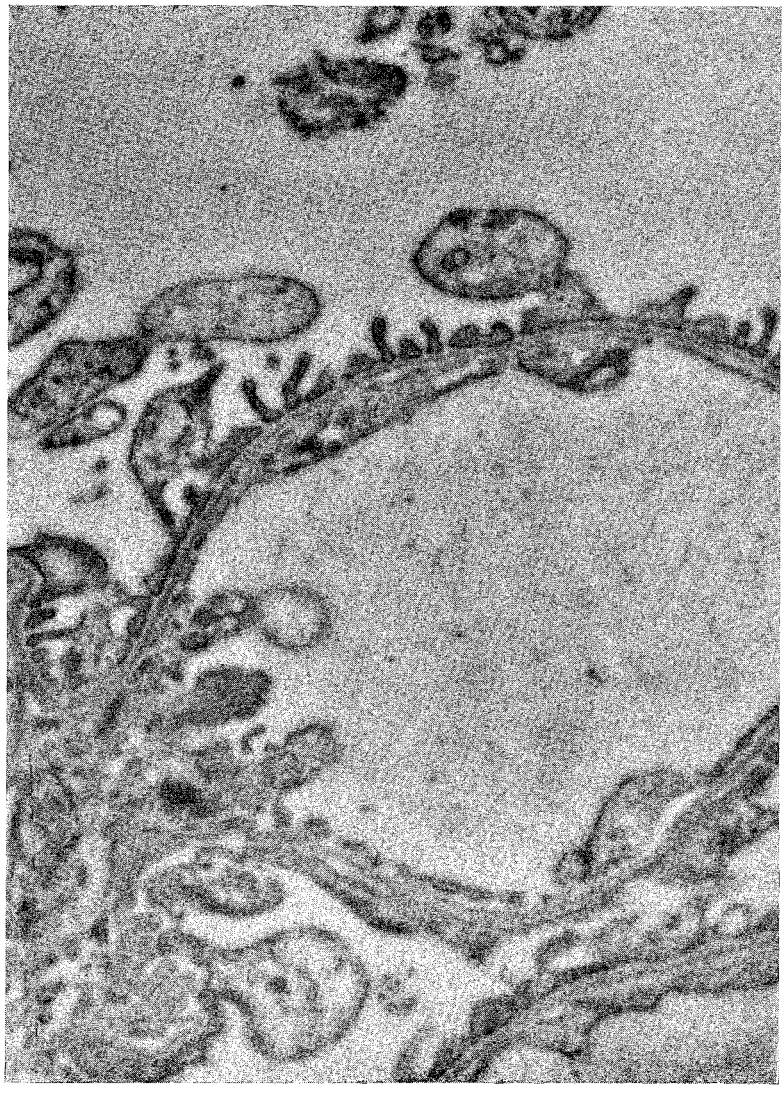

Fig. 8: Glomerulus rabbit, diminished clotting power, hematuria. 18 000 ×, 60 KV. A capillary lumen. No obvious difference with fig. 7.

no obvious differences in the aspect of the structures between blood and urine spaces (fig. 7 and 8). We definitely saw no defects through which an erythrocyte could penetrate. Under conditions of hypocoagulability, the endothelium exhibited a possible increase in the number of pores and vacuoles, but the number of kidneys which we examined and the relative invalidity of comparison of specimens fixed in osmiumtetroxyde prohibit us from stating this with any degree of certainty.

This document was downloaded for personal use only. Unauthorized distribution is strictly prohibited.

Summary

In order to study the phenomenon of spontaneous hemorrhages in cases of diminished clotting power, we performed an investigation with the aid of the electron-microscope by means of a replica technique, on the aspect of aorta endothelium in two groups of rabbits, the first with a normal clotting power, the second with a hypocoagulability. Comparison of these two groups revealed two points of discrepancy. In the first place, in all the preparations of normal rabbits we saw fibres lying perpendicular to the borderlines of endothelial cells. These fibres were hardly seen under conditions of hypocoagulability, which is one of the arguments for equating these filaments with fibrin. In the second place, the nuclei of endothelial cells were less prominent into the vascular lumen in hypocoagulability than in cases of normal clotting power. From these observations and from some theoretical arguments we came to the hypothesis that blood coagulation is a continuous process which lays down fibrin fibres on the endothelium and which influences the swelling of the cytoplasm of endothelial cells. We could not get more information concerning the problem of how erythrocytes can penetrate endothelium in cases of hypocoagulability by studying the aspect of the blood-urine barrier in the glomeruli in the same two groups of rabbits.

Acknowledgment. I wish to thank Prof. F. L. J. Jordan, on whose instigation this work was undertaken, and Dr. P. F. Elbers and the Centre for Electron-Microscopy in Utrecht for their kind help with the electron-microscopy and photography.

Résumé

Afin d'étudier l'hémorragie spontanée pendant l'hypocoagulabilité, nous avons observé l'endothélium de l'aorte dans deux groupes de lapins, un groupe contrôle et un groupe traité aux anticoagulants. Les deux groupes se distinguent en deux points. Dans le groupe contrôle nous avons observé des fibres posés verticalement sur les cellules endothéliales de l'aorte. Ces fibres font défaut dans le second groupe, ce qui incite à croire que ces fibres sont des filaments de fibrine.

La seconde différence est que les noyaux des cellules endothéliales sont moins rapprochés de la lumière du vaisseau chez les animaux traités que dans le groupe non traité. Se basant sur ces données et à l'aide de quelques arguments théoriques, nous formulons l'hypothèse que la coagulation sanguine est un processus continu déposant des fibres de fibrine sur l'endothélium influançant également le gonflement du cytoplasma de l'endothèle.

En étudiant les glomérules dans les deux groupes d'animaux, nous ne sommes pas parvenu à obtenir plus de renseignements sur le passage d'érythrocytes à travers l'endothélium dans les cas d'hypocoagulabilité.

This document was downloaded for personal use only. Unauthorized distribution is strictly prohibited.

Zusammenfassung

Um das Phänomen der Spontanblutungen bei Fällen mit verminderter Gerinnungsfähigkeit zu studieren, führten wir Untersuchungen mit dem Elektronenmikroskop mit Hilfe einer Replikationstechnik am Aortenendothel bei zwei Gruppen von Kaninchen durch. Bei der einen Gruppe war die Gerinnungsfähigkeit herabgesetzt, die andere diente als Kontrollgruppe. Der Vergleich ergab zwei wesentliche Unterschiede: Erstens sahen wir in allen Präparaten, die von normalen Kaninchen stammten, Fasern, welche senkrecht zu den Grenzen der Endothelzellen angeordnet waren. Diese Fasern wurden bei herabgesetzter Gerinnungsfähigkeit kaum gesehen. Dies war für uns ein wichtiges Argument, diese Fäden mit Fibrin gleichzusetzen.

Zweitens ragen die Kerne der Endothelzellen bei Tieren, deren Gerinnungsfähigkeit herabgesetzt ist, weniger in das Gefäßlumen als bei den Kontrolltieren. Auf Grund dieser Beobachtungen und einiger theoretischer Erwägungen kamen wir zu der Hypothese, daß Blutgerinnung ein fortwährend ablaufender Vorgang ist, durch den Fibrinfäden auf den Endothelzellen abgelagert werden und durch den die Schwellung des Cytoplasmas der Endothelzellen beeinflußt wird. Zu dem Problem, wie die Erythrozyten das Endothel in Fällen mit herabgesetzter Gerinnungsfähigkeit zu durchsetzen imstande sind, konnten wir durch die Untersuchung der Blut-Harn-Barrier in den Glomerula derselben zwei Tiergruppen keine weiteren Anhaltspunkte gewinnen.

References

(1) Aboulker, P., Soulier, J. P. et Larrieu, M. J.: Syndrome hémorragique avec fibrinolyse associé au cancer de la prostate. Presse méd. **63:** 353 (1955).
(2) Alexander, B.: Coagulation, hemorrhage and thrombosis. New Engl. J. Med. **252:** 432/484/526 (1955).
(3) Astrup, T.: Fibrinolysis in the organism. Blood **11:** 781 (1956).
(4) Bennike, T. and Müllertz, S.: Haemorrhagic diathesis associated with fibrinogenopenia and fibrinolysis. Acta Haemat. **8:** 147 (1952).
(5) Boyd, W.: A textbook of pathology. Lea & Febiger, Philadelphia, 1947.
(6) Copley, A. L.: Effet capilloragique de la fibrinolysine. Arch. int. Pharmacodyn. **99:** 426 (1954).
(7) Duguid, J. B.: Mural thrombosis in arteries. Brit. Med. Bull. **11:** 36 (1955).
(8) Eichenberger, E. und Schmidhauser-Kopp, M.: Thrombelastographische Untersuchungen über die Fibrinolyse. Helv. physiol. pharmacol. Acta **12:** C 69 (1954).
(9) Elbers, P. F.: To be published.
(10) Fearnley, G. R. and Lackner, R.: The fibrinolytic activity of normal blood. Brit. J. Haemat. **1:** 189 (1955).
(11) Frick, P. G.: Inhibition of conversion of fibrinogen to fibrin by abnormal proteins in multiple myeloma. Am. J. Clin. Pathol. **25:** 1263 (1955).
(12) Gehmacher, K., Herold, G. und Reimer, E. E.: Gerinnungsstörung beim Plasmozytom. Wien. Z. Inn. Med. **35:** 245 (1954).

This document was downloaded for personal use only. Unauthorized distribution is strictly prohibited.

(13) Gitlin, D. and Borges, W. H.: Studies on the metabolism of fibrinogen in two patients with congenital afibrinogenemia. Blood **8**: 679 (1953).
(14) Greig, H. B. W.: Inhibition of fibrinolysis by alimentary lipaemia. Lancet 2, p. 16 (1956).
(15) Jensen, H., Gray, E. and Schaefer, E. H.: Formation of blood thrombokinase. Acta Haemat. **13**: 377 (1955).
(16) Jordan, F. L. J.: Symptomenleer en differentiële diagnostiek. Bijleveld, Utrecht p. 199, 1950.
(17) Jürgens, R. und Studer, A.: Zur Wirkung des Thrombins. Helv. physiol. pharmacol. Acta **6**: 130 (1948).
(18) König, G. und Helwig, G.: Über dünne aus Kohlenwasserstoffen durch Elektronen- und Ionenbeschuß gebildete Schichten. Zschr. f. Physik **129**: 491 (1951).
(19) Laki, K.: The clotting of fibrinogen. Blood **8**: 845 (1953).
(20) Lasch, H. G.: Hemorrhage in liver disease. 6th Congress Int. Soc. Hematology, Boston, p. 388, 1956.
(21) Levene, C. I.: The electron-microscopy of atheroma. Lancet 2, p. 1216 (1955).
(22) Lüscher, E. und Labhart, A.: Blutgerinnungsstörung durch βγ-Globuline. Schweiz. Med. Wschr. **79**: 598 (1949).
(23) Macfarlane, R. G.: Discussion on the factors concerned in blood coagulation and their clinical significance. Proc. Roy. Soc. Med. **38**: 399 (1945).
(24) Madden, R. E. and Gould, R. G.: The turnover rate of fibrinogen in the dog. J. Biol. Chem. **196**: 641 (1952).
(25) Nilsson, I. M. and Wenckert, A.: Demonstration of a heparinlike anticoagulant in normal blood. Acta Med. Scand. Suppl. 297 (1954).
(26) Palade, G. E.: A study of fixation for electron microscopy. J. Exp. Med. **95**: 285 (1952).
(27) Rhodin, J.: Correlation of ultrastructural organization and function in normal and experimentally changed proximal convoluted tubule cells of the mouse kidney. Aktibolaget Godvil, Stockholm, 1954.
(28) Roos, J.: Purpura Hypocoagulabilica. Thesis Utrecht 1957.
(29) Spaet, Th. H.: Vascular factors in the pathogenesis of haemorrhagic syndromes. Blood **7**: 641 (1952).
(30) Sternberger, L. A.: Preliminary clinical evaluation of thrombin recovery test. J. Amer. med. Ass. **150**: 1591 (1952).
(31) Tagnon, H. J., Whitmore, W. F., Shulman, P. and Kravitz, S. C.: The significance of fibrinolysis occurring in patients with metastatic cancer of the prostate. Cancer **6**: 63 (1953).
(32) Uehlinger, E.: Über eine Blutgerinnungsstörung bei Dysproteinämie (Beitrag zur Kenntnis der körpereigenen Antikoagulantia). Helv. med. Acta **16**: 508 (1949).
(33) van Zandt Hawn, C. and Porter, K. R.: The fine structure of clots formed from purified bovine fibrinogen and thrombin: a study with the electron microscope. J. exp. Med. **86**: 285 (1947).
(34) Zweifach, B. W.: Structural makeup of capillary wall. Ann. N. Y. Acad. Sci. **61**: 670 (1955).

This document was downloaded for personal use only. Unauthorized distribution is strictly prohibited.