

XI cranial nerve cervical schwannoma – Case report

Roger Schmidt Brock¹, Marcelo Viana da Silva Barroso², Iuri Santana Neville³, Marcos Queiroz Teles Gomes⁴, Alberto Capel Cardoso⁵, Mario Augusto Taricco⁶, Manoel Jacobsen Teixeira⁷

Division of Neurosurgery, Clinics Hospital, University of Sao Paulo, Sao Paulo, SP, Brazil.

ABSTRACT

Cisternal spinal accessory schwannoma are still a rare condition without neurofibromatosis with only 32 cases reported so far. We describe a cisternal accessory schwannoma presented in a 36-year-old woman with posterior cervical pain and cervical mielopathy, defined by grade IV tetraparesia. A suboccipital craniectomy with C1 posterior arch resection was performed. During microsurgical dissection together with electrophysiological monitoring and nerve stimulation tumor was identified as having the spinal accessory root as its origins. Carefully intraneural dissection was then performed with complete lesion removal, histopathological examination confirmed the hypothesis of schwannoma. The patient was free from pain and improved her neurological status with no accessory nerve palsy. Complete surgical resection is indicated for such lesions and can be achieved with good outcome.

KEYWORDS

Neurilemmoma, accessory nerve diseases, microsurgery.

RESUMO

Schwannoma do nervo acessório cervical – Relato de caso

O schwannoma do ramo espinhal do nervo acessório em sua porção cisternal, quando não associado à neurofibromatose, é uma condição rara, com apenas 32 relatos de caso na literatura. O diagnóstico diferencial da lesão deve ser atentado, principalmente no que diz respeito à preservação da função motora do nervo acessório. Este é um relato de caso de uma paciente do sexo feminino de 36 anos com queixa de cervicálgia associada à mielopatia cervical compressiva secundária à lesão expansiva intradural, extramedular, estendendo-se do forame magno até a porção superior da lâmina de C2. A paciente foi submetida a uma craniectomia de fossa posterior e ressecção do arco posterior de C1. Durante exploração cirúrgica, auxiliada por monitoração eletrofisiológica e estimulação neural, foi identificado que a lesão tinha origem no ramo espinhal do nervo acessório direito. Foi então ressecada de forma completa com preservação dos fascículos íntegros do nervo de origem. O exame anatomopatológico confirmou a hipótese de schwannoma. A paciente evoluiu sem dor e com melhora do quadro neurológico, sendo preservada a função do nervo acessório. O schwannoma do ramo espinhal do nervo acessório é uma condição rara. A ressecção cirúrgica total é o tratamento de escolha para esses pacientes e pode ser alcançada sem lesões neurológicas significativas secundárias ao ato cirúrgico.

PALAVRAS-CHAVE

Neurilemmoma, doenças do nervo acessório, microcirurgia.

- 1 Coordinator of the Spine and Spinal Cord Pathology Group, Division of Neurosurgery, Clinics Hospital, University of Sao Paulo (USP), Sao Paulo, SP, Brazil.
- 2 Neurosurgeon, fellow of the Spine and Spinal Cord Pathology Group, Division of Neurosurgery, Clinics Hospital, USP, Sao Paulo, SP, Brazil.
- 3 Medical-resident of the Division of Neurosurgery, Clinics Hospital, USP, Sao Paulo, SP, Brazil.
- 4 Assistant physician of the Division of Neurosurgery, Clinics Hospital, USP, Sao Paulo, SP, Brazil.
- 5 Neurosurgeon. Contributor physician of the Spine and Spinal Cord Pathology Group. Division of Neurosurgery, Clinics Hospital, University of Sao Paulo, Sao Paulo, SP, Brazil.
- 6 Neurosurgeon and professor of the discipline of Neurosurgery, Medical School of the USP, Sao Paulo, SP, Brazil.
- 7 Professor and chairman, Division of Neurosurgery of the Department of Neurology, Clinics Hospital, Medical School of the USP, Sao Paulo, SP, Brazil.

Introduction

Intracranial neurinomas represent less than 10% of all primary brain tumors and usually arise from the vestibular and trigeminal nerves;^{1,2} less than 22% of all intracranial schwannomas are “non-acoustic”.³ Rarely originated from pure motor nerves,⁴ especially in the absence of neurofibromatosis, the accessory nerve schwannomas account for an extremely rare condition with only 32 cases described in the literature so far. It's location other than the jugular foramen, in the cervical cisternal space is even more rare with only two other reports in the literature.

The differential diagnosis and the suspicion of such lesions are important in surgery planning and nerve function preservation.

Case report

A 36-years-old woman presented with a six months history of posterior neck pain aggravated during Valsalva maneuver and the lifting of the head; she felt little better with regular pain medication. She also referred, when questioned, a light difficult handling objects with her left hand.

Her neurological exam revealed a spastic tetraparesis, muscular strength grade IV; deep motactile reflexes exacerbated in both superior and inferior members; Hoffman and Babinski signs was positive bilaterally. She presented normal static and dynamic balance as well as proprioception and artrestesy; also, there was no alteration in tactile, thermic and painful sensitivity.

Magnetic resonance imaging (MRI) of the cervical spine showed an intradural, extramedullary mass at the postero-lateral aspect of cervical spinal canal at C1-C2 level, compressing the spinal cord to the front and to the right. The well-defined tumor was hypointense on the T1-weighted image, hyperintense on the T2-weighted image and homogeneously enhanced after intravenous administration of gadolinium-diethylenetriaminepentaacetic-acid (Figures 1A and B).

The surgical procedure was carried out with intraoperative electrophysiological monitoring with both somato-sensitive evoked potential and motor evoked potential for a safer approach with most complete resection, under general anesthesia and prone positioned. We utilized a suboccipital craniectomy with resection of the posterior arch of C1 for better exposure of the dura-mater in the region of the magna cistern.

After opening of the dura large lesion posterior and to the left of the spinal cord was well visualized dislocating it to the right and anteriorly (Figures 2A and B).

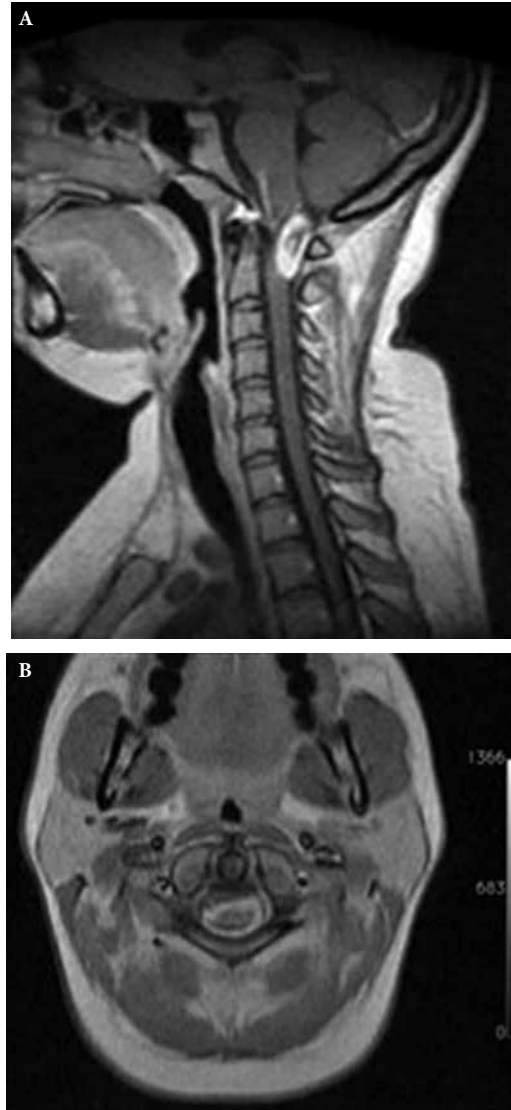

Figure 1 - A (T1) Weighted sagittal plane MRI showing the lesion, enhanced after administration of gadolinium. B (T2) - Weighted axial plane MRI.

The lesion presented with a grayish pattern with no area of dural implantation, thus favoring the diagnostic hypothesis of schwannoma. After complete microsurgical resection with the opening of the tumor and its debulking, through the arachnoid plane, it was separated from the impaired cranial nerve, which was confirmed to be the cervical root of the accessory nerve by contraction of the trapezius muscle during electrophysiological stimulation (Figure 3).

The lesion was completely removed with preservation of the nerve root. The patient presented with no new deficit in the immediate post-operative and there was improvement of the spasticity and muscular strength in her one-year follow-up. During this period, post-op the MRI confirmed total resection with no tumor recurrence (Figures 4A and B).

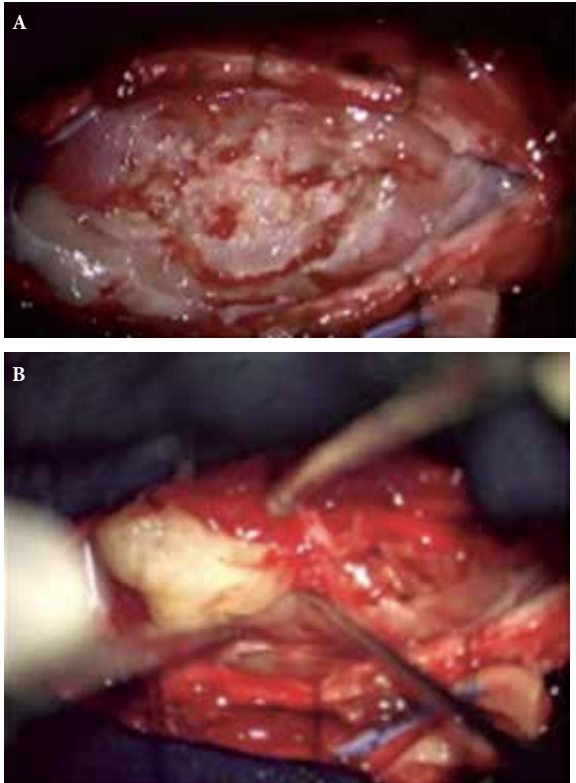


Figure 2A-B – A lesion with well-defined margins was seen after the opening of the dura-mater.

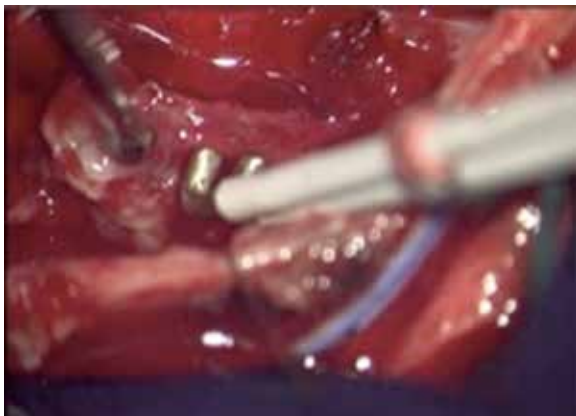

Figure 3 – Electrophysiological stimulation confirming the accessory nerve location.

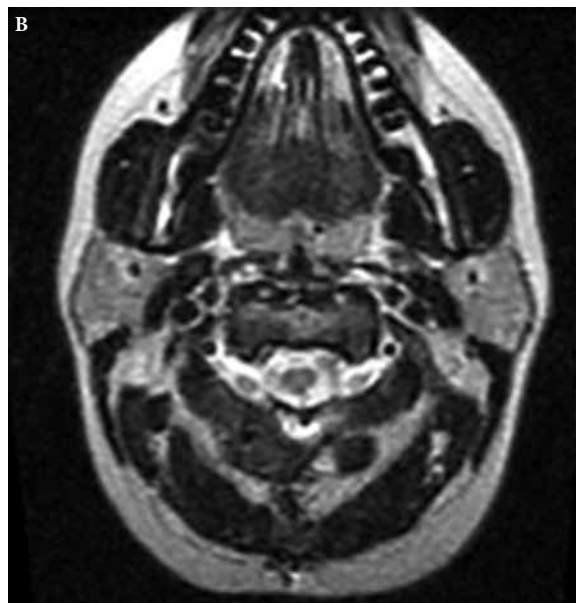
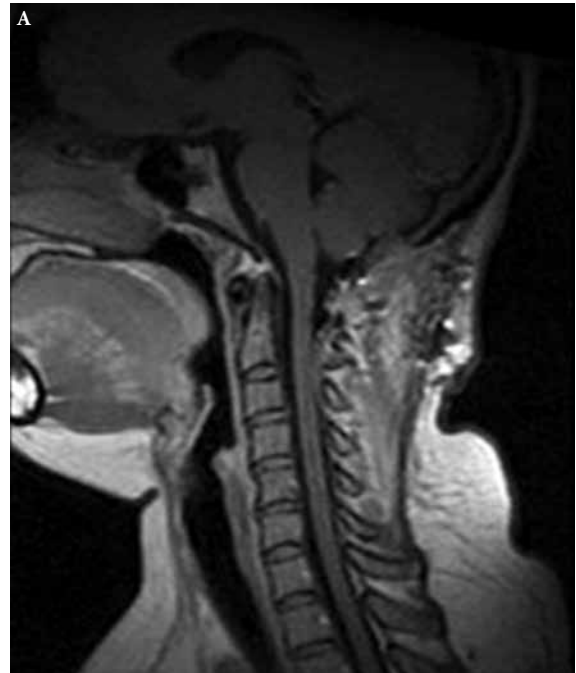
Figure 4A-B (T1) – Weighted sagittal plane and T2-weighted axial plane MRI, respectively, showed complete resection.

Discussion

Even with the advances in MRI technology making possible to detect smaller³ and, sometimes, asymptomatic neurinomas, the ones located in the foramen magnum are still extremely rare. The vast majority of these lesions arise from the vestibulocochlear nerve. The ones of lower cranial nerves usually come from the jugular foramen being mostly from the glossopharyngeal or vagal nerve. The accessory nerve is the least common site of origin.⁵⁻⁸ The correct nerve origin is almost

impossible to diagnose prior to surgery due to crowding of the lower cranial nerves⁷⁻¹⁰ and, even during surgery, in up to 65% of the cases, the site of origin cannot be accurately identified.⁹⁻¹¹ Schwannomas arising from the accessory nerve are classified by their anatomical location as intrajugular, intracisternal (the majority) and cervical (2 cases).^{1,12} They usually present with neck pain, headache, nausea, vomiting and, the intrajugular kind, with hearing disturbances, cerebellar dysfunction, myelopathy, different combinations of 5th to 12th cranial nerve palsies and jugular foramen syndrome (loss of taste

in the posterior third of the tongue, vocal cord paralysis, dysphagia, weakness of sternocleidomastoid and trapezius muscles).^{7,10,13,14} On computed tomographic scan (CT), the accessory nerve schwannoma are hypo or isodense, eventually enlargement of the jugular foramen is seen and rarely calcified component.^{7,13,15-17} The MRI findings are typically regularly shaped contour, low T1, high T2 signals, different degrees of homogenous contrast enhancement, lack of edema and may present solid or with cystic degeneration (in larger tumors).^{7,9,12-14,18-24} Total surgical resection is the recommended standard treatment for such lesions as it is considered curative.^{7,13,20} There is scarce literature regarding radiosurgical option for these tumors but a regrowth rate of 25% is seen in some series.²⁵ Surgical removal can be achieved by suboccipital uni or bilateral craniotomy/craniectomy with or without C1 laminectomy for most intracysternal accessory nerve schwannomas.^{4,10,12,18,20,23,26-32} And, even though the spinal accessory nerve is commonly sacrificed, there are low rates of postoperative deficits.¹³ We believe that intra-op electrophysiological monitoring helps in identifying nerve function and that a carefully intra-arachnoid plane dissection and nerve preservation with complete tumor removal is feasible.

Competing interests

The authors declare no conflict of interest.

References

- Hatashita S, Mitsuhashi T, Kurosu A, Ueno H. Schwannoma of the spinal accessory nerve: case report. *Neurol Med Chir (Tokyo)*. 2003;43(10):501-4.
- Sarma S, Sekhar LN, Schessel DA. Nonvestibular schwannomas of the brain: a 7-year experience. *Neurosurgery*. 2002;50(3):437-48.
- Takumi I, Isayama K, Osamura RY, Kobayashi S, Teramoto A. Intracisternal neurinoma of the C1 posterior root. *Acta Neurochir (Wien)*. 2005;147(11):1189-92.
- Caputi F, de Sanctis S, Gazzeri G, Gazzeri R. Neuroma of the spinal accessory nerve disclosed by a subarachnoid hemorrhage: case report. *Neurosurgery*. 1997;41(4):946-50.
- Fink LH, Early CB, Bryan RN. Glossopharyngeal schwannomas. *Surg Neurol*. 1978;9(4):239-45.
- Hakuba A, Hashi K, Fujitani K, Ikuno H, Nakamura T, Inoue Y. Jugular foramen neurinomas. *Surg Neurol*. 1979;11(2):83-94.
- Jung TY, Jung S, Kim IY, Kang SS. Intracisternal schwannoma of the spinal accessory nerve: a case report. *Skull Base*. 2006;16(3):175-9.
- Pluchino F, Crivelli G, Vaghi MA. Intracranial neurinomas of the nerves of the jugular foramen. Report of 12 personal cases. *Acta Neurochir (Wien)*. 1975;31(3-4):201-21.
- Iwasaki K, Kondo A. Accessory nerve neurinoma manifesting with typical jugular foramen syndrome. *Neurosurgery*. 1991;29(3):455-9.
- Shiroyama Y, Inoue S, Tsuha M, Abiko S, Aoki H. [Intracranial neurinomas of the jugular foramen and hypoglossal canal]. *No Shinkei Geka*. 1988;16(3):313-9.
- Fukui S, Miyazawa T, Okawa H, Ishihara S, Terahata S, Tamai S, et al. [A case of jugular foramen neurinoma originating from glossopharyngeal nerve]. *No Shinkei Geka*. 1997;25(1):47-51.
- Julow J. Neurinoma of spinal accessory nerve. Report of two cases. *Acta Neurochir (Wien)*. 1983;69(3-4):219-24.
- Kurokawa R, Tabuse M, Yoshida K, Kawase T. Spinal accessory schwannoma mimicking a tumor of the fourth ventricle: case report. *Neurosurgery*. 2004;54(2):510-4.
- Ortiz O, Reed L. Spinal accessory nerve schwannoma involving the jugular foramen. *AJNR Am J Neuroradiol*. 1995;16(Suppl 4):986-9.
- Solymosi L, Wassmann H, Bonse R. Diagnosis of neurinoma in the region of the jugular foramen – a case report. *Neurosurg Rev*. 1987;10(1):41-6.
- Sugawara A, Kowada M, Nishino K, Sakamoto T. [Jugular foramen neurinoma – report of a case (author's transl)]. *No Shinkei Geka*. 1981;9(7):829-33.
- Suzuki S, Yamaguchi K, Sakai H, Tanji H, Higa K. [Intracranial neurinoma of jugular foramen – report of a case and reference, its clinical manifestations (author's transl)]. *No Shinkei Geka*. 1977;5(4):379-84.
- Fransen P, Doooms G, Mathurin P, Thauvoy C, Stroobandt G. [Juxtatabular neurinoma of the spinal accessory nerve]. *Neurochirurgie*. 1992;38(3):173-8.
- Kaynar MY, Hanci M, Sarioglu AC. Intraspinal schwannoma of the accessory nerve. *Br J Neurosurg*. 1999;13(4):429-31.
- Lanotte M, Massaro F, Scienza R, Faccani G. Intracisternal schwannoma of the spinal accessory nerve presenting as a normal pressure hydrocephalus syndrome. Case report and review of the literature. *Neurosurg Rev*. 1994;17(3):225-7.
- Lee SK, Park K, Kong DS, Cho YS, Baek CH, Nam DH, et al. Surgical tactics and outcome of treatment in jugular foramen schwannomas. *J Clin Neurosci*. 2001;8(Suppl 1):32-9.
- Matsushima T, Fukui M, Matsunaga M, Kitamura K, Hasuo K. Accessory nerve neurinoma mimicking a brain stem tumor on angiography: report of a case. *Neurosurgery*. 1985;16(6):839-42.
- Soo SJ, Irie K, Fujiwara T, Kuyama H, Nagao S. [A case of accessory nerve neurinoma presenting an intracisternal tumor]. *No Shinkei Geka*. 1995;23(8):723-6.
- Uchino A, Hasuo K, Fukui M, Matsushima T, Tamura S, Yasumori K. Computed tomography of jugular foramen neurinomas – report of four cases. *Neurol Med Chir (Tokyo)*. 1987;27(7):628-32.
- Pollock BE, Kondziolka D, Flickinger JC, Maitz A, Lunsford LD. Preservation of cranial nerve function after radiosurgery for nonacoustic schwannomas. *Neurosurgery*. 1993;33(4):597-601.
- Aksik I. Microneural decompression operations in the treatment of some forms of cranial rhizopathy. *Acta Neurochir (Wien)*. 1993;125(1-4):64-74.
- Chang KC, Huang JS, Liu KN, Tsai CS, Chen TY. Neurinoma of the spinal accessory nerve: report of a case. *J Formos Med Assoc*. 1990;89(7):593-7.
- Christoferson LA, Leech RW, Grossman M. Intracranial neurilemoma of the spinal accessory nerve. *Surg Neurol*. 1982;18(1):18-20.
- Lesoin F, Destee A, Vaneecloo JF, Lozes G, Rousseaux M, Delandsheer JM, et al. [Radicular and truncal neurinoma of the spinal accessory nerve. 3 cases]. *Rev Otoneuroophthalmol*. 1984;56(4-5):455-61.
- Nishiura I, Koyama T. Neurinoma of the spinal accessory nerve. A case report. *Neurochirurgia (Stuttg)*. 1984;27(5):154-7.
- Tsuchiya K, Machida T, Maehara T, Iio M. [Case of accessory nerve neurinoma]. *Rinsho Hoshasen*. 1982;27(12):1375-8.
- Tsukamoto H, Hikita T, Takaki T. Cerebellopontine angle meningioma associated with cranial accessory nerve neurinoma – case report. *Neurol Med Chir (Tokyo)*. 1994;34(4):225-9.

Correspondence address

Roger Schmidt Brock
Rua Enéas Aguiar, 255, 5º andar, Pinheiros
05403-010 – São Paulo, SP, Brazil
E-mail: roger.brock@me.com