Adult-Onset Subgaleal Hematoma Caused by Hair Pulling: A Rare Occurrence

Sumit Bansal[1] Rabi Narayan Sahu[1] Ashis Patnaik[1]

[1]Department of Neurosurgery, All India Institute of Medical Sciences, Bhubaneswar, Orissa, India

Address for correspondence Sumit Bansal, MCh, Department of Neurosurgery, All India Institute of Medical Sciences, Bhubaneswar 751019, Orissa, India (e-mail: drsumitbansal@gmail.com).

Indian J Neurotrauma 2017;14:107–108

Subgaleal hematoma (SGH) is a potentially life-threatening extracranial hematoma and well-known condition in neonates especially after prolonged or instrumental delivery, but it has been rarely reported in childhood or beyond.[1] Its occurrence beyond the neonatal period is often associated with head trauma involving tangential or radial forces applied to the scalp (such as hair pulling), causing emissary veins traversing the subgaleal space to be ruptured.[1] The vast majority of SGHs are gradually absorbed. In cases exhibiting difficulties in absorption, puncture with aspiration or incision followed by drainage can achieve satisfactory outcomes.[2] In this article, the authors present a rare case of SGH after hair pulling in an adult male and aimed to describe its pathogenesis and management.

A 41-year-old man was admitted to the emergency department with progressive forehead scalp swelling and headache. There was no history of head trauma, but he recalled history of hair pulling while in a saloon 1 week ago. He realized forehead scalp swelling 1 day after hair pulling but ignored. On initial assessment, vital signs were stable and his Glasgow coma scale (GCS) was E4V5M6 = 15/15. Physical examination showed a tense and moderately tender scalp swelling in forehead region (►**Fig. 1a**). Neurologic evaluation was normal. His family history was not suggestive of coagulation disorders. There was no history suggestive of heart disease or intake of any medications such as aspirin or other antiplatelet agents. Complete blood count (hemoglobin, total leucocyte count, and platelet count) was normal. Coagulation parameters (prothrombin time and partial thromboplastin time) were in normal range. Computed tomography (CT) of the head showed bifrontal subgaleal heterogeneous fluid collection without skull fracture (►**Fig. 1b**). Aseptic percutaneous aspiration of scalp SGH was done with wide-bore needle and approximately 40-mL liquefied blood was aspirated. Pressure dressing was applied over scalp. He was discharged after 2 hours of observation, and paracetamol was prescribed for pain. On follow-up at 2 weeks, SGH was resolved completely.

The subgaleal space is located between the periosteum and epicranial galea, and comprises loose connective tissue; vessels connecting the scalp vein and skull diploe vein as well as the intracranial venous sinus are located within this space. Shearing or traction forces such as hair pulling lead to rupture of these veins, and this space is wide enough to store

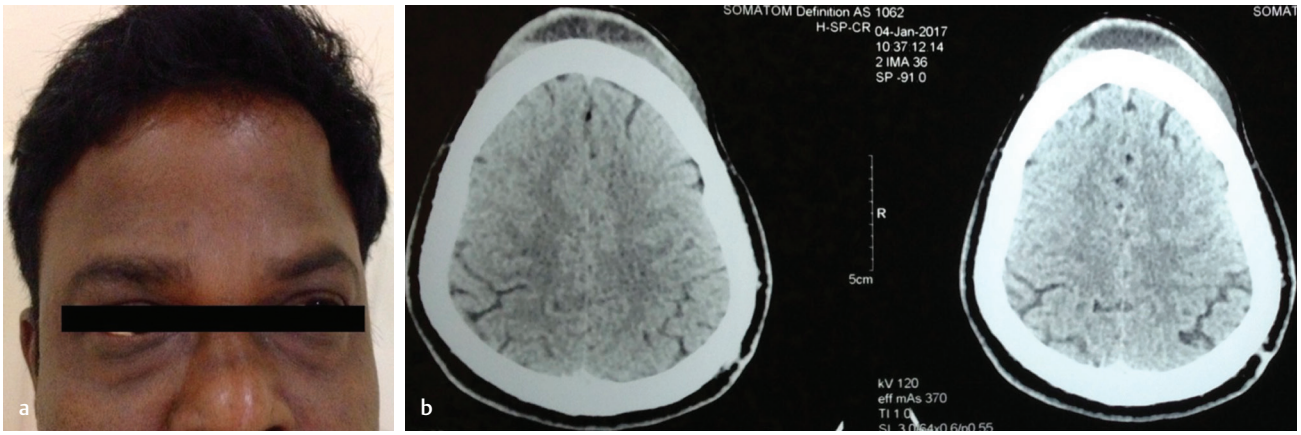

Fig. 1 A tense and moderately tender scalp swelling in forehead region (**a**). Computed tomography of the head showing bifrontal subgaleal heterogeneous fluid collection without skull fracture (**b**).

received
July 19, 2017
accepted
November 20, 2017

Copyright ©2017 Neurotrauma Society of India

DOI https://doi.org/10.1055/s-0037-1616031.
ISSN 0973-0508.

This document was downloaded for personal use only. Unauthorized distribution is strictly prohibited.

large amounts of blood, albeit limited with attachments of galea aponeurotica (orbital ridges, occipitofrontalis muscle, and zygomatic arches).[3]

At this stage, SGH manifests with a fluctuant scalp swelling crossing the suture lines and patients usually complaint of headache, emesis, drowsiness, or amnesia. Although it is a clinical diagnosis, CT is useful for patients with suspicion of abuse or traumatic brain injury. Nontraumatic SGH is very rare. The cause of nontraumatic SGH is sometimes associated with aneurysms of the superficial temporal artery (STA), scalp arteriovenous fistula (AVF), and coagulation disorders, such as von Willebrand's disease and factor XIII deficiency.[4] Therefore, one must be careful of history of easy bleeding or bruising and medications, such as aspirin. SGH usually resolves spontaneously. However, the blood in loose areolar tissue can pass beyond anatomic barriers of attachments and spread to the orbita, face, and neck with pressure and lead to proptosis, ophthalmoplegia, corneal ulceration, vision loss, facial edema, or airway compromise. There are various opinions concerning the treatment of SGH. Treatment with aspiration and compressive bandage or surgical drainage has been reported to shorten the period of blood resorption and decrease the risk of infection, calcification, and blood reaccumulation.[3] Beauchamp and Metcalf noted that hematoma aspiration was unnecessary unless severe pain, impending necrosis of the overlying scalp, or evidence of infection was present.[5] In this case, there was a large SGH causing severe pain and discomfort to the patient, so hematoma was aspirated and pressure bandage applied.

In conclusion, trivial trauma such as hair pulling can rarely lead to SGH in adults, and these patients should be evaluated thoroughly. Spontaneous resolution is usually observed, but hematoma aspiration is sometimes required for severe pain or to shorten the period of blood resorption as observed in this case.

Funding
None.

Conflict of Interest
None.

References

1 Vu TT, Guerrera MF, Hamburger EK, Klein BL. Subgaleal hematoma from hair braiding: case report and literature review. Pediatr Emerg Care 2004;20(12):821–823
2 Strowitzki M, Eymann R, Schleifer J, Steudel WI. Vertex epidural hematoma with communicating bifrontal subgaleal hematomas treated by percutaneous needle aspiration. Pediatr Neurosurg 2001;35(1):1–4
3 Fujisawa H, Yonaha H, Oka Y, et al. A marked exophthalmos and corneal ulceration caused by delayed massive expansion of a subgaleal hematoma. Childs Nerv Syst 2005;21(6):489–492
4 Raffini L, Tsarouhas N. Subgaleal hematoma from hair braiding leads to the diagnosis of von Willebrand disease. Pediatr Emerg Care 2004;20(5):316–318
5 Beauchamp CJ, Metcalf MB. Subgaleal hemorrhage. Pediatrics 1983;72(6):912–913

This document was downloaded for personal use only. Unauthorized distribution is strictly prohibited.