Periosteal Graft Myringoplasty: Our Experience

Mostafa ElTaher[1] Yosry Othman[2] Ibrahim Mohammed[1] Khaled Ali[1]

[1] Department of Otorhinolaryngology, Faculty of Medicine, Sohag University, Sohag, Egypt
[2] Department of ENT, Faculty of Medicine, Al-Azhar University, Assiut, Egypt

Address for correspondence Mostafa ElTaher, MD, Department of Otorhinolaryngology, Faculty of Medicine, Sohag University, Sohag 82524, Egypt (e-mail: mostafaent@yahoo.com).

Int Arch Otorhinolaryngol 2018;22:374–377.

Abstract

Introduction Different types of autologous graft materials are used for myringoplasty, with the temporalis fascia and cartilage being the most frequently used tissues. Periosteal tissue has been used for a long time in our department, and many advantages support its use in myringoplasty. To the best of our knowledge, this issue is scarcely discussed in the previously published literature.

Objective To present our experience with periosteal graft myringoplasty, describing the technique and the anatomical and functional outcomes.

Methods A prospective clinical study involving 88 patients (72 females and 16 males) with a mean age 26.9 years. The patients underwent myringoplasty using the mastoid cortex periosteum; they were all operated using the postauricular approach, and the graft was applied using the underlay technique. The patients performed pre- and postoperative pure tone audiometry for tested frequencies (0.5 kHz, 1 kHz, 2 kHz, and 4 kHz). All patients were followed-up for at least 12 months after the operation.

Results The anatomical success rate among all patients was of 93%, which is comparable to the rate of success in procedures using other usual grafting materials. In addition, there was a highly significant postoperative improvement in pure tone audiometry results as compared with the preoperative ones (the main hearing gain was of $\sim$ 11 dB; $p < 0.001$).

Conclusion The periosteal graft is easily harvested, easy to apply, with excellent anatomical and functional success.

Keywords
- myringoplasty
- audiometry
- periosteum

Introduction

In 1878, Emil Berthold[1] was the first author to describe a surgical procedure to graft a perforated eardrum using a free skin graft from the forearm. Since the introduction of modern tympanoplasty techniques by Wullstein[2] and Zöllner,[3] various grafting materials such as veins, the fascia, the perichondrium, and the periosteum were used to reconstruct the tympanic membrane[4]

To date, the temporalis fascia is the preferred material used in myringoplasty;[5] however, over the last decades there has been an increase in the use of cartilage due to its stiffness and resistance to necrosis.[6]

The periosteum was mentioned in the literature as a suitable material to repair perforated ear drums.[7] To our knowledge, very little is available in the literature about the technique and the outcome of the surgery regarding periosteal graft myringoplasty.

In this study, we present our experience using the mastoid periosteum to graft the tympanic membrane, specially as we find this technique rapid and time-saving, and it provides a greater chance for the surgeon to choose the graft material.

received
August 26, 2017
accepted
October 10, 2017
published online
February 16, 2018

DOI https://doi.org/10.1055/s-0037-1613716.
ISSN 1809-9777.

Copyright © 2018 by Thieme Revinter Publicações Ltda, Rio de Janeiro, Brazil

License terms

Methods

This is a prospective, non-controlled, non-randomized study that was conducted in a tertiary referral center between 2014 and 2016. The approval of the institutional ethical committee was obtained, and written informed consent forms were signed by each participant or by their guardians. The study included 88 patients for whom periosteal graft myringoplasty (PGM) was performed. Patient data on perforation size, side and location, gender, age, and audiological test results were recorded, and the clinical and audiometric follow-ups continued for one year after the operation.

All cases of tubotympanic chronic suppurative otitis media (CSOM) presenting with dry perforation, normal middle ear mucosa and no history of aural discharge for at least three months at the time of the procedure were included, while we excluded cases with associated ossicular affection or tympanosclerosis, mixed hearing loss, previous failed myringoplasty, and patients who had combined myringoplasty and cortical mastoidectomy.

All cases with mixed hearing loss were excluded, as some patients with sensorineural hearing loss may be sensitive to surgical manipulation, and this may affect the postoperative assessment. We excluded those cases in order to assess more easily the functional restoration of the hearing and patient satisfaction after the operation.

Audiological tests: we used the difference between pure tone average for air conduction and for bone conduction (pure tone average - air-bone gap [PTA-ABG]) in the frequencies of 0.5 kHz, 1 kHz, 2 kHz, and 4 kHz, and compared the preoperative results with the follow-up results after one year.

Surgical technique: All procedures are performed under general anesthesia by senior ear, nose and throat (ENT) surgeons (the authors), with the patients positioned on their back, and with a head ring placed below the head, which is rotated away from the surgeon, and the operated ear being superior. After preparing, sterilizing and draping the ear to be operated, the postauricular region and posterior canal wall are infiltrated using a mixture of 2% lidocaine with 1:100,000 adrenaline. An operative microscope (Carl Zeiss Meditec AG, Germany) is used to examine the perforation, and a needle (KarlStorz, Germany) is used to refresh its margins. Then, the surgeon performs the postauricular incision and dissects the postauricular muscles and aponeurotic tissue in the conventional manner until the periosteum over the mastoid cortex is exposed. A no. 15 scalpel blade (Swann-Morton, England) is used to cut a rectangle off the periosteum over the mastoid cortex just behind the ear meatus (according to the size of the perforation, ►**Fig. 1**). The tympanomeatal flap is then dissected, and the ossicles are tested for mobility and to see if they are intact. The graft is applied using the underlay technique; then, the meatal flap is placed back, and small pieces of Gelfoam (Pfizer, NY, USA) are introduced through the meatus to stabilize the graft at the edges of the perforation. Finally, the postauricular incision is sutured, and a piece of vaselinized gauze impregnated with oxytetracycline ointment is applied through the external canal. No difficulties were reported during the surgeries, and all steps were performed easily.

Statistics: Data were expressed as means ± standard deviation (SD). The paired Student *t*-test was used to analyze the differences between preoperative and postoperative PTA-ABG averages, and the level of statistical significance was set as $p < 0.05$. The analysis of the data was performed using the Statistical Package for the Social Sciences (SPSS, SPSS Inc., Chicago, IL, US) software, version 18.0.

Results

The study population included 72 females (81.81%) and 16 males (18.18%); the ages of the patients at the time of the myringoplasty ranged from 10 years to 49 years, with a mean of 26.93 years. Out of the 88 patients of the study population,

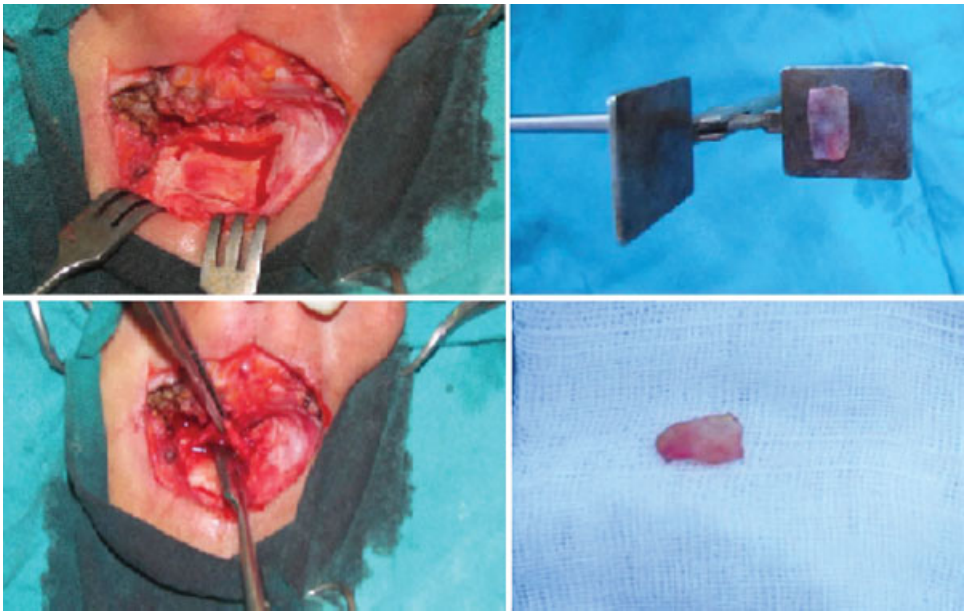

Fig. 1 Harvesting and preparation of the graft.

Table 1 Preoperative and postoperative PTA-ABG averages

	Mean ± SD	*p*
Preoperative PTA-ABG average	17.87 ± 4.56	
Postoperative PTA-ABG average	6.56 ± 4.42	
Difference between preoperative and postoperative results	11.30 ± 4.48	$p < 0.001$

Abbreviations: ABG, air-bone gab; PTA, pure tone average; SD, standard deviation.

44 (50%) had bilateral tubotympanic CSOM, while 44 (50%) patients had unilateral tubotympanic otitis media. Among the patients with unilateral perforations, 40 had normal tympanic membranes in their other ear, while 4 patients had conductive hearing loss due to adhesive otitis media.

Regarding the symptoms, 82 patients (90.90%) reported recurrent otorrhea, 72 patients (81.81%) reported a decrease in hearing in their affected ear, and 6 patients (6.81%) reported tinnitus. In total, 26 of the operated perforations were on the right side (29.54%), and 62, on the left side (70.45%). The 88 ear drums were grafted using the postauricular periosteum.

After follow-up for a period of 12 months, we found that anatomical restoration of the eardrum was achieved in 82 out of 88 patients (93% of the cases). Anatomical failure was observed in six cases: two of them had previous bilateral CSOM, and two had an adhesive contralateral ear.

The functional outcome was calculated only for the 82 patients with anatomical success of their myringoplasties. Hearing improvement was observed by comparing the mean preoperative PTA-ABG (mean: 17.87 dB; SD: 4.56) and the mean postoperative PTA-ABG performed after 1 year (mean: 6.56; SD: 4.52, ►**Table 1**) The difference between the preoperative and postoperative PTA-ABG averages was of 11.30 (p-value < 0.001, ►**Fig. 2**).

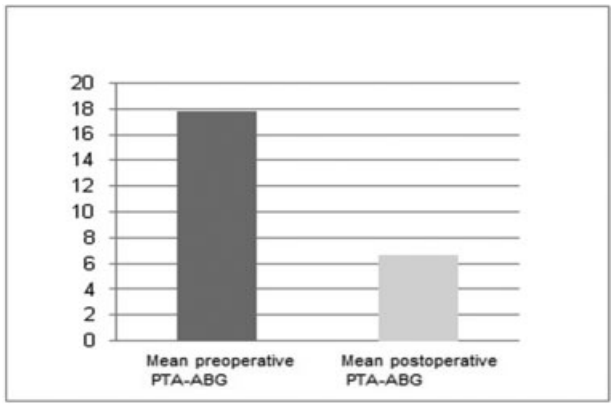

Fig. 2 Mean preoperative PTA and mean postoperative PTA-ABG averages ($p < 0.001$). Abbreviations: ABG, air-bone gap; PTA, pure tone average.

Discussion

Different tissue materials have been used as autologous grafts to repair a perforated eardrum. The temporalis fascia, which is the most famous tissue material used as a graft, achieves a success rate of ~ 93% to 97% in primary myringoplasty.[7] Cartilage grafts showed an increase in use in the last few years; due to its stiffness and strength, cartilage is thought to provide better stability and resistance to breakdown. On the other hand, some authors argue that these characteristics of cartilage may adversely affect sound conduction.[8,9]

In 1964, Chiossone, in his article entitled "Periosteal Grafting in Tympanoplasty," mentioned multiple advantages of periosteal grafts: their structural similarity with the middle fibrous layer of the tympanic membrane makes them adhere firmly to the handle of the malleus and the periosteum of the external canal; the periosteum usually receives poor nutrition, and it can resist well the first few days after transplantation; and periosteal consistency and elasticity make the periosteal grafts easy to manage. Moreover, a sufficient amount can be easily harvested, which is an extra advantage.[10]

Although the periosteal tissue provides all these advantages, very little is published in the literature regarding periosteal graft myringoplasty. In a conference presentation of our work, it was claimed during the discussion that this graft was abandoned because ossification of the periosteal graft was reported, but no evidence for that is found in the literature or in our work.[11]

This study included a higher percentage of female patients compared with males; this is related to social traditions in our country, as females are more interested in solving any medical issues before marriage.

In this study describing periosteal graft myringoplasty, a graft take rate of 93% was achieved. This rate is comparable with the success rate for cartilage grafts (~ 92%) and temporalis fascia grafts (~ 93-97%).[5,6] The failures that occurred in 6 (7%) of our patients may be related to upper respiratory tract infection in the early postoperative period, smoking, or difficulties during surgery.

In this work we found a mean improvement in hearing of ~ 11 dB, as proved by comparing the mean preoperative and postoperative PTAs for air conduction. Again, these functional results are comparable with the results reported for other graft materials.[8]

It is worthy of note that we do not use the periosteum when concurrent cortical mastoidectomy is planned; in this case, we preserve the periosteum to reconstruct the lateral wall of the mastoid to avoid postauricular dipping.

The absence of a control group may be a weak point of this study, but we report our results regarding anatomical and functional restoration in comparison to the literature data for other grafts.

Conclusion

The mastoid cortex periosteum is structurally suitable to repair the tympanic membrane. The periosteal graft is easily harvested through a postauricular approach; the graft is easy

to apply due to its strength and elasticity, and it results in excellent anatomical and functional outcomes that are comparable to fascia and cartilage grafts.

References

1 Berthold E. Ueber myring oplastik. Wien Med Blätter 1878; 26:627–639
2 Wullstein H. Funktionelle Operationen im Mittelohr mit Hilfe des freien Spaltlappen-Transplantates. Arch Ohren Nasen Kehlkopfheilkd 1952;161(2–6):422–435
3 Zöllner F. The principles of plastic surgery of the sound-conducting apparatus. J Laryngol Otol 1955;69(10):637–652
4 Sheehy JL, Anderson RG. Myringoplasty. A review of 472 cases. Ann Otol Rhinol Laryngol 1980;89(4 Pt 1):331–334
5 Lee JC, Lee SR, Nam JK, Lee TH, Kwon JK. Comparison of different grafting techniques in type I tympanoplasty in cases of significant middle ear granulation. Otol Neurotol 2012;33(04):586–590
6 Onal K, Arslanoglu S, Songu M, Demiray U, Demirpehlivan IA. Functional results of temporalis fascia versus cartilage tympanoplasty in patients with bilateral chronic otitis media. J Laryngol Otol 2012;126(01):22–25
7 Mancini F, Russo A, Sanna M. Grafting techniques for tympanoplasty. Oper Tech Otolaryngol–Head Neck Surg 1996;7:34–37
8 Freitas MR, Oliveira TC. The role of different types of grafts in tympanoplasty. Rev Bras Otorrinolaringol (Engl Ed) 2014;80(04): 275–276
9 Demirpehlivan IA, Onal K, Arslanoglu S, Songu M, Ciger E, Can N. Comparison of different tympanic membrane reconstruction techniques in type I tympanoplasty. Eur Arch Otorhinolaryngol 2011;268(03):471–474
10 Chiossone E. Periosteal Grafting in Tympanoplasty: A Preliminary Report. Arch Otolaryngol 1964;79:302–311
11 El-Taher M, Othman Y, Rizk I, Ali K. Periosteal graft myringoplasty: our experience, presented at the 88th Annual Meeting of the German Society of Oto-Rhino-Laryngology, Head and Neck Surgery. 24–27 may 2017, Erfurt. German Medical Science GMS Publishing House; 2017