

# Modified Pereira Suture as an Effective Option to Treat Postpartum Hemorrhage due to Uterine Atony

## *Sutura de Pereira modificada como uma opção eficaz para tratar a hemorragia causada por atonia uterina*

Maria Lúcia Moleiro<sup>1</sup> Luís Guedes-Martins<sup>1</sup> Alexandrina Mendes<sup>1</sup> Cláudia Marques<sup>1</sup> Jorge Braga<sup>1</sup>

<sup>1</sup> Centro Materno-Infantil do Norte, Centro Hospitalar Universitário do Porto, Porto, Portugal

Rev Bras Ginecol Obstet 2018;40:92–95.

Address for correspondence Maria Lúcia Moleiro, MD, Centro Materno-Infantil do Norte, Centro Hospitalar Universitário do Porto, Largo da Maternidade de Júlio Dinis, 4050-651 Porto, Portugal (e-mail: lucia.moleiro@gmail.com).

### Abstract

#### Keywords

- uterine atony
- pregnancy complications
- postpartum hemorrhage
- suture techniques

### Resumo

#### Palavras-chave

- atonia uterina
- complicações da gravidez
- hemorragia pós-parto
- técnicas de sutura

Nowadays, postpartum hemorrhage is the major cause of maternal mortality and morbidity worldwide. Uterine atony is its main cause; thus, prophylactic measures, as well as medical and surgical fast approaches, have been developed to manage it. The uterine compression sutures are a possible treatment that preserves the uterus and, consequently, the fertility potential. Bearing that in mind, we report two cases of postpartum hemorrhage after caesarean section, successfully treated with a new modification of Pereira suture — longitudinal and transverse uterine sutures were applied after no response was registered to the first-line therapies. Both women recovered, and the postpartum evaluation revealed a normal uterus with an adequate blood supply, suggesting potential fertility, as described in the literature regarding this kind of therapeutic approach.

Atualmente, a hemorragia pós-parto é a maior causa de morbimortalidade materna em todo o mundo. Sua principal causa é a atonia uterina, pelo que têm sido instituídas e desenvolvidas medidas profiláticas, bem como tratamentos médicos e cirúrgicos para esta complicação. As suturas uterinas de compressão representam uma possibilidade terapêutica que permite a preservação do útero e, por conseguinte, do potencial fértil. Tendo isso por base, apresentamos dois casos de hemorragia pós-parto após cesariana, que foram tratados com sucesso com uma nova modificação da sutura de Pereira — suturas uterinas longitudinais e transversais foram efetuadas após falha das terapias de primeira linha. Ambas as pacientes se recuperaram, e na reavaliação pós-parto objetivou-se um útero normal com manutenção de uma irrigação adequada, sugerindo a preservação do seu potencial fértil, tal como vem sendo descrito na literatura em relação a este tipo de procedimento.

## Introduction

Postpartum hemorrhage (PPH) is defined as a blood loss over 500 mL in the first 24 hours after birth, and it is considered severe when exceeding 1,000 mL.<sup>1</sup> Postpartum hemorrhage persists as the main cause of maternal morbidity and mortality, with uterine atony being the leading trigger.<sup>1</sup>

The management of uterine atony includes a range of measures, starting with prophylactic ones and first-line therapies with uterotonic drugs.<sup>2</sup> When they fail, uterine compression sutures may be a reasonable option.<sup>3</sup>

Since B-Lynch et al<sup>4</sup> successfully controlled PPH due to uterine atony with their suture technique, many modifications of it have been described. Pereira et al<sup>5</sup> used longitudinal and transverse sutures, differing from the previous ones, because they do not enter the uterine cavity.

We report two cases of PPH due to uterine atony successfully treated with the modified Pereira suture technique. Both women signed an informed consent agreeing with the publication of their medical information, surgical data and sonographic still images but keeping their identities anonymous.

## Case Description

### Case 1

A 45-year-old healthy woman, G2P0, allergic to penicillin, with a 41-week-long uneventful pregnancy achieved after fertility treatment with female donor gamete, was admitted for induction of labor. Due to maternal prolonged membrane rupture and fever, a caesarean section was performed. After fetal delivery and uterine repair, uterine atony suddenly occurred. Medical treatment was attempted with intravenous oxytocin (10 IU/500 mL of saline solution, 125 mL/h), sulprostone (1,000 µg/500 mL of saline solution, 125 mL/h) and 800 µg of rectal misoprostol, while uterine massage was executed. As these measures were unsuccessful, a modified uterine Pereira suture was performed using delayed, absorbable suture thread with effective control of the hemorrhage (►Fig. 1A).

After the surgery, given that the patient's hemoglobin value was 7.9 g/dL (previous value of 12.8 g/dL), an intravenous iron

sucrose infusion was needed. She successfully recovered and was discharged 7 days postpartum. At the post-op appointment, nearly 7 weeks postpartum, the patient had fully recovered, and the transvaginal sonography revealed a normal uterus (►Fig. 2A–D) with normal uterine arteries impedance.<sup>6,7</sup>

### Case 2

A 31-year-old healthy woman, with a 41-week-long spontaneous and uneventful pregnancy, was admitted for elective caesarean section due to a previous one. The surgical procedure was uneventful. Still in the operating room, a bolus of 5 IU intravenous oxytocin and 800 µg of rectal misoprostol was administered, with no abnormal hematic loss identified.

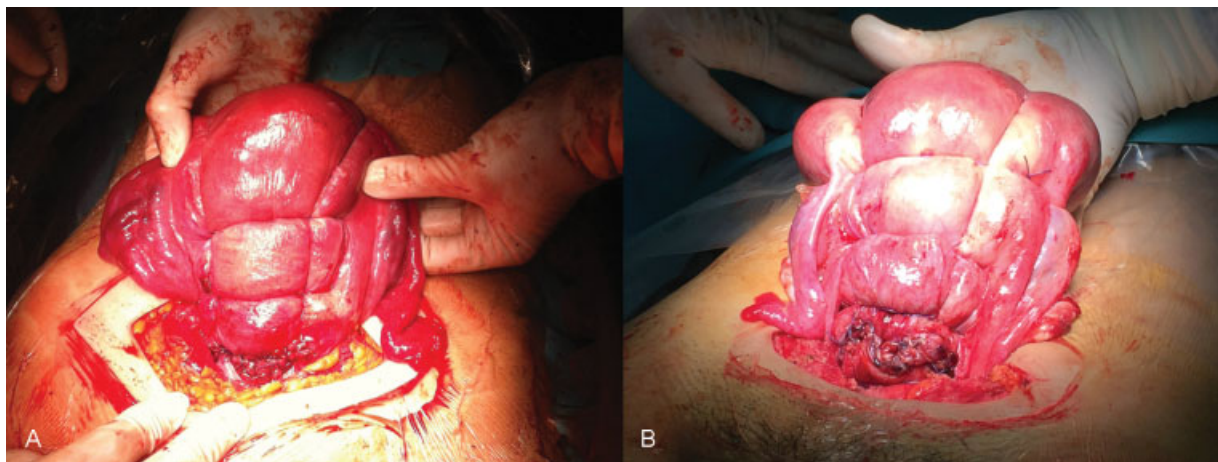
A few hours later, the emergency team was called due to active vaginal hemorrhage. Manual uterine massage and pharmacological measures (oxytocin – 10 IU/500 mL of saline solution, 125 mL/h – and sulprostone – 1,000 µg/500 mL of saline solution, 125 mL/h) were attempted with no success. An exploratory laparotomy was performed and other causes of postpartum hemorrhage besides uterine atony were excluded. It was decided to perform a modified uterine Pereira suture using delayed, absorbable suture thread with effective control of the hemorrhage (►Fig. 1B).

After the surgery, the patient was transfused two units of red blood cells given that the postoperative hemoglobin value was 7.1 g/dL (previous value of 13.1 g/dL). No other events were registered, and the patient was discharged 4 days postpartum.

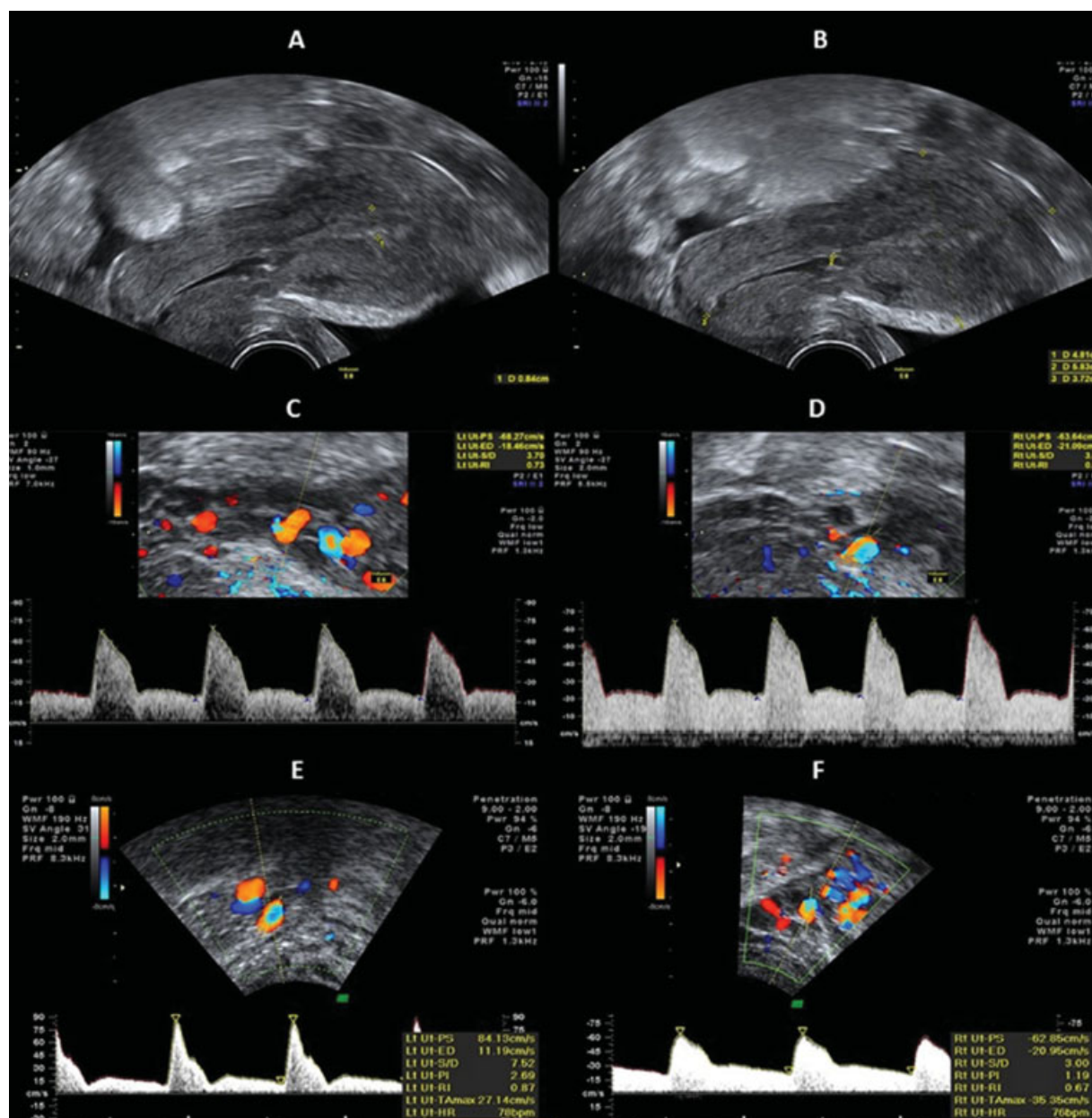
At the post-op appointment, 7 weeks postpartum, the patient had fully recovered. A transvaginal sonography was performed revealing an anteverted, normal uterus with normal uterine arteries impedance (►Fig. 2, E + F), suggesting adequate myometrial blood supply.<sup>6,7</sup>

## Discussion

Postpartum hemorrhage is an obstetric emergency that can lead to emergency hysterectomy in patients with treatment-resistant, life-threatening bleeding.<sup>8</sup> Uterine atony is the most common cause of PPH, but retained placenta, coagulation abnormalities and genital tract trauma must be considered.<sup>1,3</sup>



**Fig. 1** Postpartum aspect of the modified Pereira suture (A: case 1. B: case 2).



**Fig. 2** Transvaginal sonography and uterine arterial (Uta) waveforms at 7-weeks post-partum. Normal sagittal sonogram of the uterus, physiologically anteverted and anteflexed. (A + B: case 1). Spectral analysis of blood flow velocity waveforms obtained from the Uta (right and left) revealed a normal pattern (C + D: case 1. E + F: case 2); (Guedes-Martins et al, 2015).<sup>6,7</sup>

After first-line treatment failure, many procedures have been developed, including uterine balloon tamponade, uterine packing, uterine artery embolization, uterine and other pelvic artery ligation and uterine compression sutures.<sup>2,3,9</sup> Uterine compression sutures are a relatively simple option to avoid an emergency hysterectomy, with associated morbidity, and to preserve fertility.<sup>2,3,8,9</sup>

The suture performed was a combination of the B-Lynch and the Alcides Pereira techniques. A blunt, 70 mm semi-circular needle, mounted with a Vicryl 1 (polyglactin 910) absorbable suture, was used to puncture the uterus 2–3 cm from the right lower edge of the uterine incision and 2–3 cm from the right lateral border. The suture was

threaded through the uterine cavity to emerge at the upper incision margin, located 2–3 cm above and 3–4 cm from the lateral border. Subsequently, the surgical thread was passed over to compress the uterine fundus 3–4 cm from the right cornual border and pulled under moderate tension, assisted by manual compression. The length of the suture was passed back posteriorly through the same surface marking as on the right side, the suture lying horizontally. Additionally, the suture was fed through posteriorly and vertically over the fundus to lie anteriorly and vertically compressing the fundus on the left side, as occurred on the right. The needle was passed in the same fashion on the left side through the uterine cavity and out

2–3 cm anteriorly and below the lower incision margin on the left side being then finished with a tight knot. After that, a series of transverse circular sutures of multifilament absorbable Vicryl 1 were placed around the uterus. The placement of the sutures involved a series of bites inserted superficially, taking only the serous membrane without penetrating the uterine cavity, to anchor and tighten the longitudinal sutures (described above). Three or four transverse circular sutures were placed, starting in the anterior wall of the uterus, crossing the broad ligament toward the posterior aspect of the uterus, then crossing the opposite broad ligament toward the anterior aspect and tying the suture over the anterior aspect of the uterus. When the suture crossed the broad ligament, we selected an avascular area to ensure that the fallopian tube, the utero-ovarian ligament, and the round ligament were not inside the suture. The last transverse circular suture was placed in the lower uterine segment.

Lynch et al first described a uterine suture technique in which longitudinal sutures were performed to control PPH due to uterine atony and, since then, several modifications have been developed. Hayman et al<sup>10</sup> used not only longitudinal uterine sutures, but also transverse isthmic-cervical compression sutures to treat PPH due to uterine atony or placenta previa.<sup>4</sup> Pereira et al<sup>5</sup> presented another longitudinal uterine suture technique. Different from the others, the Pereira suture only bites the serous membrane and the subserous myometrium, without penetrating the uterine cavity. So, it can be performed when there is no hysterotomy or when the uterus is already closed, as happened in our case 2.<sup>5</sup>

The suture technique used in the patients presented was a new modification of the previously described by Pereira et al,<sup>5</sup> and it proved to be successful in controlling postpartum hemorrhage due to uterine atony. Nevertheless, there are no randomized control trials evaluating the efficacy of different uterine sutures, since they are second- or even third-line therapies in hemodynamically unstable patients.<sup>9</sup> The literature review, so far, advises clinicians to make individual decisions regarding each clinical situation.<sup>9</sup>

The fertility outcomes in women who underwent uterine compression suture to treat PPH are optimistic, suggesting that there are no differences to other healthy women.<sup>9</sup> Both cases presented revealed no abnormalities on postpartum uterine exam, namely on uterine artery impedance, supporting future fertility potential.

## Conclusion

In conclusion, in these two cases, the uterine compression sutures were an adequate option to successfully treat PPH due to uterine atony while preserving fertility.

### Conflicts to Interest

The authors declare that there is no conflict of interest.

### Acknowledgments

We would like to thank all the emergency staff who worked on these cases, contributing for their successful treatment, namely Doctor Susana Marta. L.G-M., who performed both modified Pereira's sutures.

## References

- 1 World Health Organization. *WHO Recommendations for the Prevention and Treatment of Postpartum Haemorrhage*. Geneva: WHO; 2012
- 2 Weeks A. The prevention and treatment of postpartum haemorrhage: what do we know, and where do we go to next? *BJOG* 2015; 122(02):202–210. Doi: 10.1111/1471-0528.13098
- 3 Abdul-Kadir R, McLintock C, Ducloy AS, et al. Evaluation and management of postpartum hemorrhage: consensus from an international expert panel. *Transfusion* 2014;54(07):1756–1768. Doi: 10.1111/trf.12550
- 4 B-Lynch C, Coker A, Lawal AH, Abu J, Cowen MJ. The B-Lynch surgical technique for the control of massive postpartum haemorrhage: an alternative to hysterectomy? Five cases reported. *Br J Obstet Gynaecol* 1997;104(03):372–375. Doi: 10.1111/j.1471-0528.1997.tb11471.x
- 5 Pereira A, Nunes F, Pedroso S, Saraiva J, Retto H, Meirinho M. Compressive uterine sutures to treat postpartum bleeding secondary to uterine atony. *Obstet Gynecol* 2005;106(03):569–572. Doi: 10.1097/01.AOG.0000168434.28222.d3
- 6 Guedes-Martins L, Gaio AR, Saraiva J, Cunha A, Macedo F, Almeida H. Uterine artery impedance during the first eight postpartum weeks. *Sci Rep* 2015;5:8786. Doi: 10.1038/srep08786
- 7 Guedes-Martins L, Saraiva J, Felgueiras Ó, et al. Uterine artery impedance during puerperium in normotensive and chronic hypertensive pregnant women. *Arch Gynecol Obstet* 2015;291(06):1237–1246. Doi: 10.1007/s00404-014-3560-6
- 8 Kayem G, Kurinczuk JJ, Alfirevic Z, Spark P, Brocklehurst P, Knight M; U.K. Obstetric Surveillance System (UKOSS) Uterine compression sutures for the management of severe postpartum hemorrhage. *Obstet Gynecol* 2011;117(01):14–20. Doi: 10.1097/AOG.0b013e318202c596
- 9 Sathe NA, Likis FE, Young JL, Morgans A, Carlson-Bremer D, Andrews J. Procedures and uterine-sparing surgeries for managing postpartum hemorrhage: a systematic review. *Obstet Gynecol Surv* 2016; 71(02):99–113. Doi: 10.1097/OGX.0000000000000273
- 10 Hayman RG, Arulkumaran S, Steer PJ. Uterine compression sutures: surgical management of postpartum hemorrhage. *Obstet Gynecol* 2002;99(03):502–506