Case Report

Postelectrocution Massive Brain Infarcts

Kaiser Kareem[1] Khursheed Nayil[1] Zulfikar Ali[2] Bashir Dar[2] Altaf Ramzan[1]

[1]Department of Neurosurgery, Sheri-Kashmir- Institute of Medical Sciences, Kashmir, Jammu and Kashmir, India
[2]Department of Anesthesiology, Sheri-Kashmir- Institute of Medical Sciences, Kashmir, Jammu and Kashmir, India

Address for correspondence: Khursheed Nayil, MS, MCh, Department of , Neurosurgery, Office- First Floor 1312, SKIMS, Kashmir, 190011, Jammu and Kashmir, India (e-mail: nayilkhursh@gmail.com).

Indian J Neurotrauma 2018;15:39–40

Abstract

Acute brain infarct is an uncommon complication of electrical injury, and only a few cases have been reported. A young man sustained a high-voltage electrical injury followed by a fall from height. Imaging revealed right hemibrain infarct. He was operated for that, but did not make much progress. Electric shock injury with the high-voltage current even for short period of contact may cause massive infarction of brain, and prognosis remains dismal.

Keywords
- electrical injury
- infarction
- vasospasm
- thrombosis

Introduction

Electrical injuries are relatively common in daily life and they are incurred accidentally. The severity of electrical injury varies depending on magnitude of energy delivered, type of current, current pathway, and duration of contact. Different body systems react differently, and some are especially vulnerable to injuries such as the heart, kidneys, muscles, skin, and vascular and nervous systems. Acute brain infarct is a rare complication. Here, we describe the case of a young man who suffered brain infarction after accidental electrical injury.[1,2]

Case Report

A 20-year-old man sustained a high-voltage electric shock while he was on work. Post electrocution, he had a fall from a height of 15 meters. He had loss of consciousness with right ear bleed and third-degree burn over the right forearm. On arrival to hospital, he had Glasgow coma scale (GCS) of $E_1V_1M_1$. Bilateral pupils were fixed and dilated. He was intubated and ventilated. Computed tomography (CT) of the brain showed malignant brain infarct with mass effect (►**Fig. 1A, B**). *Because of technical reasons, a Doppler study of the neck vessels could not be done*. A right frontotemporoparietal decompressive craniotomy with autologous duraplasty using subgaleal patch was done. His postoperative neurologic examination of sedation was E_1 V_t M_1. Postoperative CT scan showed well-developed infarct on right side and fresh infarct on the left anterior cerebral artery territory (►**Fig. 2**). At the time of discharge, the patient's GCS was $E_1V_1M_2$. At 3 months follow-up time, the patient continues to have same neurologic status and has not made any further neurologic recovery.

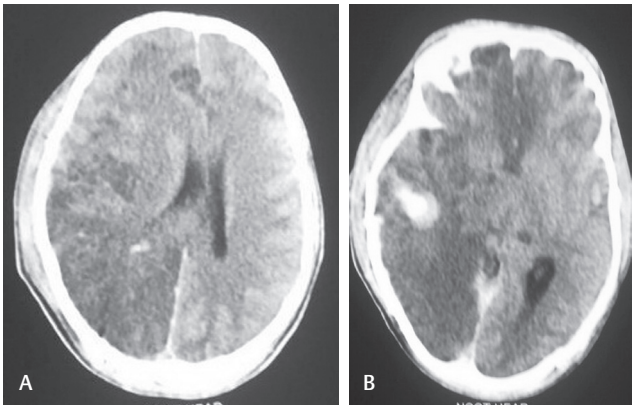

Fig. 1 (**A, B**) Plain CT of the head showing right hemispheric infarct with mass effect and midline shift with speck of contusion. CT, computed tomography.

Discussion

The severity of electric injury is determined by voltage, amperage, type of current (alternating or direct), resistance of the body, path of electrical flow, and duration of contact—type of current and voltage being the most important factors.[1]

received
September 10, 2016
accepted
October 31, 2017
published online
August 17, 2018

DOI https://doi.org/10.1055/s-0037-1612646.
ISSN 0973-0508.

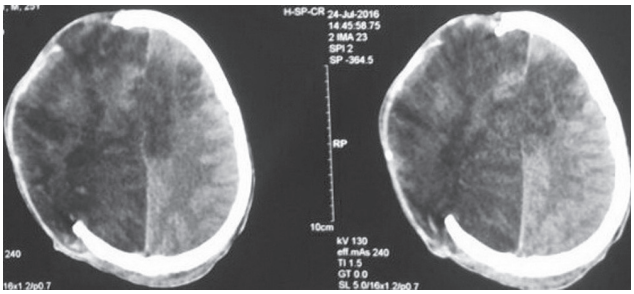

Fig. 2 Postoperative CT scan of head showing well-developed infarct on right side and fresh infarct on left anterior cerebral artery territory. CT, computed tomography.

The resistance of body tissue to current varies between the bone, fat, ligaments, skin, muscles, vessels, and nerves. High-voltage current passes through the body across the shortest distance regardless of tissue type, and it may cause massive soft tissue injury and extensive skin necrosis at the contact site.[1,2]

Cerebral infarction is rarely reported, although the infarction of watershed areas vulnerable to ischemia may result from cardiopulmonary arrest. Cerebral infarctions without hemodynamic alterations have been reported following electric injury, but the underlying mechanisms are poorly understood.[3–5] Two cases reported of cerebral infarction from a direct electrical injury exhibited wedge-shaped infarctions of the frontotemporal and parietal lobes, respectively. These were probably caused by territorial occlusion due to vasospasm or embolism formation.[3,4] In our patient, the ischemic stroke occurred in the right middle cerebral artery (MCA) territory, and it is possible that vascular endothelial damage and thrombus formation occluded it.[5]

Janus and Barrash reported cases of 10 individuals who suffered from lightning injury with neurologic complications, and only two of them had abnormal findings on cranial CT scans.[6] Thermal injury may be one of the mechanisms underlying cerebral damage.[5] The temperature of the cerebrospinal fluid may increase to as high as 145°F at 5 hours after electrocution. However, because the shortest current pathway did not pass through the brain in our patient, direct thermal injury is less likely to be the cause of ischemic stroke.

Acute stroke may result from vascular structural changes after electrical injury,[7] but acute infarctions or hemorrhage is not common after lightning accidents. Further, several cases of acute ischemic stroke after lightning showed watershed infarction due to hemodynamic alterations after cardiac arrest, but a wedge-shaped infarction lesion on magnetic resonance imaging (MRI) was noted in only one report on lightning-induced cerebral infarction.[3,8] In this case, the brain infarction in the right frontotemporoparietal region was probably caused by territory occlusion due to vasospasm or embolism formation in the MCA rather than systemic hypoperfusion and hypoxic encephalopathy.

In this case, the shortest current pathway was through the hands, arms, chest, and heart. Both vasospasm and endothelial injury may contribute to vascular narrowing. Animal studies of electrical convulsive therapy showed segmental spastic constriction of the pial arteries and arterioles in the brain parenchyma, and the pial arteries were found to directly constrict with electrical stimulation.[9,10] Usually, these vasospasms persisted even after the stimulation was discontinued. Vascular endothelial damage may be related to electrical nonthermal effect, in addition to thermal effects. Lee et al used electroporation to describe this nonthermal effect, which causes structural changes in cell membranes and tissue damage by denaturation of intracellular proteins or changes in cell-membrane permeability.[11]

Conclusion

Electric shock injury with high-voltage alternating currents and a prolonged contact period may cause ischemic stroke. Vasospasms/vessel thrombosis caused by the electrical injury may be the etiology of the stroke.

References

1 Wilkinson C, Wood M. High voltage electric injury. Am J Surg 1978;136(6):693–696
2 Hoover BB, Baxter CR, Kirkpatrick MR. Electromyographic findings in high voltage electrical burns: two cases. South Med J 1971;64(11):1392–1394
3 Cherington M, Yarnell P, Lammereste D. Lightning strikes: nature of neurological damage in patients evaluated in hospital emergency departments. Ann Emerg Med 1992;21(5):575–578
4 Huan-Jui Y, Chih-Yang L, Huei-Yu L, Po-Chih C. Acute ischemic stroke in low-voltage electrical injury: a case report. Surg Neurol Int 2010;1:83
5 Stanley LD, Suss RA. Intracerebral hematoma secondary to lightning stroke: case report and review of the literature. Neurosurgery 1985;16(5):686–688
6 Janus TJ, Barrash J. Neurologic and neurobehavioral effects of electric and lightning injuries. J Burn Care Rehabil 1996;17(5):409–415
7 Critchley M. Neurological effects of lightning and electricity. Lancet 1934;1:68–72
8 Cherington M. Neurologic manifestations of lightning strikes. Neurology 2003;60(2):182–185
9 Echlin FA. Vasospasm and focal cerebral ischemia. An experimental study. Arch Neurol Psychiatry 1942;47(1):77–95
10 Matakas F, Cervós-Navarro J, Roggendorf W, Christmann U, Sasaki S. Spastic constriction of cerebral vessels after electric convulsive treatment. Arch Psychiatr Nervenkr (1970) 1977;224(1):1–9
11 Lee RC, Aarsvold JN, Chen W, et al. Biophysical mechanisms of cell membrane damage in electrical shock. Semin Neurol 1995;15(4):367–374