

# Use of Intramedullary Cannulated Headless Screws in the Treatment of Hand Fractures - An Anatomical Study on Long Fingers

## *Utilización de los tornillos canulados sin cabeza intramedulares en el tratamiento de las fracturas de la mano - estudio anatomico en los dedos largos*

María Jesús Rivera Vegas<sup>1</sup> Miguel Eugenio Estefanía Díez<sup>1</sup> Pablo Martínez Núñez<sup>2</sup>  
Rebeca Astorga Veganzones<sup>2</sup>

<sup>1</sup>Medical Expert, Plastic, Aesthetic and Reconstructive Surgery Service, Hospital Universitario de Burgos, Burgos, Spain  
<sup>2</sup>Medical Resident, Plastic, Aesthetic and Reconstructive Surgery Service, Hospital Universitario de Burgos, Burgos, Spain

Address for correspondence María Jesús Rivera Vegas, Adjunto del Servicio de Cirugía plástica, Estética y Reparadora del Hospital Universitario de Burgos, Burgos, Spain  
(e-mail: riveravegas@gmail.com).

Rev Iberam Cir Mano 2017;45:94–103.

### Abstract

**Objective** To quantify the cartilaginous and tendinous lesions produced upon percutaneous introduction of intramedullary cannulated screws as osteosynthesis material in metacarpal and phalangeal fractures.

**Materials and Methods** Seven anatomical models and one non-replanted hand were used. The measurements of 30 metacarpals and proximal and middle phalanges were taken. Cannulated screws with complete and partial threads were placed percutaneously through the metacarpal head and the proximal and middle phalanges, reproducing the actions performed in the clinic. The following measurements were performed: A) Percentage of the damaged cartilaginous area and its location. B) Damage to the extensor apparatus and its distance to the bone insertion point. C) Bone marrow size.

**Results** (A) The percentages of the damaged areas in the metacarpals, proximal and middle phalanges were 5.7%, 13.35% and 9.62%, respectively. (B) The damage to the extensor apparatus was less than 3 mm with a 4-mm distance to the bone insertion point and (C) We have obtained the measurements of the intramedullary bone and from them, we calculated the width of the most appropriate screw.

**Conclusion** In conclusion, the use of retrograde and percutaneous cannulated screws is a reliable technique with regard to the associated morbidity, and we present an approximation regarding the most appropriate screw for each location.

### Keywords

- ▶ metacarpals
- ▶ phalanges
- ▶ osteosynthesis
- ▶ intramedullary screws

### Resumen

**Objetivo** El objetivo de este estudio es cuantificar las lesiones cartilaginosas y tendinosas que se producen al introducir tornillos canulados intramedulares percutáneos como material de osteosíntesis en fracturas de metacarpianos y falanges.

received  
July 12, 2017  
accepted  
September 25, 2017  
published online  
November 22, 2017

DOI <https://doi.org/10.1055/s-0037-1608789>.  
ISSN 1698-8396.

Copyright © 2017 Thieme Revinter  
Publicações Ltda, Rio de Janeiro, Brazil

License terms



**Materiales y Métodos** Utilizamos en nuestro estudio anatómico piezas anatómicas donadas (7 manos) y manos no reimplantadas en nuestro hospital (1mano). Se han medido 30 metacarpianos y falanges proximales y medias. Se colocan percutáneamente los tornillos canulados de espiras completas y parciales, a través de la cabeza de los metacarpianos y las falanges proximales y medias reproduciendo las acciones realizadas en la clínica. Realizamos las mediciones: A) Porcentaje del área cartilaginosa lesionada y su localización. B) Lesión en el aparato extensor y la distancia de esta a la inserción ósea. C) Tamaño de la medular de los huesos.

**Resaultados** Obteniendo los siguientes resultados: A) el porcentaje del área lesionada en los metacarpianos, falanges proximales y medias es de 5,7%,13,35% y 9,62% respectivamente. B) La lesión del aparato extensor es menor de 3mm con una distancia a las inserciones óseas de 4mm y C) Obtenemos medidas de las intramedulares óseas y las relacionamos con la anchura del tornillo más adecuado.

**Conclusión** Como conclusión, la utilización de tornillos canulados via retrograda y percutánea es una técnica fiable en cuanto a la morbilidad asociada y damos una aproximación al tornillo más adecuado en cada localización.

#### Palabras Clave

- ▶ metacarpianos
- ▶ falanges
- ▶ ostesíntesis
- ▶ tornillos intramedulares

## Introduction

Fractures of the metacarpals and phalanges are the second most common fractures of the upper limb, after fractures of the distal radius. Fractures can be treated conservatively or surgically depending on several criteria.<sup>1</sup>

Kirschner needles (K-needles), screws and osteosynthesis plates have been the usual methods of fixation.<sup>2-6</sup> These methods can lead to complications, depending, in a way, on the characteristics of the fracture, the patient, the surgical technique and the osteosynthesis material itself.<sup>7</sup>

The use of cannulated headless screws inserted in a retrograde manner is indicated in certain types of fractures of the metacarpals and phalanges, and present advantages in relation to the other types of osteosynthesis.<sup>8-13</sup> The screws are inserted percutaneously, allowing a stable fixation with minimally invasive surgery. These are inserted through a joint surface, and not having a head allows them to be buried in the subchondral bone, without interfering with the joint movement. The use of cannulated screws embedded in the medullary structure facilitates a sufficiently solid fixation to allow early mobilization by avoiding the rotation of the threads that are fixed in the medullary.

The objective of this study is to quantify the cartilaginous and tendinous lesions that occur when using intramedullary cannulated screws as osteosynthesis material in fractures of the metacarpals and phalanges. This involves obtaining a measurement of the intramedullary canal of the studied bones to make an approximation of the appropriate screw to be used.

## Material and Methods

### Anatomical Study / Bone Section

Our anatomical study was supported by the Centre for Body Donation and dissection rooms of the Anatomy Department of the Faculty of Medicine of the Complutense University of

Madrid, which provided seven anatomical pieces of formaldehyde-preserved cadavers (upper limbs), in addition to hands whose reimplantation had been rejected or failed, treated in our service (1 hand), in which we have studied the bones of the long fingers, excluding the thumb.

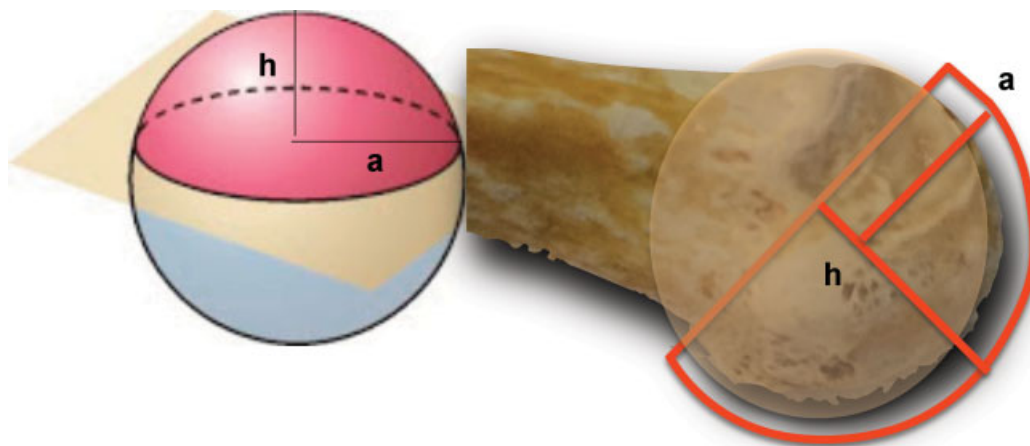
Two types of screws were used, one with a conical structure and threads along the entire length, Acutrak (Acumed, Hillsboro, Oregon USA), and the other type is a Herbert screw, the AutoFix (Cannulated Compression Screw; Tarma Group, Madrid, Spain) in several head and thread sizes (▶ **Table 1**).

The placement of the screws was transcuteaneous. A maximum flexion of the metacarpophalangeal joint in the metacarpals, and of the proximal and distal interphalangeal joints was required for placement in the proximal and middle phalanges without dissection of the soft tissues, which are the same actions that would be performed in a clinic. The bone measurements presented in this paper were performed on these hands.

To carry out the measurements, we used a Borletti digital caliper, model CDEP15, with an accuracy of 0.01 mm (LFT SpA, Antegnate, BG, Italy).

**Table 1** Screws used in our study and their measures

Screw type	Width in threading type	Width in point type
Cannulated turns complete	4.1 mm	4.0 mm
Cannulated turns complete	3.6 mm	3.5 mm
Cannulated turns complete	2.8 mm	2.5 mm
Cannulated turns partial (type Herbert)	3.7 mm	3.0 mm
Cannulated turns partial (type Herbert)	2.8 mm	2.2 mm



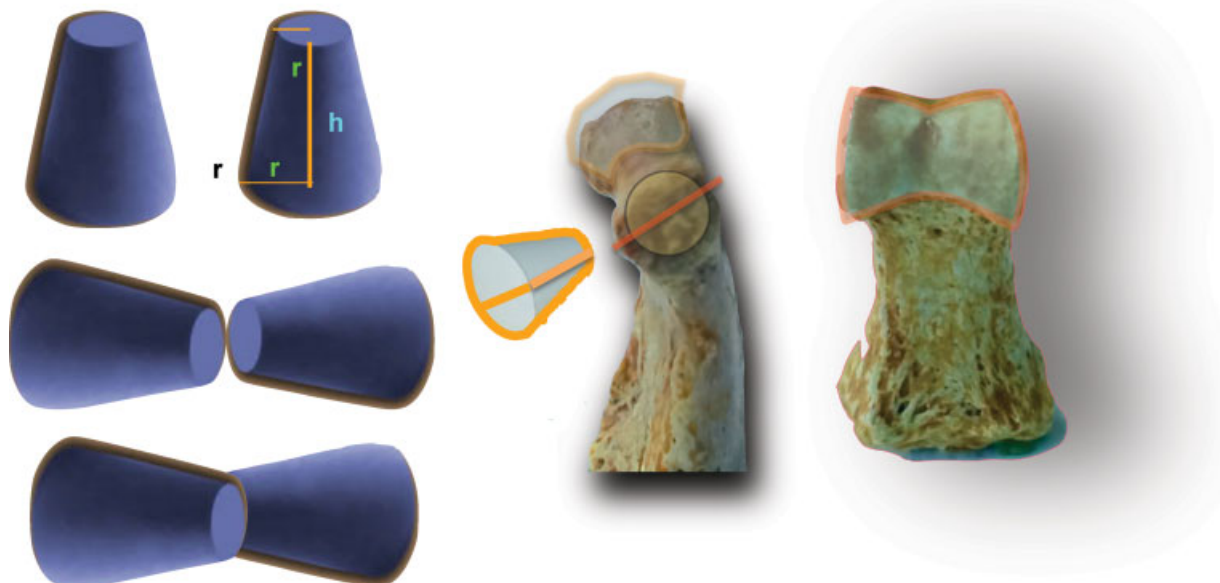
**Fig. 1** The geometric image of the spherical cap and the articular surface of the metacarpal head.

We measured 30 metacarpals, proximal and middle phalanges of the long fingers, in which the following variables were studied:

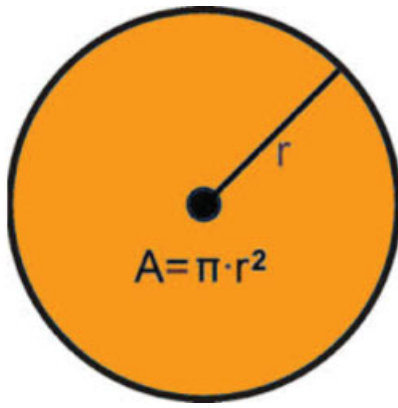
- Area of the metacarpal head  
The area of the metacarpal head is approximated to the geometric spherical cap figure. A spherical cap is the part of a sphere cut by a plane (→Fig. 1). The formula of the area of the cap is  $\pi(a^2 + h^2)$ , with “a” being the radius of the base of the cap, and “h,” the height of the cap.
- Area of the head of the proximal and middle phalanges  
To find the area of the head of the proximal and middle phalanges, we approximated their shape to two truncated cones joined by their smaller base. The area of the truncated cone is determined by the radius of the bases,  $r_1$  and  $r_2$ , the height “h” and the generatrix “s” and is obtained by the formula  $\pi(r_1 + r_2) S$ . The results

obtained are divided in half to approximate the geometric structure to the figure of the phalangeal head (→Fig. 2).

- Measurement of the lesion area caused by the entry of the cannulated screws through the metacarpal head and the proximal and middle phalanges.  
The lesion resulting from the entry of the cannulated screws into the cartilage will be equal to the circle area of the cannulated screw head, whose formula is  $\pi \times r^2$ . Even though the screw structures may be different, what should be taken into account is the width of the screw head (→Fig. 3).
- Relationship between the head of the bones studied, and the cartilaginous lesion caused by the introduction of the cannulated screws.
- It is determined by the percentage of injured area at the head of the studied bones caused by the entry of the screws.



**Fig. 2** Two truncated cones joined at their narrow portion and their association with the phalangeal heads.



**Fig. 3** Geometric image of the cannulated screw insertion associated with a circle.

- Localization of the entry of the cannulated screws into the metacarpal head and into the proximal and middle phalangeal heads.
- Measurement of the medullary size and the relationship between the outer and inner (medullary) widths of the metacarpals.  
The external and medullary widths of the metacarpals are measured in order to obtain the proportion between them.
- Relationship between the medullary cavities of the metacarpals and phalanges and the size of the screws.  
The relationship between the medullary cavities of the bones studied and the width of the screws helps to indicate the proper screw for each bone.

**Anatomical Study/Tendon Section**

- Study of the extensor apparatus at the metacarpal head level and at the level of the head of the proximal and middle phalanges following screw placement.  
The lesion and its distance to the bone insertion are measured in mm, allowing us to assess the mechanical repercussion in the extension of the proximal and distal metacarpophalangeal and interphalangeal joints.

**Results**

**Bone Section**

- Measurement of the area of the metacarpal head and of the head of the proximal and middle phalanges.  
The metacarpal heads have an area of 231.31 mm<sup>2</sup> on average. The heads of the proximal and middle phalanges have an area of 98.85 mm<sup>2</sup> and 63.90 mm<sup>2</sup>, respectively (see ranges, in ► **Table 2**).

**Table 2** Average area and range of the head of the metacarpals, phalanges proximal y medium

	Average area	Area max / min
Metacarpal	231.31 mm <sup>2</sup>	299 / 193.55 mm <sup>2</sup>
Proximal phalange	98.85 mm <sup>2</sup>	113.96 / 66.62 mm <sup>2</sup>
Medium phalange	63.90 mm <sup>2</sup>	78.67 / 53.67 mm <sup>2</sup>

**Table 3** Area of the proximal portion of the screws

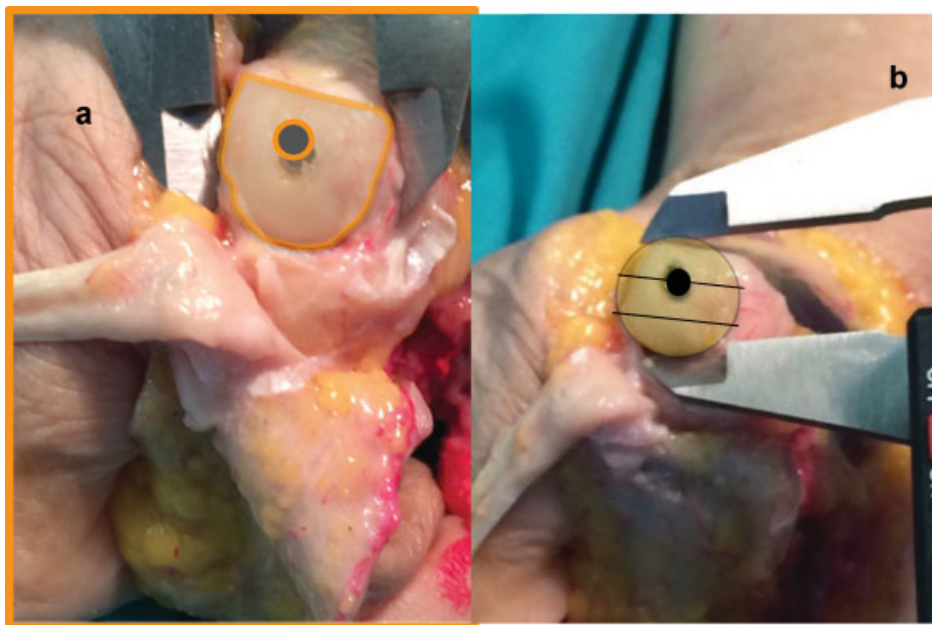
Width of the screw	Area
4.1 mm	13.20 mm <sup>2</sup>
3.6 mm	10.17 mm <sup>2</sup>
2.8 mm	6.15 mm <sup>2</sup>

- Measurement of the area of the lesion caused by the cannulated screws during their entry into the joint head. Screws that have a diameter of 4.1 mm in their proximal portion would affect an area of 13.20 mm<sup>2</sup>, while 3.6 mm and 2.8 mm screws impact an area of 10.17 mm<sup>2</sup> and 6.15 mm<sup>2</sup>, respectively.  
Herbert screws with a width of 3.6 and 2.8 mm at the proximal portion impact the same area as the screws with threads through their entire length (► **Table 3**).
- Percentage of damage to the metacarpal heads in relation to the entry area of the cannulated screws.
- The damage to the metacarpal heads following the placement of cannulated screws is seen at a rate of 5.70%, at most (► **Table 4**).
- Percentage of damage to the articular facets on the head of the proximal phalanges in relation to the area of the cannulated screws.  
In second and third fingers, the use of the 4.1 mm screw causes a 13.35% damage to the joint surface. In the fourth finger, we used a 3.6 mm screw, which caused a 10.28% damage of the joint head. In the fifth finger, 2.8 mm screws can be used generating an impact of 6.22% (► **Table 4**).
- Percentage of damage to the articular facets on the head of the middle phalanges in relation to the area of the cannulated screws.  
Upon placing 2.8 mm screws, the impact is 9.62%. In the middle phalanx of the fifth finger, it is not possible to use the intramedullary screws that we have due to the size of the medullary canal (► **Table 4**).
- Localization of the entry of the cannulated screws into the metacarpal head and into the proximal and middle phalangeal heads.

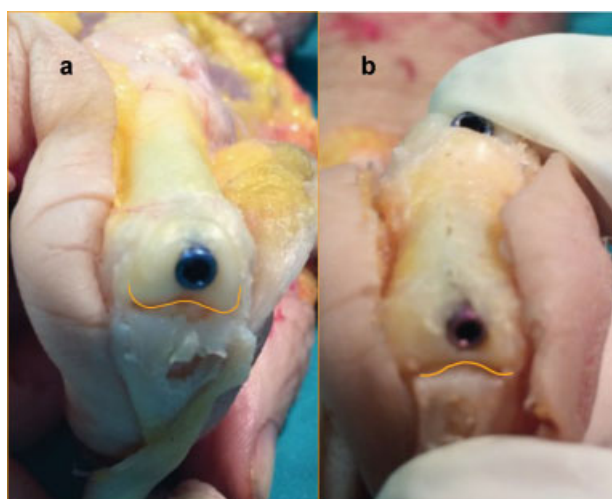
**Table 4** Percentage of the affected area produced by the introduction of a screw in total area of the head of metacarpals, phalanges proximal y medium

Bone	Screw	Percentage of joint involvement
Metacarpals	screw of 4.1	5.70%
	screw of 3.6	4.40%
Proximal phalange	screw of 4.1	13.35%
	screw of 3.6	10.28%
	screw of 2.8	6.22%
Medium phalange	screw of 2.8	9.62%





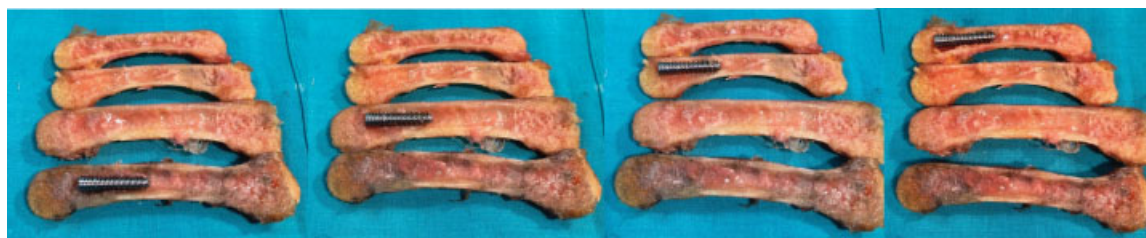**Fig. 4** (a) Articular surface lesion of the metacarpal caused by the insertion of the screw. (b) Position in its dorsal portion.



**Fig. 5** (a) Articular surface lesion of the proximal phalanx caused by the insertion of the screw. (b) Articular surface lesion of the middle phalanx caused by the insertion of the cannulated screw.

For the insertion of the screws, we perform maximum flexion of the distal bone of the joint, so that the affected head portion is the dorsal third of the metacarpal head and the intercondylar zone in the phalanges (→Figs. 4 and 5).

- The relationship between the external and internal size of the metacarpals in the diaphysis.  
The medullary canal of the second metacarpal is 5.23 mm; of the third is 5.24 mm; of the fourth is 4.20 mm, and of the fifth is 4 mm.  
The medullary canal of the fifth metacarpal is proportionally greater than the medullary of the rest of the metacarpals, occupying 63.86%.  
These measurements helped us to determine the appropriate screws, which are the ones with a 4.0 mm tip (→Figs. 6 and 7) (→Table 5).
- The relationship between the internal size of the proximal and middle phalanges in the diaphysis and the cannulated screws.  
With regard to the proximal phalanx, the medullary canal of the second finger is 4.45 mm; of the third finger is 4.44 mm; of the fourth is 3.64 mm, and of the fifth is 3.14 mm.  
These measurements allow us to use a 4.0 mm screw in second and third fingers. In the fourth finger, it is recommended to use 3.5 mm screws. In the fifth finger, 2.8 mm screws can be used (→Fig. 8) (→Table 6).  
With regard to the middle phalanx, the medullary canal of the second finger is 2.87 mm, of the third finger is 2.80 mm, of the fourth is 2.66 mm, and of the fifth finger is 1.80 mm.



**Fig. 6** Location of fully threaded screws in the medullary canal of the metacarpals.



**Fig. 7** Location of partially threaded screws in the medullary canal of a metacarpal.

The measurements obtained allow us to use the 2.8 mm and 2.2 mm screws on the second and third fingers. As for the fourth finger, 2.2 mm screws can be used as per the measurements obtained, and on the fifth finger, we cannot use the screws in a safe manner.

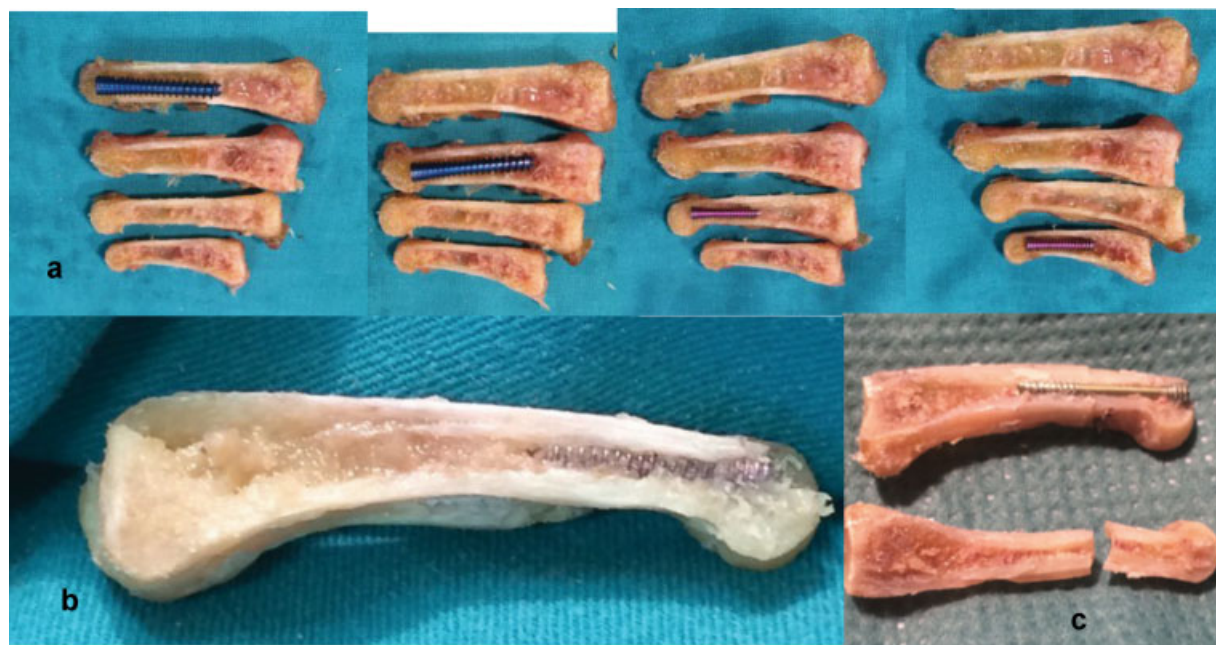
► **Fig. 9** shows the imprint that the threaded screws create on the medullary canal of the proximal and middle phalanges after being placed in the phalanx (► **Table 7**).

**Tendon Section**

- Study of the extensor apparatus at the metacarpal head level.
- The lesion we have measured is 2.94 mm in diameter on the tendon of the extrinsic extensor muscle.
- Study of the extensor apparatus with regard to the placement of the screw at the level of the proximal and middle phalangeal heads.
- The lesion that causes the screw placement on the extensor apparatus does not affect the insertion of the central band in the middle phalanx, by displaying an average minimum distance of 4 mm between the screw inlet and the insertion of the central band at the base of the proximal phalanx, a mean of 4.86 mm, and an average lesion of 2.70 mm in the tendon.
- Regarding the introduction of screws in the middle phalanx, the average distance between the screw inlet and the tendon insertion is 3.55 mm, with an extensor tendon injury of 1.90 mm, on average (► **Figs. 10** and **11**).

**Table 5** Measurement of the metacarpal medulla, percentage medulla takes over total metacarpal size and proper screw according our data

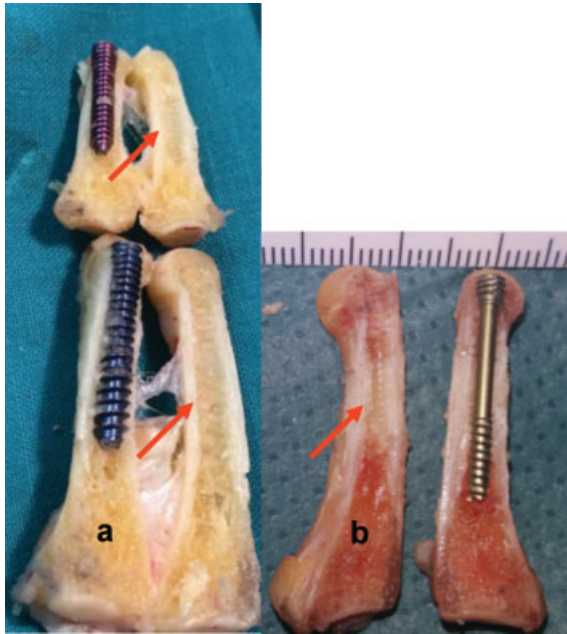
Metacarpals	Metacarpal medulla size	%*	Recommended screw
2 <sup>nd</sup> metacarpal	5.23 mm	44.14%	Screw - threading 4.1 mm / point 4 mm
3 <sup>rd</sup> metacarpal	5.24 mm	37.86%	Screw - threading 4.1 mm / point 4 mm
4 <sup>th</sup> metacarpal	4.20 mm	35.98%	Screw - threading 4.1 mm / point 4 mm
5 <sup>th</sup> metacarpal	4 mm	63.86%	Screw - threading 4.1 mm / point 4 mm



**Fig. 8** (a) Location of fully threaded screws in the medullary canal of the proximal phalanx. (b) Proximal phalanx with screw embedded in the medullary canal. (c) Proximal phalanx with a fracture, on which intramedullary screw placement has been performed. Note the imprint of the screw in the middle of the phalanx.

**Table 6** Measurement of the proximal phalanx medulla and proper screw according our data

Proximal phalange	Proximal phalange medulla size	Recommended screw
Proximal phalange 2 <sup>nd</sup> finger	4.45 mm	Screw - threading 4.1 mm / point 4 mm
Proximal phalange 3 <sup>rd</sup> finger	4.44 mm	Screw - threading 4.1 mm/ point 4 mm
Proximal phalange 4 <sup>th</sup> finger	3.64 mm	Screw - threading 3.6 mm/ point 3.5 mm
Proximal phalange 5 <sup>th</sup> finger	3.14 mm	Screw - threading 2.8 mm / point 2.5 mm



**Fig. 9** (a) Location of fully threaded screws in the medullary canal of the proximal and middle phalanges of the long fingers. (b) Proximal phalanx with partially threaded intramedullary screw embedded in the medullary canal. The red arrows mark the imprint of the threads of the screws.

## Discussion

Our study demonstrates that the cartilaginous lesion following the placement of intramedullary cannulated screws results in an articular surface defect of less than 15%, while preserving the bone insertions of the extensor apparatus. We also present the intramedullary size measurements to give guidance regarding the width of the appropriate screw, so that it gets embedded in the walls, without distending or breaking them.

We have looked into surgical fractures, those with alterations in rotation, excess angulation, as well as the presence of multiple fractures.

The long bones of the hand are formed by cancellous and cortical bone, but there are few literary references to their internal structure.

Our study emerged from a need to understand the alterations secondary to the introduction of intramedullary screws through the joint surface in the treatment of fractures. The percutaneous placement of these screws allows fixation through the intramedullary fit and the subchondral cancellous bone of the bone head, thus remaining hidden in it, without affecting the joint mechanics.

The metacarpals have a concave shape on their volar surface as a result of a radius that corresponds to 5/7 of its length, giving the palm its concave shape.<sup>14</sup> This anatomical feature means that placement of the screw inlet is located in the upper third of the head. We have approximated the head of the metacarpal to a spherical cap, as we needed a geometric figure with a formula that would allow us to calculate the area. In our study, the percentage of damage to the articular head was 5.70% for the screw used. Our study is consistent with the conclusions obtained in the study performed with 3D computed tomography (CT) on the heads of the metacarpals treated with headless intramedullary screws in neck fractures.<sup>15</sup>

The measurements of the medullary canal of the metacarpals allow us to affirm that, proportionally, the largest medullary canal is the fifth metacarpal, occupying 65.85% of that finger, compared with 44.14% for the second metacarpal, and 37.86% and 35.98% for the third and fourth metacarpals. This provides an insight regarding the size of the cortical bones, allowing us to conclude that the cortical bones of the third and fourth metacarpals are thicker, since these cortical bones represent over 60% of the entire metacarpals.

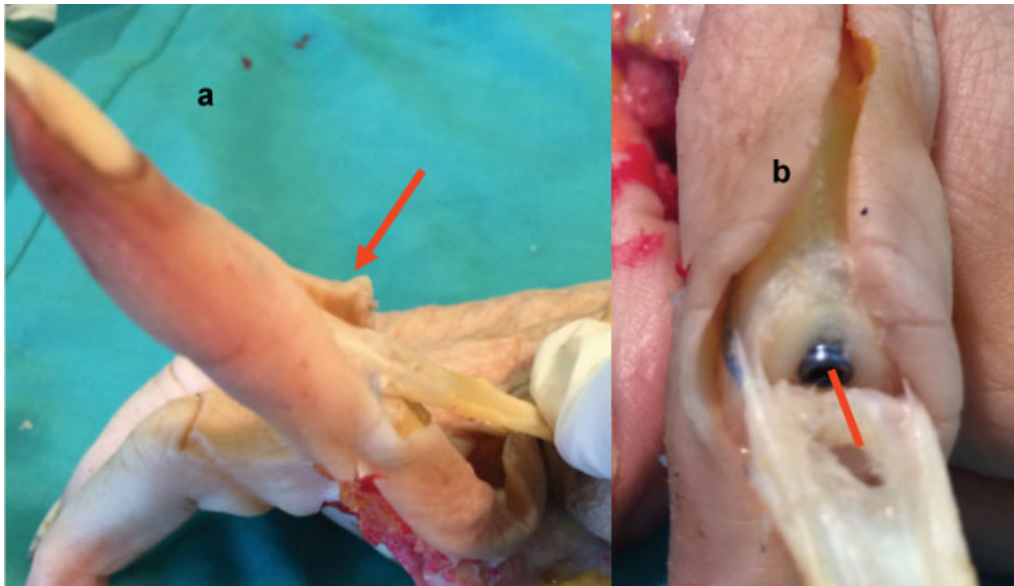
Apart from the anatomical data, this allows us to conclude that we can introduce a screw that is 4.1 mm wide in the medullary canal of the metacarpals, which would be a perfect fit in the medullary canal both in its frontal and sagittal views, without distending or breaking the cortical bones.

The heads of both phalanges have been approximated to two truncated cones joined by the base with a smaller diameter and

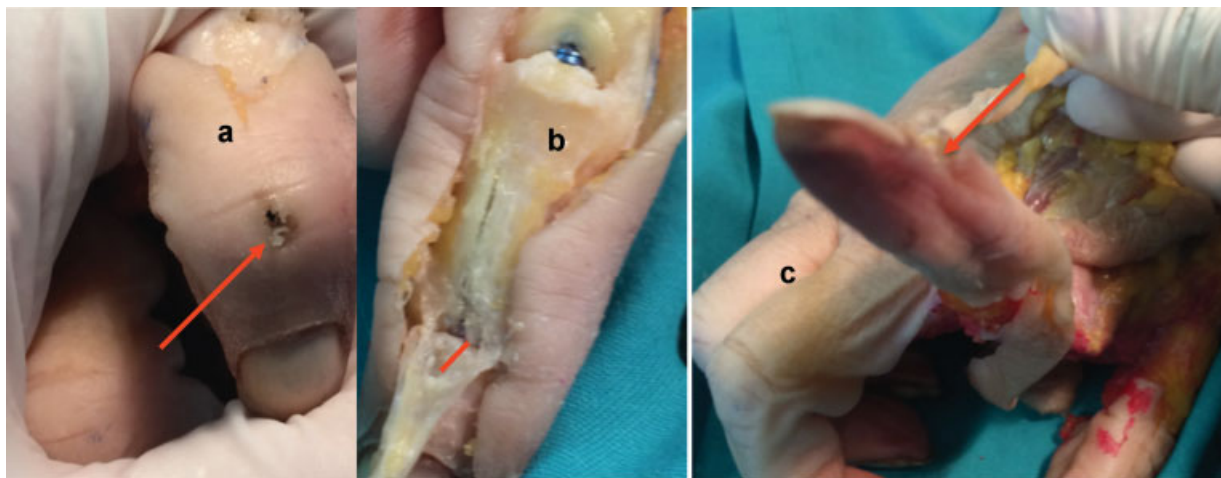
**Table 7** Measurement of the medium phalanx medulla and proper screw according our data

Proximal phalange	Medium phalange medulla size	Recommended screw
Proximal phalange 2 <sup>nd</sup> finger	2.87 mm	Screw - threading 2.8 mm/ point 2.5 mm
Proximal phalange 3 <sup>rd</sup> finger	2.80 mm	Screw - threading 2.8 mm/ point 2.5 mm
Proximal phalange 4 <sup>th</sup> finger	2.66 mm	Screw - threading 2.8 mm/ point 2.5 mm
Proximal phalange 5 <sup>th</sup> finger	1.80 mm	NO





**Fig. 10** (a) The traction of the extensor apparatus after placement of a screw in the proximal phalanx, showing the functionality of the middle band. (b) Proximal phalanx with intramedullary screw; distance between the screw entry point at the level of the extensor apparatus and the insertion of the middle band at the base of the middle phalanx.



**Fig. 11** (a) Location of the screw entry point. (b) Lesion on the extensor apparatus after placement of a screw in the middle phalanx. Note the distance between the lesion and the insertion point at the base of the distal phalanx. (c) Tendon traction shows a functioning extensor apparatus.

based on this geometric figure, we have found the corresponding areas. The palmar cortical bone is wider than the dorsal cortical bone. The shape of the medullary canal is like a tunnel with a flat floor on the palmar aspect and a dorsal arch. The cancellous bone is more abundant in the proximal part than in the distal part of all phalanges. The proximal phalanx displays a medullary canal greater than the middle phalanx, as the latter is narrower, shorter and, proportionally, with more cortical bone.<sup>16</sup> The outcomes of the Schulter-Ellis and Lazar study are consistent with our results with regard to the size of the proximal and middle phalanges.

The impact on the articular head of the phalanges is maintained within a percentage that allows us to use headless intramedullary screws, leading to a maximum impact of

13%, when 4.1 mm screws are used. In the literature, we have not encountered any anatomical studies except for the study by Bordas et al conducted on proximal phalanges, in which the cartilaginous involvement of the base of the proximal phalanx was measured after the introduction of intramedullary screws through the antegrade route, obtaining a percentage of 8.5% using 3 mm screws.<sup>17</sup>

We must take into account that our results are based on a limited number of anatomical models, and that, through our radiological studies, we have verified the enormous variability in the size of the bones studied, both with respect to their external size and the sizes of the medullary canal and of the cortical bone. These variations result in a fluctuation in the percentage of articular involvement, since bones that are large externally may



have a proportionally small medullary, indicating that we must use a screw with a smaller width, so that the impact on the joint is smaller. A conclusion has thus been reached that the choice of screws must be individualized for each patient.

The delicate balance of the different tendinous extensions is fundamental to maintain coordinated flexion and extension. Our study has demonstrated that the extensor apparatus, which is travelled through by the intramedullary screws during their insertion, is mechanically preserved and should allow the immediate mobilization of the injured area.

The majority of complications in the treatment of fractures occur in open surgery and due to the placement of external materials. The deeper the surgical dissection, the greater the possibility of causing complications due to the processes of devascularization, loss of periosteum and anatomical features of the few slip planes between the bone and the adjacent structures (absence of musculature and limited amount of fatty deposits). In case the scar produced is very close to the tendons, it will be able to encompass the structures and produce a tenodesis effect, especially in the phalanges<sup>18,19</sup>

Kirschner needles have the advantage of limited soft tissue alteration, but their use decreases the possibility of early mobilization, and according to some authors, it may lead to require tenolysis in 7% of cases. It also increases the chances of osteomyelitis (4%) as extracutaneous osteosynthesis material remains.<sup>20</sup>

The use of K-needles may lead to further complications, such as the rotation of the bone, in addition to those already commonly associated with the use of K-needles<sup>20</sup> (tendon rupture, osteomyelitis, skin infection, delayed union or non-union, as well as stiffness due to having to remain immobile, since K-needles do not provide sufficient stability for osteosynthesis).

Fixation with plates produces adhesions due to the need for further dissection of soft tissue. In addition to soft tissue dissection, the presence of a foreign body causes a scarring reaction, despite the efforts of commercial companies to make low profile plates and screws even smaller. In a randomized study, Fujitani<sup>21</sup> compared the results of K-needle placement with those of low profile plates, and the results obtained are better for the needles at both 3 and 6 months, consistent with the study by Facca<sup>22</sup> and the meta-analysis performed by Yammine.<sup>23</sup>

The intramedullary fixation method allows cannulated screws to be placed without causing loss of periosteum and with minimum dissection of soft tissues, which implies that the effects of scarring are decreased, as our clinical experience allows us to confirm.

We have demonstrated that the articular lesions are within the ranges that allow us to use the retrograde insertion of intramedullary cannulated screws without involving the bone insertion of the extensor apparatus, which makes this a safe technique in the treatment of fractures of the bones studied.

Our study has serious limitations, the most important of which is the small number of anatomical models. The approximation of surfaces to geometric figures is not perfect either, but in this case, we deem that it is sufficiently precise to be able to draw adequate conclusions.

## Conflict of Interest

Authors declare no conflict of interest.

## References

- Cheah AE, Yao J. Hand Fractures: Indications, the Tried and True and New Innovations. *J Hand Surg Am* 2016;41(06):712-722
- Winter M, Balaguer T, Bessière C, Carles M, Lebreton E. Surgical treatment of the boxer's fracture: transverse pinning versus intramedullary pinning. *J Hand Surg Eur Vol* 2007;32(06):709-713
- Kim JK, Kim DJ. Antegrade intramedullary pinning versus retrograde intramedullary pinning for displaced fifth metacarpal neck fractures. *Clin Orthop Relat Res* 2015;473(05):1747-1754
- Hornbach EE, Cohen MS. Closed reduction and percutaneous pinning of fractures of the proximal phalanx. *J Hand Surg [Br]* 2001;26(01):45-49(British And European Volume)
- Belsky MR, Eaton RG, Lane LB. Closed reduction and internal fixation of proximal phalangeal fractures. *J Hand Surg Am* 1984;9(05):725-729
- Elmaraghy MW, Elmaraghy AW, Richards RS, Chinchalkar SJ, Turner R, Roth JH. Transmetacarpal intramedullary K-wire fixation of proximal phalangeal fractures. *Ann Plast Surg* 1998;41(02):125-130
- Balaram AK, Bednar MS. Complications after the fractures of metacarpal and phalanges. *Hand Clin* 2010;26(02):169-177
- Aita MA, Mos PA, de Paula Cardoso Marques Leite G, Alves RS, Credidio MV, da Costa EF. Minimally invasive surgical treatment for unstable fractures of the proximal phalanx: intramedullary screw. *Rev Bras Ortop* 2015;51(01):16-23
- Giesen T, Gazzola R, Poggetti A, Giovanoli P, Calcagni M. Intramedullary headless screw fixation for fractures of the proximal and middle phalanges in the digits of the hand: a review of 31 consecutive fractures. *J Hand Surg Eur Vol* 2016;41(07):688-694
- Doarn MC, Nydick JA, Williams BD, Garcia MJ. Retrograde headless intramedullary screw fixation for displaced fifth metacarpal neck and shaft fractures: short term results. *Hand (NY)* 2015;10(02):314-318
- del Piñal F, Moraleda E, Rúas JS, de Piero GH, Cerezal L. Minimally invasive fixation of fractures of the phalanges and metacarpals with intramedullary cannulated headless compression screws. *J Hand Surg Am* 2015;40(04):692-700
- Ruchelsman DE, Puri S, Feinberg-Zadek N, Leibman MI, Belsky MR. Clinical outcomes of limited-open retrograde intramedullary headless screw fixation of metacarpal fractures. *J Hand Surg Am* 2014;39(12):2390-2395
- Boulton CL, Salzler M, Mudgal CS. Intramedullary cannulated headless screw fixation of a comminuted subcapital metacarpal fracture: case report. *J Hand Surg Am* 2010;35(08):1260-1263
- Lazar G, Schulter-Ellis FP. Intramedullary structure of human metacarpals. *J Hand Surg Am* 1980;5(05):477-481
- ten Berg PW, Mudgal CS, Leibman MI, Belsky MR, Ruchelsman DE. Quantitative 3-dimensional CT analyses of intramedullary headless screw fixation for metacarpal neck fractures. *J Hand Surg Am* 2013;38(02):322-330
- Schulter-Ellis FP, Lazar GT. Internal Morphology Of Human Phalanges. *J Hand Surg Am* 1984;9(04):477-481
- Borbas P, Dreu M, Poggetti A, Calcagni M, Giesen T. Treatment of proximal phalangeal fractures with an antegrade intramedullary screw: a cadaver study. *J Hand Surg Eur Vol* 2016;41(07):683-687
- Shimizu T, Omokawa S, Akahane M, et al. Predictors of the postoperative range of finger motion for comminuted periarticular metacarpal and phalangeal fractures treated with a titanium plate. *Injury* 2012;43(06):940-945
- Pun WK, Chow SP, So YC, et al. Unstable phalangeal fractures: treatment by A.O. screw and plate fixation. *J Hand Surg Am* 1991;16(01):113-117

- 20 Faruqi S, Stern PJ, Kiefhaber TR. Percutaneous pinning of fractures in the proximal third of the proximal phalanx: complications and outcomes. *J Hand Surg Am* 2012;37(07):1342–1348
- 21 Fujitani R, Omokawa S, Shigematsu K, Tanaka Y. Comparison of the intramedullary nail and low-profile plate for unstable metacarpal neck fractures. *J Orthop Sci* 2012;17(04):450–456
- 22 Facca S, Ramdhian R, Pelissier A, Diaconu M, Liverneaux P. Fifth metacarpal neck fracture fixation: Locking plate versus K-wire? *Orthop Traumatol Surg Res* 2010;96(05):506–512
- 23 Yamine K, Harvey A. Antegrade intramedullary nailing for fifth metacarpal neck fractures: a systematic review and meta-analysis. *Eur J Orthop Surg Traumatol* 2014;24(03):273–278