

# Effect of Kyphoplasty in the Treatment of Osteoporotic Vertebral Fractures Compared to Vertebroplasty – Overview of Systematic Reviews

## *Efeito da cifoplastia no tratamento de fraturas vertebrais osteoporóticas comparado ao da vertebroplastia - revisões das revisões sistemáticas publicadas*

Ricardo Vieira Botelho<sup>1</sup> Juliete Melo Diniz<sup>1</sup> Ulysses de Oliveira Sousa<sup>1</sup> Marcelo Luís Mudo<sup>1</sup>  
Matheus Fernandes de Oliveira<sup>1</sup>

<sup>1</sup> Post Graduation Program – Instituto de Assistência Médica ao Servidor Público Estadual, São Paulo, SP, Brazil

Address for correspondence Ricardo Vieira Botelho, Rua Pedro de Toledo, 1800, Vila Clementino, São Paulo, SP, Brazil, Zip Code 04039-000 (e-mail: bitbot@uol.com.br).

Arq Bras Neurocir 2017;34:217–224.

### Abstract

**Introduction** Vertebroplasty and kyphoplasty are possible options for vertebral augmentation after osteoporotic fractures. Both are percutaneous techniques with specific advantages and disadvantages. Our aim is to compare the clinical and radiological results of these two procedures.

**Methods** An overview of published systematic reviews in the literature on the effects of kyphoplasty compared with vertebroplasty was performed.

**Results** After short and long follow-up, the kyphoplasty group had lower pain scores on the visual analogue scale (VAS), lower scores in the Oswestry Disability index (ODI), greater restoration of the vertebral body height and lower kyphosis angle in the immediate postoperative period. There was less leakage of cement to the vertebral canal and extraspinal spaces.

**Conclusions** Compared with vertebroplasty, kyphoplasty achieved better results in pain relief, quality of life, correction of spinal deformity and lower risk of cement leakage.

### Keywords

- ▶ kyphoplasty
- ▶ vertebroplasty
- ▶ vertebral fracture
- ▶ osteoporosis

### Resumo

**Introdução** Vertebroplastia e cifoplastia são opções possíveis de tratamento para fraturas vertebrais osteoporóticas. Ambas são técnicas percutâneas com vantagens e desvantagens específicas. Nosso objetivo é comparar os resultados clínicos e radiológicos dos dois procedimentos.

**Métodos** Foi realizada uma revisão sistemática da literatura publicada sobre os efeitos da cifoplastia em comparação com a vertebroplastia.

**Resultados** No acompanhamento a curto e longo prazo, o grupo de cifoplastia teve valores mais baixos na escala visual analógica (EVA) de dor, valores mais baixos no



**Palavras-chave**

- ▶ cifoplastia
- ▶ vertebroplastia
- ▶ fratura vertebral
- ▶ osteoporose

índice de incapacidade de Oswestry (IIO), maior restauração da altura do corpo vertebral e menor ângulo de cifose no pós-operatório imediato. Houve menor incidência de extravasamento de cimento no canal vertebral e nos espaços extraespinhais.

**Conclusões** Em comparação com a vertebroplastia, a cifoplastia obteve melhores resultados no alívio da dor, na qualidade de vida, na correção de deformidade espinhal e menor risco de extravasamento de cimento.

## Introduction

It is estimated that 30% of the people over the age of 65 will have a vertebral body compression fracture caused by osteoporosis.<sup>1</sup> Osteoporotic fractures of the spine can lead to chronic pain, progressive deformity, reduced quality of life, and increased mortality.<sup>1-13</sup>

Since 1987, bone filling techniques have become progressively widespread, with benefits in the treatment of pain and associated deformity correction.<sup>5</sup> Vertebroplasty was initially introduced as a spinal cementation method for treating pain and preventing or treating vertebral collapse. Its major drawback is that it involves the direct injection of cement at high temperatures into the Haversian canals within the trabecular bone,<sup>5</sup> with risk of leakage into the spinal structures, potential damage to the spinal cord, and paraplegia.<sup>5,13-20</sup>

Kyphoplasty was developed to address the limitations and risks of vertebroplasty. The procedure was first performed in 1998, and its goals are similar to those of vertebroplasty. The technique, based on the principle of coronary stents, consists of placing an inflatable intravertebral balloon by the percutaneous route. The balloon creates a cavity which is then filled with cement in the same volume. Although there is an injection of cement at high temperature under pressure (similarly to vertebroplasty), it is not injected into the Haversian canals but into a created cavity, lowering the risks of leakage. In addition, the intravertebral balloon can be expanded to restore the vertebral body height, which is not possible with the vertebroplasty. From a technical standpoint, kyphoplasty follows almost the same fluoroscopic principles used in vertebroplasty.<sup>21-30</sup>

The aim of this study is to evaluate the effect of kyphoplasty, compared with that of vertebroplasty, for the treatment of osteoporotic vertebral fractures, based on an overview of published reviews.

## Methods

This study is a literature review of systematic reviews on the effects of kyphoplasty compared with vertebroplasty. References were retrieved electronically from the MEDLINE (via PubMed), Cochrane Database of Systematic Reviews and Google Scholar databases.

Only articles in English were considered. A structured search was conducted using the PICOT method, as described below:

**Participants:** Patients with osteoporotic vertebral fractures.

**Intervention:** Kyphoplasty.

**Controls:** Vertebroplasty.

**Outcomes:** All clinically relevant outcomes.

**Types of study:** Published systematic reviews.

**Search query:** (“Kyphoplasty” [MeSH Terms] OR “kyphoplasty” [All Fields]) AND “Review” [Publication Type] - 272

## Methodological Quality Assessment

We used the validated measurement tool to assess systematic reviews (AMSTAR) to evaluate the methodological quality of the retrieved studies.<sup>11-14</sup> This tool consists of 11 questions designed to determine how strictly a systematic review was conducted. Each answer is assigned a score equivalent to one point per positive response. Quality is graded as low (0 to 4 points), moderate (5 to 8 points), or high (9 points or more).<sup>11-14</sup>

## Results

Our search strategy yielded 31 records of systematic reviews, selected by title. Among these, the following reviews were analyzed: three reviews comparing kyphoplasty versus vertebroplasty versus conservative treatment;<sup>15-17</sup> three reviews comparing kyphoplasty versus conservative treatment;<sup>18-20</sup> and six reviews comparing kyphoplasty and vertebroplasty.<sup>17-19,21-23</sup> Head-to-head comparisons of vertebroplasty versus kyphoplasty were the object of this analysis. Because there was an overlapping of the reviews above mentioned, the final number of studies evaluated was 9 (► **Fig. 1** and ► **Table 1**).

## Data Extraction

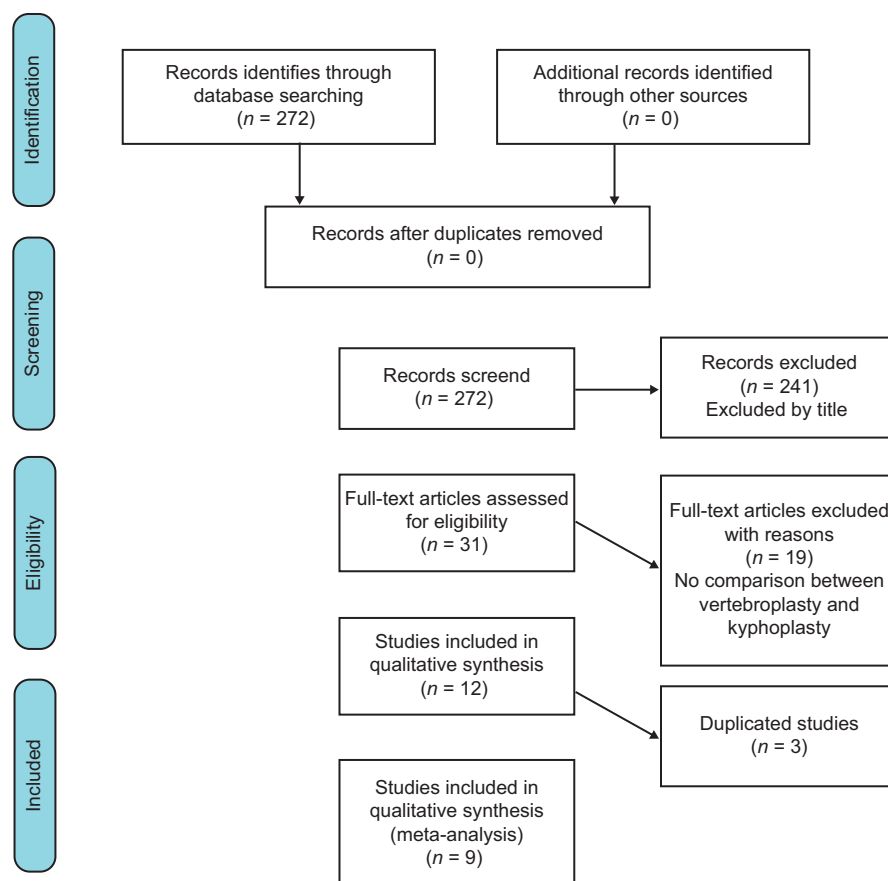
The latest review was published in 2016,<sup>6</sup> and included 4 randomized trials, 14 prospective cohort studies, and 14 retrospective cohort studies for analysis.<sup>6</sup>

The second most recent review<sup>24</sup> identified two randomized trials. The study conducted by Bae et al<sup>25</sup> used Cortoss (Orthovita, Malvern, PA, USA) cement as the spinal fill method, and was thus excluded from our analysis, as all other studies used methyl methacrylate cements.

Wang et al<sup>26</sup> identified only one randomized trial.

Taylor et al (2007)<sup>19</sup> evaluated five comparative studies, several non-comparative prospective studies, and no randomized trials.

Hulme et al (2006)<sup>22</sup> also did not assess any randomized trial. Most of the analyzed studies were retrospective (37); 25 were prospective; and did not describe their designs.



**Fig. 1** Prisma flow diagram of evaluated studies.

Hsieh et al (2013)<sup>27</sup> reviewed not only primary studies, but systematic reviews as well.

In 2014, a health technology assessment of percutaneous vertebroplasty and kyphoplasty was published by a UK group.<sup>23</sup> The authors identified nine randomized trials. Out of these, only one (Liu et al) directly compared kyphoplasty and vertebroplasty.<sup>28</sup>

The most complete and current review, which evaluated the largest number of publications, was conducted by Liang et al.<sup>6</sup> All the comparative studies, including 3,274 patients (1,653 undergoing kyphoplasty and 1,621 undergoing vertebroplasty), were covered in their meta-analysis.<sup>30-63</sup>

As stated by the current evidence regarding overviews of systematic reviews, it is possible to choose the last or the best existent review to be used as the main source for a final review.<sup>11-14</sup> As the revision of Liang et al included all the described studies present in other revisions, this revision was selected for the data analysis, ensuring that there was no data duplication. Data are presented in **Table 1**.

## Outcomes

### Clinical

#### Visual Analogue Scale (VAS)

Visual analogue scale at short-term follow-up (less than 1 week of follow-up): Eighteen studies reported results as

weighted mean difference (WMD), with the kyphoplasty group scoring lower on the pain scale (- 0.2; 95% CI - 0.27 to - 0.63;  $p < 0.01$ ).<sup>6,30-63</sup>

Visual analogue scale (after 6 months of follow-up): This outcome was assessed by 14 studies. Again, the kyphoplasty group had lower scores on the pain scale (- 0.46; 95% CI - 0.57 to - 0.36;  $p < 0.01$ ).<sup>6,18-63</sup>

#### Oswestry Disability Index (ODI)

The short-term ODI scores were evaluated by 7 studies. The difference between the kyphoplasty and vertebroplasty groups was significant (- 17.56; 95% CI - 18.07 to - 17.05;  $p < 0.01$ ).<sup>6,18-63</sup>

Regarding the clinical outcomes of both techniques, the pooled analysis revealed a statistically significant difference favoring kyphoplasty compared with vertebroplasty in the short-term and long-term VAS,<sup>6</sup> yielding lower scores than vertebroplasty. The difference, however, was insufficient to achieve clinical benefit. The minimal clinically significant difference in short-term ODI scores varies in the literature, but 17 points favoring kyphoplasty has been considered as clinically significant.

### Radiological

The height of the anterior third of the vertebral body was evaluated in 14 studies. On late follow-up, patients undergoing kyphoplasty had a higher standardized average difference in

**Table 1** Summarized data from reviews evaluated in the present manuscript

Author/Year	Liang et al, 2016	Bouza et al, 2006	Taylor et al, 2007
Included studies	32 (4 RCTs)	26	43
Objective	To compare clinical/radiological outcomes and complication of KP/VP.	To analyze the collected body of evidence regarding the efficacy and safety of KP in the treatment of VCFs.	update of a previous systematic review and meta-analysis of the efficacy and safety of KP
Clinical outcomes	Short-term and Long-term VAS scores were evaluated. The result showed a significant difference favoring KP.	Data from comparative studies: Combined analysis of the studies shows KP to yield a mean reduction in pain intensity that is 55.6% greater than that afforded by conservative management. The results of a retrospective analysis of KP versus vertebroplasty in tumoral VCFs show that, globally, no significant differences are found between the two techniques in terms of pain relief.	Data from comparative studies: VAS pain was significantly reduced with KP at 3, 6, 12 and 36 months follow up ( $p < 0.001$ ). These reductions in pain were greater (than those observed at the same point in time with medical care treatment).
Radiological outcomes	Kyphoplasty resulted more improvement in the kyphotic angle (immediate and final follow-up) than with the VP procedure	Comparative studies: KP x VP: KP produces a statistically significant improvement in local kyphosis	Two studies reported improvement in the vertebral height and kyphotic angle with KP at follow-up. These improvements exceeded those of vertebroplasty
Complications	No significant differences in the rate of postoperative fractures. Cement leakage to the intraspinal space was more frequently observed in the VP group ( $p = 0.35$ ).	Evaluation of the 19 studies that contribute data shows a total of 134 cement leakages in 1,742 treated levels, out of which only 1.5% are described as symptomatic or cause clinical sequelae. Combined analysis of two comparative studies showed that patients subjected to kyphoplasty are at a significantly lesser risk of suffering new fractures 6 months after the procedure than patients in the comparator group studies subjected to medical management.	A total of 189 cement leakages were reported in 2,239 vertebrae submitted a KP. This corresponds to 81 cement leaks per 1,000 fractures undergoing KP per year. A total of 171 new or incident fractures were reported in 1,151 patients across 16 studies, 110 (64%) of which occurred in the vertebrae adjacent to the procedure.
Author/Year	Ma et al, 2012	Papanastassiou et al, 2012	Shi-Ming et al, 2015
Included studies	12 (1 RCT)	27	11
Objective	To evaluate the safety and efficacy of (KP) compared with (VP) and provide recommendations for using these procedures to treat (VCF).	To determine if differences in safety or efficacy exist between KP, VP and conservative treatment of osteoporotic vertebral fractures	To determine the efficacy and safety for the treatment of VCFs to reach a relatively conclusive answer
Clinical outcomes	Long-term VAS scores: the RCT and CCT subgroup analyses found no significant differences between the KP and VP groups. However, the cohort study subgroup analysis found that KP was more effective than VP	Pain reduction in both KP and VP was superior to that observed in conservative treatment, while no difference was found between KP and VP ( $p = 0.35$ )	VAS: The short-term subgroup found that KP was more effective than VP, but subgroup analysis of long-term did not find a significant difference between the VP and KP groups.
Radiological outcomes	Long-term postoperative kyphosis angles. The RCT and cohort study subgroup analyses found that the mean long-term kyphosis angle of the KP patients was significantly smaller than the angle of the VP patients. However, CCT subgroup analysis did not find a significant difference between the KP and VP patients.	Kyphoplasty resulted in greater kyphosis reduction than VP (4.88 versus 1.7°, $P<0.01$ )	Short-term kyphotic angle: the VP and KP patients did not differ significantly in the USA subgroup. However, the Europe and Asia subgroups analysis found that KP was more effective than VP
Complications	The overall pooled analysis of bone cement leakage found a significantly lower rate in KP patients than in VP patients. However, the CCT subgroup analysis did not find a significant difference between the KP and VP groups. Adjacent vertebral fracture: there were no significant differences between the KP and VP patients in any of the subgroups analyzed	Cement extravasation, reported as an event rate, was significantly less frequent for KP, than for VP. Subsequent fractures occurred more frequently in the conservative group compared with VP and KP	Cement leakage: the pooled analysis showed that there was no significant difference between these two interventions. Adjacent fractures: these two interventions had similar risk for a subsequent fracture

**Table 1** (Continued)

Author/Year	Liang et al, 2016	Bouza et al, 2006	Taylor et al, 2007
Author/Year	Robinson et al, 2012	Hulme et al, 2006	Stevenson et al, 2014
Included studies	8	69	9 RCTs
Objective	This systematic review analyses randomized controlled trials on VP and KP to provide an overview on the current evidence	To evaluate the safety and efficacy of VP and KP	To evaluate the clinical effectiveness and cost-effectiveness of VP and KP in reducing pain and disability in people with VCFs in England and Wales.
Clinical outcomes	All treatment and control groups had significant improvement from baseline to follow-up at 1, 3, and 12 months. Pooled analyze not described	Visual analog pain scores (VAS) were reduced from an average of 8.2 and 7.15 to 3.0 and 3.4 for vertebroplasty and kyphoplasty, respectively	–
Radiological outcomes	Not evaluated	Mean kyphotic angle restoration was 6.6° and 6.6° for vertebroplasty and kyphoplasty, respectively. Not all subjects had a reduction in kyphotic angle or restoration of height (34% and 39% of KP and VP interventions)	Four studies reported changes in BH and/or angular deformity. However, because of because of heterogeneity, the data was not pooled.
Complications	Not evaluated	Cement leakage occurred for 41% and 9% of treated vertebrae for vertebroplasty and kyphoplasty, respectively. New fractures of adjacent vertebrae occurred for both procedures at rates that are approximately equivalent to the general osteoporotic population that had a previous vertebral fracture.	Cement leakage: the pooled data suggest an incidence of 44% for VP compared with 27% for KP. Only three studies reported the number of patients who suffered new radiographic vertebral fractures during the study period. None of these studies found a statistically significant difference between treatment groups

Abbreviations: CCT, controlled clinical trial; KP, kyphoplasty; RCT, randomized controlled trial; VAS, visual analogue scale; VBH, vertebral bone height; VCF, vertebral compression fractures; VP, vertebroplasty.

the vertebral body height (greater correction) (2.79; 95% CI 2.39 to 3.19;  $p < 0.01$ ).<sup>6,18–63</sup>

The height of the middle third of the vertebral body was greater in the kyphoplasty group, as measured by the standardized mean difference (6.92; 95% CI 6.31 to 7.52;  $p < 0.01$ ).<sup>6,18–63</sup>

The kyphosis angle in the immediate postoperative period was evaluated in 15 studies, and showed greater improvement in the kyphoplasty group compared with the vertebroplasty group (-2.5; 95%CI -2.16 to -2.84;  $p < 0.01$ ). The kyphotic angle in the late postoperative period was assessed by 9 studies, and the kyphoplasty group was again superior to the vertebroplasty group.<sup>6,18–63</sup> The clinical and radiological outcomes are briefly summarized in ► **Table 2**.

### Complications

Cement leakage into the vertebral canal was less frequent in the kyphoplasty group than in the vertebroplasty group (OR 0.5; 95% CI 0.3 to 0.85;  $p = 0.035$ ). Extraspinal leakage was also less frequent with kyphoplasty than with vertebroplasty (OR 0.36; 95% CI 0.21 to 0.62;  $p = 0.15$ ).<sup>6,18–63</sup>

Adjacent vertebral fractures were reported in 3 studies, with no significant difference between techniques.<sup>6,18–63</sup>

### Methodological Quality Assessment of Selected Reviews

The sole review selected for analysis (Liang 2016) was assigned 7 of 11 possible points on the AMSTAR score, corresponding to a moderate methodological quality.<sup>11–14</sup>

**Table 2** Clinical and radiological outcomes compared between kyphoplasty (KP) and vertebroplasty (VP)

Outcome			Result	Statistics
Clinical	VAS	Short term	Kp < VP	$p < 0.01$
		Long term	Kp < VP	$p < 0.01$
	ODI	–	Kp < VP	$p < 0.01$
Radiological	Height of anterior third of the vertebral body	–	KP > VP	$p < 0.01$
	Height of middle third of the vertebral body	–	KP > VP	$p < 0.01$
	Kyphosis angle	–	KP > VP	$p < 0.01$

Abbreviations: KP, kyphoplasty; ODI, Oswestry Disability Index; VAS, visual analogue scale; VP, vertebroplasty.

In all analyzed outcomes, kyphoplasty was superior to vertebroplasty. There were lower scores in visual analogue scale (VAS) and Oswestry disability index (ODI), and better increase in the height of vertebral body and in the kyphosis angle.

## Discussion

Vertebral body fractures secondary to osteoporosis are highly prevalent and cause significant morbidity. They are associated with chronic pain, progressive deformity, reduced quality of life, and increased mortality. While treatment can be conservative or surgical, spinal augmentation techniques play a key role in the management of these cases, as they are effective and minimally invasive options.<sup>1–30</sup>

Vertebroplasty was the first vertebral augmentation technique to be implemented. Although technically effective, it has the drawback of requiring direct injection of cement at high temperature and pressure directly into the Haversian canal system within the trabecular bone, with a risk of leakage into the spinal and extraspinal structures.<sup>1–30</sup> Of particular concern is the possibility of high-temperature cement leakage from the Haversian canals into the epidural veins. The vertebral venous content oscillates with the vertebral deformation during the endplate loading. This contributes to the communication into the vertebral venous plexus and, potentially, a cement leakage into the vertebral canal and spinal cord injury. Kyphoplasty has the advantage of using a balloon to create an intravertebral cavity that allows the injection of intravertebral bone cement with lower leakage risk.<sup>1–30</sup>

Although there are many studies on these two techniques, there is no consensus in the literature regarding the superiority of one method over the other. We conducted a systematic review of literature reviews to synthesize the current concept of their clinical efficacy.<sup>1–30</sup>

In our literature review, we identified three systematic reviews comparing kyphoplasty versus vertebroplasty versus conservative treatment, all limited to randomized studies. Only one randomized study comparing both techniques was described.<sup>28</sup>

Regarding the clinical outcomes of both techniques, kyphoplasty was superior to vertebroplasty in short-term and long-term VAS and short-term ODI, yielding lower scores than vertebroplasty. Pain control was more effective with kyphoplasty.<sup>6</sup>

Regarding radiological outcomes, kyphoplasty achieved greater differences in the height of the anterior third and middle third of the vertebrae, reflecting better reestablishment of the bone architecture. The kyphotic angles in the immediate and late postoperative period were also significantly lower in the kyphoplasty group compared with the vertebroplasty group, which is consistent with greater correction of the deformity.<sup>6</sup>

Osteoporotic deformities are another factor that contributes to pain, discomfort, and impaired quality of life. Promoting optimal correction of the deformity has direct implications for pain management and spinal sagittal imbalance correction. Kyphoplasty was superior to vertebroplasty in correcting deformities in the sagittal plane.<sup>6</sup>

Cement leakage and adjacent vertebral fractures were evaluated as complications. Leakage of cement into the vertebral canal and extraspinal spaces was significantly more frequent in the vertebroplasty than in the kyphoplasty group. Conversely, fractures in the adjacent vertebral levels

were reported in few studies, without evidence of a significant difference between the techniques.<sup>6</sup>

Complications arising from vertebroplasty may be classified as mild (temporary increase in pain, transient hypotension), moderate (infection, leakage of cement into the foraminal, epidural, or dural space), or severe (cement leakage into the paravertebral veins, pulmonary embolism, cardiac perforation, cerebral embolism, or even death). Leakage of cement into the epidural or foraminal space is considered a rare complication. However, as most cases are clinically silent, the true prevalence may be as high as 40%. Paraplegia due to a cement-related spinal cord compression may occur in 0.4% of patients. Needle traversal of laminae instead of the pedicle can occur, especially in the thoracic vertebrae, where the pedicle is smaller; this can lead to catastrophic complications.<sup>6</sup>

The optimal method should concentrate the deposition of bone cement into the vertebrae, preferably supporting the middle and anterior thirds of the spinal column, which are the main sites of bone loss. Furthermore, the ideal method would isolate the cement from the rich neurovascular structures in the vicinity. In this line, the vertebral canal and extravertebral cement leakage rates were lower with kyphoplasty than with vertebroplasty.

Therefore, the current evidence supports that kyphoplasty has superior efficacy in terms of clinical and radiographic outcomes and is associated with fewer complications than vertebroplasty.

This study is limited by the absence of a definitive guideline for conducting literature reviews of systematic reviews. Instead, we modeled our design after suggestions and published guidelines. Furthermore, we evaluated all the available reviews, but only the last one (Liang et al) was chosen as a parameter, as it was the most recent and robust, and it contained all the published studies of interest.

New randomized trials should be encouraged to analyze larger samples of patients and assess the heterogeneity of effects.

### Conflicts of Interest

Authors declare no conflicts of interest

## References

- 1 Bonnick SL. Osteoporosis in men and women. *Clin Cornerstone* 2006;8(01):28–39
- 2 Yeh ML, Heggenes MH, Chen HH, Jassawalla J, Luo ZP. Compressive loading at the end plate directly regulates flow and deformation of the basivertebral vein: an analytical study. *J Orthop Surg* 2006;1:18
- 3 Oleksik A, Ott SM, Vedi S, Bravenboer N, Compston J, Lips P. Bone structure in patients with low bone mineral density with or without vertebral fractures. *J Bone Miner Res* 2000;15(07):1368–1375
- 4 Lyles KW, Gold DT, Shipp KM, Pieper CF, Martinez S, Mulhausen PL. Association of osteoporotic vertebral compression fractures with impaired functional status. *Am J Med* 1993;94(06):595–601
- 5 Takata S, Yasui N. Disuse osteoporosis. *J Med Invest* 2001;48(3–4):147–156
- 6 Liang L, Chen X, Jiang W, et al. Balloon kyphoplasty or percutaneous vertebroplasty for osteoporotic vertebral compression fracture? An updated systematic review and meta-analysis. *Ann Saudi Med* 2016;36(03):165–174

- 7 Martelli N, Devaux C, van den Brink H, Pineau J, Prognon P, Borget I. A Systematic Review of the Level of Evidence in Economic Evaluations of Medical Devices: The Example of Vertebroplasty and Kyphoplasty. *PLoS One* 2015;10(12):e0144892
- 8 Martín-López JE, Pavón-Gómez MJ, Romero-Tabares A, Molina-López T. Stentoplasty effectiveness and safety for the treatment of osteoporotic vertebral fractures: a systematic review. *Orthop Traumatol Surg Res* 2015;101(05):627–632
- 9 Feng H, Huang P, Zhang X, Zheng G, Wang Y. Unilateral versus bilateral percutaneous kyphoplasty for osteoporotic vertebral compression fractures: A systematic review and meta-analysis of RCTs. *J Orthop Res* 2015;33(11):1713–1723
- 10 Guo JB, Zhu Y, Chen BL, et al. Surgical versus non-surgical treatment for vertebral compression fracture with osteopenia: a systematic review and meta-analysis. *PLoS One* 2015;10(05):e0127145
- 11 Whitlock EP, Lin JS, Chou R, Shekelle P, Robinson KA. Using existing systematic reviews in complex systematic reviews. *Ann Intern Med* 2008;148(10):776–782
- 12 White CM, Ip S, McPheeters M, et al. *Using Existing Systematic Reviews to Replace De Novo Processes in Conducting Comparative Effectiveness Reviews*. In: Agency for Healthcare Research and Quality. *Methods Guide for Comparative Effectiveness Reviews*. Rockville, MD: Agency for Healthcare Research and Quality; September 2009<http://effectivehealthcare.ahrq.gov>
- 13 Robinson KA, Whitlock EP, Oneil ME, et al. *Integration of Existing Systematic Reviews*. *AHRQ Publication No. 14-EHC016-EF*. Rockville, MD: Agency for Healthcare Research and Quality; June 23, 2014<http://effectivehealthcare.ahrq.gov>
- 14 Robinson KA, Whitlock EP, Oneil ME, et al. Integration of existing systematic reviews into new reviews: identification of guidance needs. *Syst Rev* 2014;3:60
- 15 Bouza C, López T, Magro A, Navalpotro L, Amate JM. Efficacy and safety of balloon kyphoplasty in the treatment of vertebral compression fractures: a systematic review. *Eur Spine J* 2006;15(07):1050–1067
- 16 Taylor RS, Taylor RJ, Fritzell P. Balloon kyphoplasty and vertebroplasty for vertebral compression fractures: a comparative systematic review of efficacy and safety. *Spine* 2006;31(23):2747–2755
- 17 Ma XL, Xing D, Ma JX, Xu WG, Wang J, Chen Y. Balloon kyphoplasty versus percutaneous vertebroplasty in treating osteoporotic vertebral compression fracture: grading the evidence through a systematic review and meta-analysis. *Eur Spine J* 2012;21(09):1844–1859
- 18 Papanastassiou ID, Phillips FM, Van Meirhaeghe J, et al. Comparing effects of kyphoplasty, vertebroplasty, and non-surgical management in a systematic review of randomized and non-randomized controlled studies. *Eur Spine J* 2012;21(09):1826–1843
- 19 Taylor RS, Fritzell P, Taylor RJ. Balloon kyphoplasty in the management of vertebral compression fractures: an updated systematic review and meta-analysis. *Eur Spine J* 2007;16(08):1085–1100
- 20 Shi-Ming G, Wen-Juan L, Yun-Mei H, Yin-Sheng W, Mei-Ya H, Yan-Ping L. Percutaneous vertebroplasty and percutaneous balloon kyphoplasty for osteoporotic vertebral compression fracture: A metaanalysis. *Indian J Orthop* 2015;49(04):377–387
- 21 Robinson Y, Olerud C. Vertebroplasty and kyphoplasty—a systematic review of cement augmentation techniques for osteoporotic vertebral compression fractures compared to standard medical therapy. *Maturitas* 2012;72(01):42–49
- 22 Hulme PA, Krebs J, Ferguson SJ, Berlemann U. Vertebroplasty and kyphoplasty: a systematic review of 69 clinical studies. *Spine* 2006;31(17):1983–2001
- 23 Stevenson M, Gomersall T, Lloyd Jones M, et al. Percutaneous vertebroplasty and percutaneous balloon kyphoplasty for the treatment of osteoporotic vertebral fractures: a systematic review and cost-effectiveness analysis. *Health Technol Assess* 2014;18(17):1–290
- 24 Borgström F, Beall DP, Berven S, et al. Health economic aspects of vertebral augmentation procedures. *Osteoporos Int* 2015;26(04):1239–1249
- 25 Bae H, Shen M, Maurer P, et al. Clinical experience using Cortoss for treating vertebral compression fractures with vertebroplasty and kyphoplasty: twenty four-month follow-up. *Spine* 2010;35(20):E1030–E1036
- 26 Wang H, Sribastav SS, Ye F, et al. Comparison of Percutaneous Vertebroplasty and Balloon Kyphoplasty for the Treatment of Single Level Vertebral Compression Fractures: A Meta-analysis of the Literature. *Pain Physician* 2015;18(03):209–222
- 27 Hsieh MK, Chen LH, Chen WJ. Current concepts of percutaneous balloon kyphoplasty for the treatment of osteoporotic vertebral compression fractures: evidence-based review. *Biomed J* 2013;36(04):154–161
- 28 Liu JT, Liao WJ, Tan WC, et al. Balloon kyphoplasty versus vertebroplasty for treatment of osteoporotic vertebral compression fracture: a prospective, comparative, and randomized clinical study. *Osteoporos Int* 2010;21(02):359–364
- 29 Song D, Meng B, Gan M, et al. The incidence of secondary vertebral fracture of vertebral augmentation techniques versus conservative treatment for painful osteoporotic vertebral fractures: a systematic review and meta-analysis. *Acta Radiol* 2015;56(08):970–979
- 30 Chen LX, Li YL, Ning GZ, et al. Comparative efficacy and tolerability of three treatments in old people with osteoporotic vertebral compression fracture: a network meta-analysis and systematic review. *PLoS One* 2015;10(04):e0123153
- 31 Elder BD, Lo SF, Holmes C, et al. The biomechanics of pedicle screw augmentation with cement. *Spine J* 2015;15(06):1432–1445
- 32 Srinivasan D, Than KD, Wang AC, et al. Radiation safety and spine surgery: systematic review of exposure limits and methods to minimize radiation exposure. *World Neurosurg* 2014;82(06):1337–1343
- 33 Ivanishvili Z, Fourney DR. Incorporating the Spine Instability Neoplastic Score into a Treatment Strategy for Spinal Metastasis: LMNOP. *Global Spine J* 2014;4(02):129–136
- 34 Wood KB, Li W, Lebl DR, Ploumis A. Management of thoracolumbar spine fractures. *Spine J* 2014;14(01):145–164
- 35 Chandra RV, Yoo AJ, Hirsch JA. Vertebral augmentation: update on safety, efficacy, cost effectiveness and increased survival? *Pain Physician* 2013;16(04):309–320
- 36 Yang LY, Wang XL, Zhou L, Fu Q. A systematic review and meta-analysis of randomized controlled trials of unilateral versus bilateral kyphoplasty for osteoporotic vertebral compression fractures. *Pain Physician* 2013;16(04):277–290
- 37 Khan OA, Brinjikji W, Kallmes DF. Vertebral augmentation in patients with multiple myeloma: a pooled analysis of published case series. *AJNR Am J Neuroradiol* 2014;35(01):207–210
- 38 Wang LJ, Yang HL, Shi YX, Jiang WM, Chen L. Pulmonary cement embolism associated with percutaneous vertebroplasty or kyphoplasty: a systematic review. *Orthop Surg* 2012;4(03):182–189
- 39 Bliemel C, Oberkircher L, Buecking B, Timmesfeld N, Ruchholtz S, Krueger A. Higher incidence of new vertebral fractures following percutaneous vertebroplasty and kyphoplasty—fact or fiction? *Acta Orthop Belg* 2012;78(02):220–229
- 40 Body JJ, Bergmann P, Boonen S, et al. Non-pharmacological management of osteoporosis: a consensus of the Belgian Bone Club. *Osteoporos Int* 2011;22(11):2769–2788
- 41 Lutz S, Berk L, Chang E, et al; American Society for Radiation Oncology (ASTRO). Palliative radiotherapy for bone metastases: an ASTRO evidence-based guideline. *Int J Radiat Oncol Biol Phys* 2011;79(04):965–976
- 42 Röllinghoff M, Zarghooni K, Dargel J, et al. The present role of vertebroplasty and kyphoplasty in the treatment of fresh vertebral compression fractures. *Minerva Chir* 2010;65(04):429–437
- 43 Mendel E, Bourekas E, Gerszten P, Golan JD. Percutaneous techniques in the treatment of spine tumors: what are the diagnostic and therapeutic indications and outcomes? *Spine* 2009;34(22, Suppl):S93–S100

- 44 Krueger A, Bliemel C, Zettl R, Ruchholtz S. Management of pulmonary cement embolism after percutaneous vertebroplasty and kyphoplasty: a systematic review of the literature. *Eur Spine J* 2009;18(09):1257–1265
- 45 Felder-Puig R, Piso B, Guba B, Gartlehner G. [Kyphoplasty and vertebroplasty for the management of osteoporotic vertebral compression fractures: a systematic review]. *Orthopade* 2009;38(07):606–615
- 46 McGirt MJ, Parker SL, Wolinsky JP, Witham TF, Bydon A, Gokaslan ZL. Vertebroplasty and kyphoplasty for the treatment of vertebral compression fractures: an evidenced-based review of the literature. *Spine J* 2009;9(06):501–508
- 47 Shen MS, Kim YH. Vertebroplasty and kyphoplasty: treatment techniques for managing osteoporotic vertebral compression fractures. *Bull NYU Hosp Jt Dis* 2006;64(3-4):106–113
- 48 Witham TF, Khavkin YA, Gallia GL, Wolinsky JP, Gokaslan ZL. Surgery insight: current management of epidural spinal cord compression from metastatic spine disease. *Nat Clin Pract Neurol* 2006;2(02):87–94, quiz 116
- 49 DaFonseca K, Baier M, Grafe I, et al. [Balloon kyphoplasty in the treatment of vertebral fractures]. *Unfallchirurg* 2006;109(05):391–399, quiz 400
- 50 Verlaan JJ. Comment on: efficacy and safety of balloon kyphoplasty in the treatment of vertebral compression fractures: a systematic review (C. Bouza et al.). *Eur Spine J* 2006;15(07):1068–1069
- 51 Popp AW, Isenegger J, Buergi EM, Buergi U, Lippuner K. Glucocorticoid-induced spinal osteoporosis: scientific update on pathophysiology and treatment. *Eur Spine J* 2006;15(07):1035–1049
- 52 Lemke DM. Vertebroplasty and kyphoplasty for treatment of painful osteoporotic compression fractures. *J Am Acad Nurse Pract* 2005;17(07):268–276
- 53 Laredo JD, Hamze B. Complications of percutaneous vertebroplasty and their prevention. *Semin Ultrasound CT MR* 2005;26(02):65–80
- 54 Cotten A, Dewatre F, Cortet B, et al. Percutaneous vertebroplasty for osteolytic metastases and myeloma: effects of the percentage of lesion filling and the leakage of methyl methacrylate at clinical follow-up. *Radiology* 1996;200(02):525–530
- 55 Ratliff J, Nguyen T, Heiss J. Root and spinal cord compression from methylmethacrylate vertebroplasty. *Spine* 2001;26(13):E300–E302
- 56 Lopes NM, Lopes VK. Paraplegia complicating percutaneous vertebroplasty for osteoporotic vertebral fracture: case report. *Arq Neuropsiquiatr* 2004;62(3B):879–881
- 57 Chiras J, Depriester C, Weill A, Sola-Martinez MT, Deramond H. [Percutaneous vertebral surgery. Technics and indications]. *J Neuroradiol* 1997;24(01):45–59
- 58 Syed MI, Jan S, Patel NA, Shaikh A, Marsh RA, Stewart RV. Fatal fat embolism after vertebroplasty: identification of the high-risk patient. *AJNR Am J Neuroradiol* 2006;27(02):343–345
- 59 Yoo KY, Jeong SW, Yoon W, Lee J. Acute respiratory distress syndrome associated with pulmonary cement embolism following percutaneous vertebroplasty with polymethylmethacrylate. *Spine* 2004;29(14):E294–E297
- 60 Jang JS, Lee SH, Jung SK. Pulmonary embolism of polymethylmethacrylate after percutaneous vertebroplasty: a report of three cases. *Spine* 2002;27(19):E416–E418
- 61 Kim SY, Seo JB, Do KH, Lee JS, Song KS, Lim TH. Cardiac perforation caused by acrylic cement: a rare complication of percutaneous vertebroplasty. *AJR Am J Roentgenol* 2005;185(05):1245–1247
- 62 Edmonds CR, Barbut D, Hager D, Sharrock NE. Intraoperative cerebral arterial embolization during total hip arthroplasty. *Anesthesiology* 2000;93(02):315–318
- 63 Xiao H, Yang J, Feng X, et al. Comparing complications of vertebroplasty and kyphoplasty for treating osteoporotic vertebral compression fractures: a meta-analysis of the randomized and non-randomized controlled studies. *Eur J Orthop Surg Traumatol* 2015;25(Suppl 1):S77–S85