

# Case Series on Perforator Aneurysm: Endovascular Stenting—A Safe Strategy

Chandra Dev Sahu<sup>1</sup> Ashish Ashpilaya<sup>1</sup>

<sup>1</sup>Department of Radiodiagnosis, Pt. Jawahar Lal Nehru Memorial Medical College & Dr. Bhim Rao Ambedkar Hospital, Raipur, Chhattisgarh, India

Address for correspondence Ashish Ashpilaya, MD, H. No. 20/320, Station Road, Raipur 492001, Chhattisgarh, India (e-mail: drashishashpilaya@gmail.com).

J Clin Interv Radiol ISVIR 2017;1:179–183.

## Abstract

Perforator aneurysms are rare vascular lesions that are infrequently reported in literature, and because of difficult anatomic approach, their treatment and management pose challenges. Given the rarity of these aneurysms, the natural history and ideal approach to treatment has not been established. The authors retrospectively analyzed six patients, age ranging from 16 to 75 years with ruptured perforator aneurysm, four of posterior circulation and two of anterior circulation including clinical characteristics, imaging data, treatment regimen, and outcome. All but two patients presented with the World Federation of Neurosurgical Societies grades I to III and Fisher grade 2 or 3 subarachnoid hemorrhage, and the other two presented with intracerebral bleed in the right gangliocapsular region. Four patients were managed conservatively whereas two basilar perforator aneurysms were treated with endovascular stent. At the last follow-up, the endovascularly treated group of patients demonstrated complete thrombosis of aneurysm with preservation of perforators, and the conservatively managed group showed spontaneous occlusion in one patient, whereas three were lost to follow-up and ultimate outcome remains unknown. The authors report single-center hospital-based experience in six patients, which adds to the scarce published literature that addresses the limited understanding of the natural course and consolidating safe endovascular management of this entity.

## Keywords

- ▶ basilar perforator aneurysm
- ▶ endovascular stenting
- ▶ lenticulostriate perforator

## Introduction

Perforator aneurysms arise from the perforating branches of major vessels of cerebral circulation. They are an exceedingly rare entity but are detected on clinical imaging for diffuse or perimesencephalic/prepontine subarachnoid hemorrhage (SAH) or as intracerebral hemorrhage. The first case of perforator aneurysm was described by Ghogawala et al<sup>1</sup> in 1996, and since then 20 cases of basilar perforator and 50 cases of lenticulostriate perforators have been reported worldwide. Although exact etiopathogenesis is not known, arterial hypertension and intracranial dissection pathology have been denoted as inciting causes for its development. Clinical presentation of ruptured perforator aneurysm is similar to any other aneurysm manifesting as severe thunder

clap headache and unconsciousness with or without motor deficit. Diagnosis of perforator aneurysm poses a serious challenge due to low flow in perforating arteries, which adequately explains the diagnostic difficulty in computed tomographic (CT) angiography and even on initial catheter angiogram. In case of an acute ruptured basilar artery perforator aneurysm (BAPA), there is uncertainty concerning the therapeutic management. The approach to the anatomic site is challenging both for clipping and coiling due to the retrobasilar location and tiny diameter of the perforators.<sup>2,3</sup> Hence, therapeutic attempts are risky and may fail. Till date, only eight cases of basilar perforators have been described in the literature with endovascular treatment by coiling or pipeline/stent placement.<sup>4</sup> The authors report their experience in six patients of perforator aneurysm; two were

received  
April 25, 2017  
accepted after revision  
July 21, 2017  
published online  
October 9, 2017

DOI <https://doi.org/10.1055/s-0037-1606374>.  
ISSN 2457-0214.

Copyright © 2017 by Indian Society of  
Vascular and Interventional Radiology

License terms



treated via endovascular stenting with satisfactory clinical outcome, and rest were managed conservatively (►Table 1).

### Endovascularly Treated Group

#### Case 1

A 50-year-old man presented in the emergency department with severe progressive headache without any neurologic deficit. The patient was conscious with Glasgow Coma Scale (GCS) 13. Noncontrast CT (NCCT) of the head demonstrated diffuse thick SAH (Fisher grade 3) along the perimesencephalic and basal cisterns extending along the bilateral sylvian fissure with effacement of sulcal spaces and moderate hydrocephalus (►Fig. 1a). CT angiogram failed to demonstrate any aneurysmal cause of SAH. Diagnostic cerebral angiography performed on the third day of ictus demonstrated 1.6-mm midbasilar perforator aneurysm on delayed arterial phase arising from left lateral wall of the basilar artery (►Fig. 1b–d). After multidisciplinary approach and on the basis of available literature, endovascular stenting was planned and performed with placement of two 4.5 × 23 mm overlapping LVIS self-expanding stents (MicroVention Terumo) from the P1 segment of the left posterior cerebral artery to the midbasilar artery with approximately 8 mm overlap across the neck of the BAPA. Repeated cerebral angiography performed on fourth day post stenting showed persistent filling of the dome of aneurysm, but its size was reduced (►Fig. 1e). The patient was discharged with GCS 15 after 2 weeks of uneventful hospital stay. Follow-up cerebral angiography performed at 3 months failed to demonstrate aneurysm (i.e., aneurysm was completely thrombosed) without evidence of stent thrombosis (►Fig. 1f).

#### Case 2

A 58-year-old hypertensive man presented with acute onset of progressively increasing severe headache since 5 days

without neurologic deficit. NCCT showed perimesencephalic and basal cistern bleed (Fisher grade 2) (►Fig. 2a). Next day cerebral angiography revealed 1.5-mm midbasilar perforator aneurysm arising from left lateral wall of the basilar artery (►Fig. 2b). The patient was planned for endovascular stenting and was placed on dual-antiplatelet therapy. A single LVIS stent (4.5 × 23 mm) was deployed in the basilar artery securing aneurysm with preservation of perforator. There was immediate thrombosis of the aneurysm. Check angiography performed 5 days later showed thrombosed aneurysm with flow preservation in the perforator (►Fig. 2c, d). Further course of hospital stay was uneventful and the patient was discharged. Follow-up angiography at 12 months showed persistent occluded aneurysm without parent artery compromise.

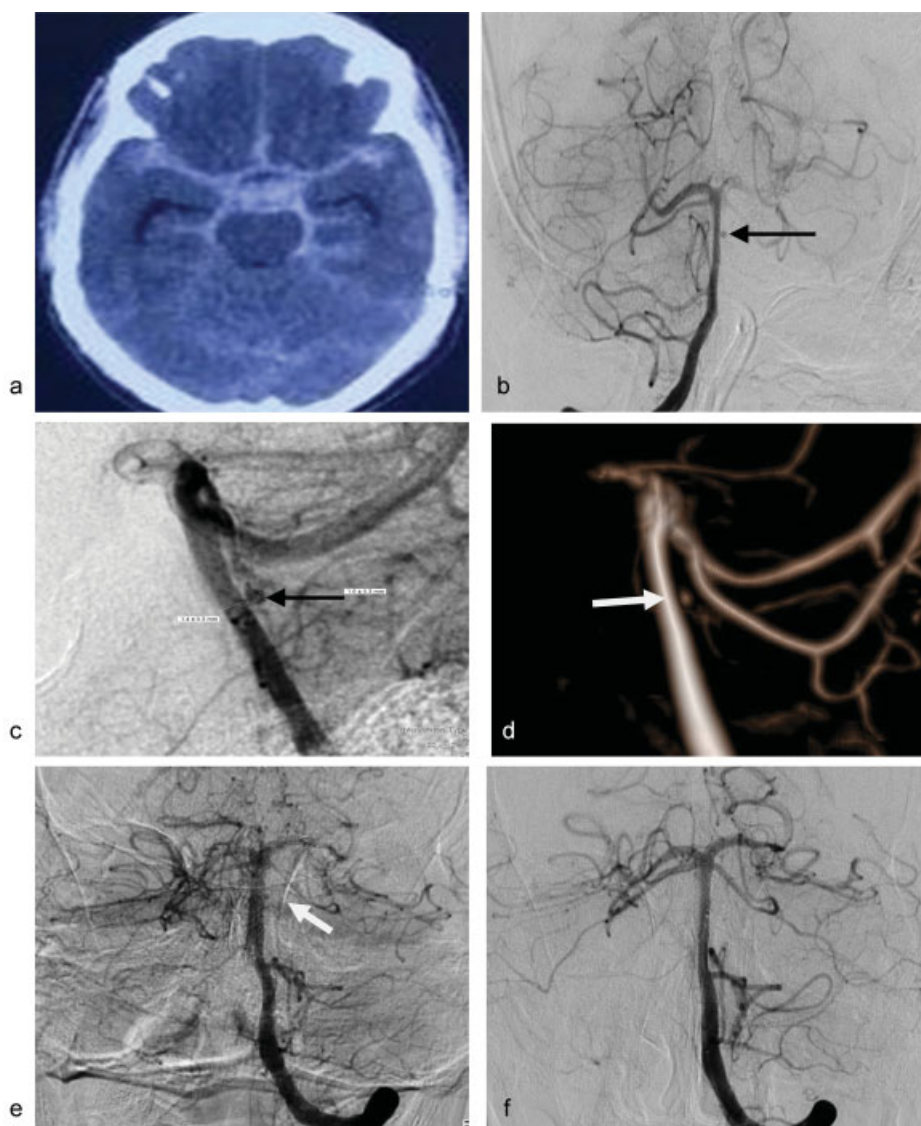
### Conservatively Managed Group

There were four patients who were managed conservatively, with age ranging from 16 to 45 years with mean age of 42. Two of them presented with Fisher grades 1 and 3 SAH in perimesencephalic and basal cistern whereas the other two presented with gangliocapsular bleed. None had significant medical past history or history of trauma. GCS of patients varied from 13 to 15. Digital subtraction angiography (DSA) performed in all these patients suspecting vascular etiology demonstrated perforator aneurysm. Both anterior circulation perforators arise from right lateral lenticulostriate artery measured less than 3 mm.

One had M1 occlusion of the right middle cerebral artery (MCA) with lenticulostriate to lenticulostriate collaterals, with a small pseudoaneurysm arising from the lenticulostriate collateral perforator. During super selective catheterization, subarachnoid leak was demonstrated from pseudoaneurysm, and further intervention was arrested considering risk of rupture and was managed conservatively.

**Table 1** Summary of six patients with ruptured perforator aneurysms

	Patient 1	Patient 2	Patient 3	Patient 4	Patient 5	Patient 6
Age/Sex	75/M	58/M	16/M	32/M	65/F	35/F
Size (mm)	1.6 mm	1.5 mm	1.5 mm	1.3 mm	1.2 mm	1.3 mm
Fisher grade	3	2	–	–	2	3
Bleed pattern	Diffuse	Diffuse	Right gangliocapsular	Right gangliocapsular	Perimesencephalic	Diffuse
Detection on angiogram	(–) initial CTA (+) angiogram on day 4 bleed	(–) initial CTA (+) angiogram on day 6 bleed	(–) initial CTA, angiogram. (+) repeat angiogram after 7 d	(–) initial CTA (+) angiogram after 2 d	(+) angiogram after 1 wk of bleed	(–) initial CTA, angiogram (+) repeat angiogram after 10 d
Origin of perforator on basilar artery	Midbasilar	rostral	Perforating branch of lenticulostriate	Perforating branch of lenticulostriate	Midbasilar	Rostral basilar
Treatment	Endovascular double stenting	Endovascular stenting	Conservative with spontaneous occlusion of aneurysm	Conservative	Conservative	Conservative
Complications	None	None	Focal seizures	Unknown	Unknown	Unknown
Follow-up	3 mo	4 mo	Spontaneous occlusion of aneurysm on day 11 of bleed	Loss to follow-up	Loss to follow-up	Loss to follow-up



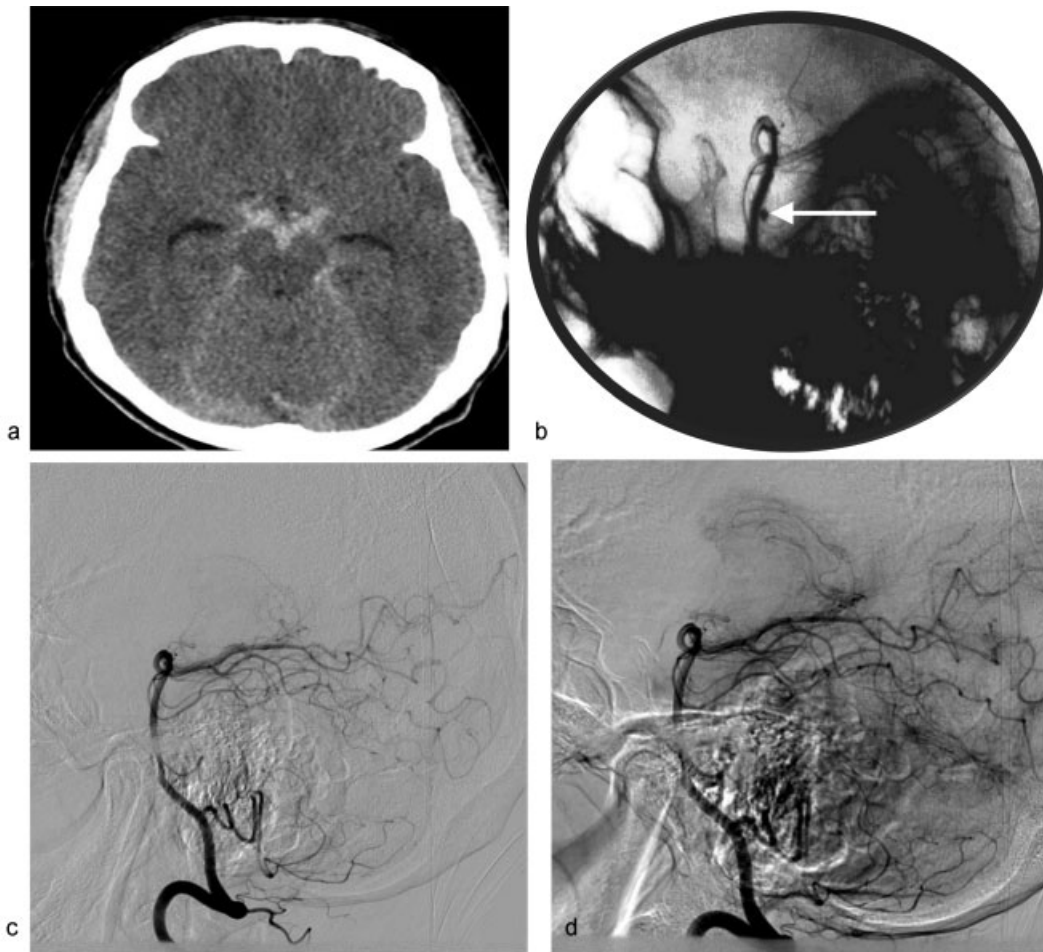
**Fig. 1** (a) NCCT of the head demonstrating Fisher grade 3 SAH. (b, c) Digital subtraction angio images in AP and lateral view showing 1.6-mm midbasilar perforator (arrow), (d) confirmed on 3D CT angio (arrow). (e) Post stenting size of aneurysm was reduced (arrow). (f) Check angio at 3 months does not demonstrate aneurysm suggesting total occlusion.

Another lenticulostriate perforator was spontaneously thrombosed on seventh day of ictus (→ Fig. 3). Both posterior circulation perforators arise from mid and rostral basilar artery segments. Both patients refused for the endovascular management, and considering size of the aneurysm to be too small, small caliber of the parent vessel, and negative initial angiography for these patients, a conservative approach was made for management of these patients. They were ultimately lost to follow-up.

## Discussion

Perforator aneurysms are rare lesions with very few reported cases. Basilar artery perforators have been stratified according to their location into caudal (2–5 in number with a diameter of 80–600  $\mu\text{m}$ ), middle (5–9 in number with diameter of 210–940  $\mu\text{m}$ ) and rostral perforators<sup>2</sup> (1–5 in number with a diameter of 190–800  $\mu\text{m}$ ). Aneurysms are

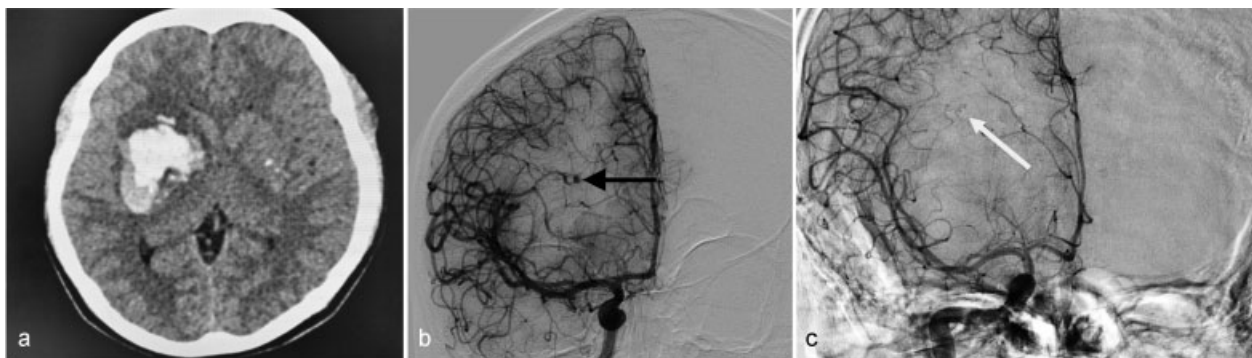
commonly associated with the middle or rostral basilar perforators. Similarly, in this series, three out of four posterior circulation aneurysms were located in rostral and one was in midbasilar perforating branches. None was found in caudal perforators. Bleeding pattern in basilar trunk perforators is variable ranging from perimesencephalic/prepontine bleed to diffuse SAH. According to the available literature, they usually measure less than 6 mm<sup>1,5,6</sup> excluding the two cases of Chen et al.<sup>7</sup> Similarly, in all these six patients, aneurysms were not larger than 3 mm. A basilar perforating aneurysm can be easily missed on CT angiography due to its small size, variable location, slow opacification, and potential for intra-aneurysm thrombus. Due to low blood flow within the parent vessel, they remain even angiographically occult for several days. In this case series, none of the perforator aneurysms was demonstrated on CT angiography and was occult by subarachnoid blood whereas two basilar and one lenticulostriate perforators were occult on first angiography



**Fig. 2** (a) NCCT of the head demonstrating Fisher grade 2 SAH. (b) Digital subtraction angiography images in lateral view showing midbasilar perforator aneurysm (arrow). (c, d) Post stenting DSA images in early and late arterial phase do not demonstrate any aneurysm.

performed within seventh day of bleed, owing to the small size of the aneurysms. These characteristics make diagnostic evaluation of perforating aneurysm a challenging task. Hence, it is important to maintain high index of suspicion for perforating aneurysms in negative or equivocal imaging studies with careful assessment of conventional angiography in the delayed capillary and venous phases. Given the rarity of these aneurysms, the natural history and ideal approach to treatment have not been established. Treatment options

traditionally considered for these uncommon lesions have included direct surgery, endovascular therapy, or conservative management. To date, there are only eight published cases of ruptured BAPAs treated using endovascular techniques. Since the advent of endovascular aneurysm treatment by Guglielmi, detachable coil embolization, and literature supporting its noninferiority to traditional microsurgical obliteration, the authors have seen a trend toward endovascular therapy, especially for aneurysms of the posterior



**Fig. 3** (a) NCCT of the head demonstrating right basal ganglia bleed. (b) Digital subtraction angiography images in AP townes view showing lenticulostriate perforator aneurysm (arrow). (c) Seventh day post ictus repeat angiography does not demonstrate any aneurysm (arrow).

circulation. Chen et al<sup>7</sup> reported on two cases with coil embolization of a ruptured aneurysm arising from the pontine circumferential artery, possibly owing to large diameter of the vessel. Direct coiling of basilar trunk perforator (BTP) aneurysms is otherwise rarely possible because it requires catheterizing exceedingly small-caliber perforators often arising at a straight angle from the basilar trunk. Moreover, the very small size of these aneurysms precludes safe coil placement. Therefore, Deshaies et al<sup>8</sup> in 2011 first performed the technique of telescoping stent for 3-mm basilar perforator after unsuccessful coil embolization. Since then, endovascular stenting has been considered in treatment regimen of basilar artery perforator that is consolidated by the reports of Nyberg et al<sup>5</sup> (2013) and Satti et al<sup>4</sup> (2017) who performed endovascular stenting in three patients, using double and triple stents. In all these cases, there was complete thrombosis of aneurysm with excellent long-term outcome. After reviewing literature, the authors found that their patients 1 and 2 are ideal candidates for endovascular stenting. The authors performed double stenting, using telescoping technique in patient 1, which showed delayed slow filling of aneurysm post stenting and complete occlusion of aneurysm on 90-day follow-up, whereas in the second patient, there was immediate occlusion of aneurysm after single stent with preserved flow in the perforator, which persisted on 4-month follow-up. There was no significant immediate or delayed neurologic complication in both these patients. Spontaneous resolution of aneurysm was observed in one patient on the 11th day post-intracerebral hemorrhage with no significant neurologic complication or rebleed, possibly owing to small size of aneurysm (< 2 mm) supported by the evidence from the case report of Chavent et al.<sup>9</sup>

## Conclusion

The authors report their single-center hospital-based experience in six cases of perforator aneurysm of both anterior

and posterior circulation, which are rare causes of SAH. Their diagnosis and management poses great challenge notably due to their small size and slow filling and unusual location. Based on the authors' experience, endovascular treatment of these lesions has proved to be extremely challenging with successful stent placement achieved without any significant morbidity. Conservative management has demonstrated that, in cases, spontaneous thrombosis and resolution does occur. However, because the natural history and course of perforator artery aneurysms remain unknown, the management of these entities should be performed on an individual basis weighing the risk and possible clinical outcome.

## References

- 1 Ghogawala Z, Shumacher JM, Ogilvy CS. Distal basilar perforator artery aneurysm: case report. *Neurosurgery* 1996;39(02):393–396
- 2 Marinković SV, Gibo H. The surgical anatomy of the perforating branches of the basilar artery. *Neurosurgery* 1993;33(01):80–87
- 3 Caruso G, Vincentelli F, Giudicelli G, Grisoli F, Xu T, Gouaze A. Perforating branches of the basilar bifurcation. *J Neurosurg* 1990;73(02):259–265
- 4 Satti SR, Vance AZ, Fowler D, Farmah AV, Sivapatham T. Basilar artery perforator aneurysms (BAPAs): review of the literature and classification. *J NeuroInterv Surg* 2017;9(07):669–673
- 5 Nyberg EM, Chaudry MI, Turk AS, Spiotta AM, Fiorella D, Turner RD. Report of two cases of a rare cause of subarachnoid hemorrhage including unusual presentation and an emerging and effective treatment option. *J Neurointerv Surg* 2013;5(05):e30
- 6 Ding D, Starke RM, Jensen ME, Evans AJ, Kassell NF, Liu KC. Perforator aneurysms of the posterior circulation: case series and review of the literature. *J Neurointerv Surg* 2013;5(06):546–551
- 7 Chen L, Chen E, Chotai S, Tian X. An endovascular approach to ruptured aneurysms of the circumferential branch of the basilar artery. *J Clin Neurosci* 2012;19(04):527–531
- 8 Deshaies EMJW, Krishnamurthy S. Enterprise stent-within-stent embolization of a basilar artery perforator aneurysm. *World J Neurosci* 2011;1:45–48
- 9 Chavent A, Lefèvre PH, Thouant P, et al. Spontaneous resolution of perforator aneurysms of the posterior circulation. *J Neurosurg* 2014;121:1107–1111