Chronic Subdural Hematoma Surgical Evacuation with Burr-Hole Drainage: An Institutional Experience

Yogesh Agrawal[1] Ashok Gupta[1] Virendra Deo Sinha[1]

[1]Department of Neurosurgery, Sawai Man Singh Medical College and Hospital, Jaipur, Rajasthan, India

Address for correspondence Dr. Yogesh Agrawal, MBBS, MS, MCh, Department of Neurosurgery, Mahatma Gandhi Medical College and Hospital, RIICO Industrial Area, Sitapura, Jaipur, Rajasthan 302004, India (e-mail: agrawaly_2k@yahoo.co.in).

Indian J Neurotrauma 2017;14:59–64

Abstract

Background Chronic SDH (CSDH) is one of the most common clinical entities in neurosurgery with most favorable prognosis commonly encountered in elderly patients with history of minor trauma and surgery is gold standard treatment.

Objectives This study was done to evaluate the clinical presentation, radiologic findings, complications, and management of patients with CSDH who were treated surgically with burr-hole evacuation.

Materials and Methods This prospective study was done in Department of Neurosurgery, SMS Medical College, Jaipur, India, from September 2015 to April 2016. The sample size was 55.

Results In this study out of 55 patients, 39 (71%) patients were male and 16 (29%) were female. The most common age group in which CSDH observed was between 61 and 70 years. Most common presenting symptom was headache present in 30 (54.55%) patients followed by weakness. Midline shift more than 5 mm was seen in 43 (78%) patients. The most common complication was recurrence of CSDH (5.4%) in our study. Recurrence after single burr hole was 16.6% and 4.1% after double burr holes. Simple pneumocephalus was present in almost all cases and tension pneumocephalus was found in one (1.8%) patient.

Conclusion Complete evacuation of unilateral CSDH by two burr holes at highest point of hematoma is sufficient. Factors affecting recurrence rate include old age, gross midline shift, and single burr hole. Postoperative simple pneumocephalus is a common radiologic finding that requires no treatment and it does not affect ultimate outcome. Tension pneumocephalus is a serious complication requiring emergent treatment.

Keywords
- chronic subdural hematoma
- burr-hole evacuation
- tension pneumocephalus

Introduction

Chronic subdural hematoma (CSDH) is defined as fluid collection within the layer of the dura. The annual reported incidence of CSDH is approximately 0.001 to 0.002%.[1] Patients older than 40 years account for 80% of cases. Trauma is probably the most important risk factor for the development of CSDH, with two-thirds of CSDH patients remembering some type of minor trauma. Other risk factors include seizures, dehydration, brain atrophy, degenerative brain disease, cerebrospinal fluid (CSF) shunting, lumbar puncture, spinal anesthesia, chronic alcoholism, primary coagulopathy in children, and neurosurgical treatment involving opening of subarachnoid space. Surgical treatment of CSDH in symptomatic patients is the "gold standard" of therapy. The principal techniques used for the surgical treatment of CSDH include twist drill craniostomy (TDC), burr-hole craniostomy (BHC), and craniotomy. BHC and craniotomy are the most efficacious

received
November 7, 2016
accepted
June 15, 2017

DOI https://doi.org/10.1055/s-0037-1606210.
ISSN 0973-0508.

techniques and provide the lowest recurrence rates.[2] CSDHs are commonly associated with cerebral atrophy, and this factor of associated increase in potential space in the subdural area helps in air collection after surgery.[3] Presence of air in the cranial cavity is termed as "pneumocephalus." It is commonly encountered after surgical evacuation of CSDH. Two types of pneumocephalus exist: simple and tension. Simple pneumocephalus is typically asymptomatic and requires no treatment. Tension pneumocephalus (TP) refers to air collection under pressure and requires an emergent management.[4]

Material and Method

In SMS Medical College and Hospital, Jaipur, India, from September 2015 to April 2016, this prospective study was performed on 55 patients who were treated surgically for chronic subdural hematoma through cranial burr holes. In all cases, computed tomographic (CT) scan was performed to evaluate the location of CSDH and degree of midline shift if present. Surgery was done under local anesthesia in all patients and surgical procedure included BHC (single or double). The hematoma was approached over the thickest part and evacuation of the subdural collection was done by dural and hematoma membrane incision followed by repeated saline irrigation until clear fluid came out in all the cases. Thus the uniformity of the surgical procedure was maintained. Postoperatively patients were kept in head-low position for 48 hours and were adequately hydrated with intravenous (IV) fluids for 2 to 3 days to promote expansion of the brain. All patients underwent postoperative CT scan after 24 hours and follow-up CT scan 1 month after surgery. Patients with no complications were discharged between sixth and eighth postoperative days and follow-up after 1 month period. The neurologic grading system presented by Markwalder et al,[5] was used to evaluate the surgical results on admission and immediate postoperative period and after 1 month. Good pre- and postoperative results were considered in patients graded 0–2 and bad pre- and postoperative results were considered in patients graded 3–4.

Results

In this study out of 55 patients, 39 (71%) were male and 16 (29%) were female, with age ranging from 25 to 86 years (►**Table 1**).The most common age group comprising 18 (32.7%) patients in whom CSDH was observed was between 61 and 70 years, followed by 41 to 50 years comprising 10 patients (18.18%). History of head injury was present in 47 (85%) patients. Most head injuries were minor trauma without loss of consciousness. Preoperative midline shift of 11 to 15 mm was found in 32 (58.1%) patients, 6 to 10 mm in 8 (14.5%), more than 16 mm in 3 (5.4%), and less than 5 mm in 12 patients. Total 43 (78%) patients had midline shift of more than 5 mm. There was higher incidence of CSDH in the patients older than 40 years as well as in those presenting with a midline shift of more than 5 mm. The most common presenting symptom was headache in 30 (54.55%) patients followed by weakness in 25 (45.45%) patients, right side in 9 (16.3%) patients, left side in 9 (16.3%) patients, and bilateral (b/l) in 7 (12.73%) patients. The next most common presenting symptom was altered sensorium (►**Table 2**). Other symptoms included vesicular eruption, urinary incontinence, and bloody vomits presented in 7 (12.7%) patients. The most common complication observed was recurrence of CSDH that was 5.4% (three patients). One patient developed early postoperative seizure. One patient had cerebral infarction in posterior cerebral artery (PCA) territory and one had phenytoin toxicity. One patient died of multiorgan failure. Some amount of intracranial air (simple pneumocephalus) was observed in postoperative CT scan of all cases (►**Figs. 1, 2**) and TP was seen in one (1.8%) patient (►**Fig. 3**).

All cases of simple pneumocephalus did not show any neurologic deterioration and did not require any specific treatment. One case of TP was a woman of age 67 years with b/l frontotemporoparietal CSDH that showed improvement in immediate postoperative period followed by progressive deterioration in the conscious level with right-side weakness, and her CT scan revealed Mount Fuji sign. Reopening of wound to evacuate the air with saline irrigation was done. The patient responded well and improved clinically in immediate postoperative period.

As per grading by Markwalder et al (►**Table 3**), in preoperative period the authors had 46 (83.6%) patients between grades 0 and 2. Nine (16.3%) patients were between grades 3 and 4. Postoperative grading with the same system showed bad postoperative results in 8 (14.5%) patients between

Table 1 Age of patients with CSDH

Year	No. of patients (%)
21–30	3 (5.4)
31–40	5 (9.0)
41–50	10 (18.18)
51–60	7 (12.7)
61–70	18 (32.7)
71–80	7 (12.7)
> 80	5 (9.0)

Abbreviation: CSDH, chronic subdural hematoma.

Table 2 Presentation at the time of admission

Name	Count	Percentage
Headache	30	54.55
Weakness	25	45.45
Altered sensorium	21	38.18
Vomiting	17	30.91
Loss of consciousness (LOC)	8	14.55
Others	7	12.93
Giddiness	6	10.91
Forgetfulness	4	7.27
Seizure	4	7.27
Fever	3	5.45

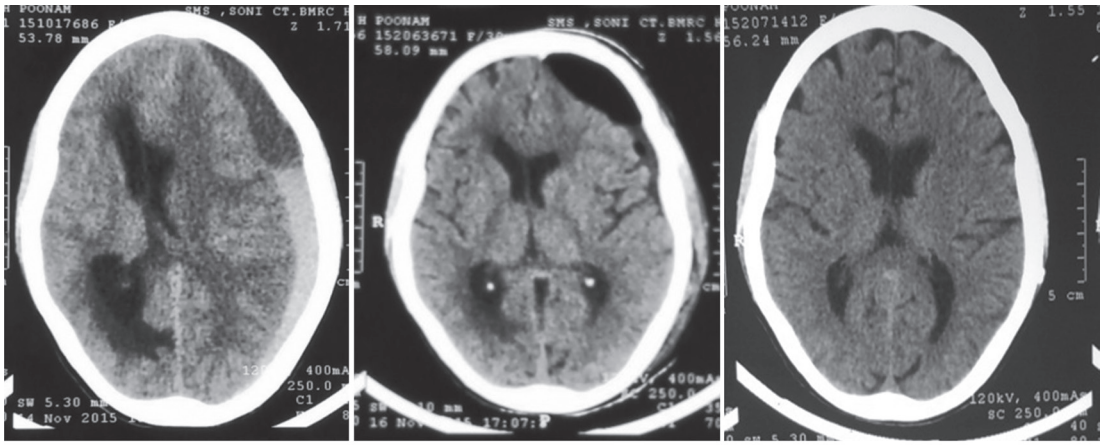

A B C

Fig. 1 Plain axial CT scan of a 32-year-old female patient. (**A**) Preoperative image showing chronic subdural hematoma with subacute component in left frontotemporoparietal (FTP) region with midline shift. (**B**) Immediate postoperative image showing pneumocephalus in left frontal region. (**C**) One month after surgery no hematoma, pneumocephalus was resolved and brain expanded.

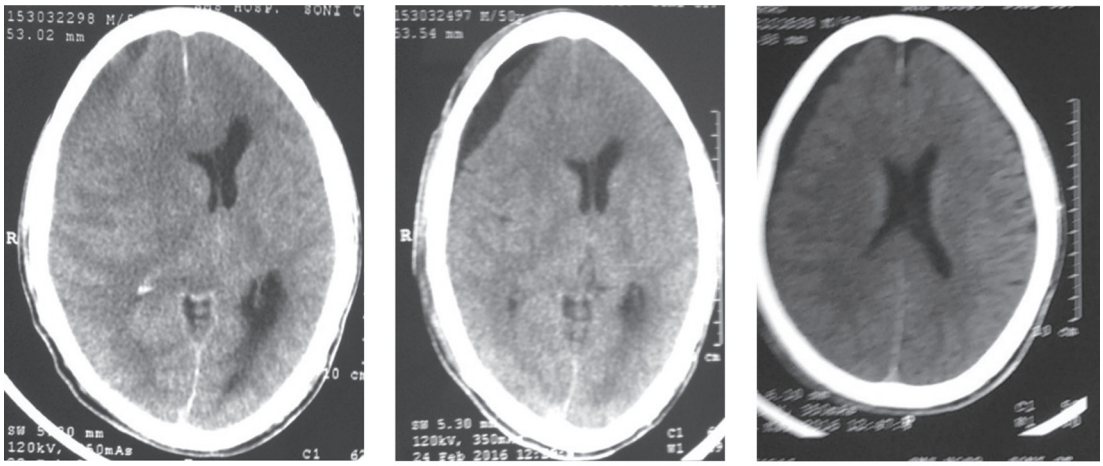

A B C

Fig. 2 Plain axial CT scan of a 52-year-old man. (**A**) Preoperative image showing CSDH in right FTP region with midline shift. (**B**) Immediate postoperative image showing pneumocephalus in right frontal region. (**C**) One month after surgery, image showing no midline shift and pneumocephalus was spontaneously resolved.

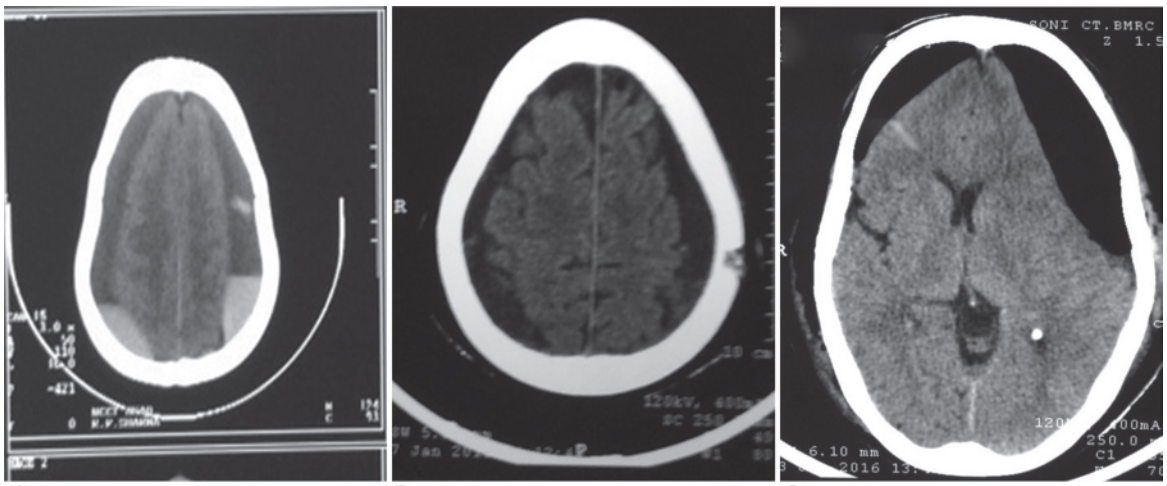

A B C

Fig. 3 Plain axial CT scan of a 67-year-old female patient. (**A**) Preoperative image showing chronic subdural hematoma in bilateral FTP region with small acute component. (**B**) Immediate postoperative image after burr hole craniostomy showing no hematoma brain surface not expanded. (**C**) After 6 days of surgery when pt neurologically deteriorate image showing Mount Fuji sign.

Table 3 The neurologic grading system of Markwalder et al

0—Patient neurologically normal
1—Patient alert and oriented, mild symptoms such as headache, absent or mild neurologic deficits such as reflex asymmetry
2—Patient drowsy or disoriented with variable neurologic deficits such as hemiparesis
3—Patient stuporous but responding appropriately to noxious stimuli, severe focal signs such as hemiplegia
4—Patient comatose with absent motor responses to painful stimuli, decerebrate or decorticate posturing

grades 3 and 4. Three patients had recurrence and neurologic deficit not recovered. One patient died and one patient had TP. Good postoperative results were found in 47 (85.4%) patients between grades 0 and 2. One month after burr-hole evacuation, 50 (90.9%) patients showed good recovery that was in grades 0 to 2 and 4 (7.27%) patients had poor outcome that was in grades 3 to 4, as per grading by Markwalder et al (►**Table 4**). One patient died that was grade 3 before surgery.

Discussion

CSDH represents one of the most frequent types of intracranial hemorrhage with a favorable prognosis when treated adequately.[6] The etiology of CSDH is not completely understood. Traumatic subdural effusion is widely accepted as preliminary stage in development of CSDH.[7,8] Traumatic subdural effusion is a result of arachnoid tearing caused by head injury or neurosurgery, and this fluid with or without blood in the subdural space facilitates formation of so-called outer membrane. Bleeding occurs repeatedly from capillaries with degenerative endothelium, and it is accompanied by local hyperfibrinolysis, which is one of the causes of the effusion of CSDH.[9]

CSDH commonly occurs in elderly people because of brain atrophy that causes enlargement of subarachnoid space and stretching of bridging veins, which facilitates tearing of arachnoid membrane and leakage of bloody CSF after mild head injury.[5] A definite history of head injury was present in 47 (85.45%) cases.

In this study, peak incidence of CSDH was seen in 61 to 70 age group (32.70%) and 85.45% of patients were older than 40 years. Age is also generally thought to be a strong predictor of prognosis, and most studies have shown worse prognosis in patients with increasing age.[10]

In the present study, males were 39 (71%). The male preponderance may be due to the following: (1) men are more likely to suffer head injury than women; (2) fewer females seek medical advice; and (3) estrogen and their derivatives may have a protective effect on the capillaries.[11]

Table 4 Clinical grade and outcome according to Markwalder neurologic grading

Outcome	Preoperative	Postoperative	After 1 month[a]
0–2 (good)	46 (83.6%)	47 (85.4%)	50 (90.9%)
3–4 (poor)	9 (16.3%)	8 (14.5%)	4 (7.27%)

[a]One patient died in postoperative period.

Among the three common surgical methods, BHC shares the advantages over TDC. BHC has a high cure rate, safety, less recurrence, and better outcome with lower reoperation rate than craniotomy. It can be performed under local anesthesia.[2] It takes shorter operation time and is less invasive than the other two, but it is often less efficient to evacuate the hematoma, especially in cases of separated type of CSDH or thick hematoma.[12] In this study overall recurrence rate is 5.45%, recurrence after single burr hole was 16.6% in one out of six patients, and recurrence after two burr holes was 4.08% in two out of 49 patients. A large comparison group is required to determine whether it is significant or not, and in our study, sample size was not adequate in case of single burr hole, but reported incidence of recurrence in literature was 7 to 18% after one BHC.

In this study, drain was not used in any case, and rate of recurrence in this series was 5.4%, which equals to rates reported by other authors.[13] There is no consensus in the literature regarding the superiority of drain. Markwalder and Seiler[14] described no additional benefit with subdural drain. Erol et al[15] and Hamilton et al[16] reported no significant difference in recurrence rate between simple BHC with irrigation and BHC with closed system drainage.

The pathogenesis and recurrence of CSDH have been controversial for more than a century and it still remains obscure. The most widely accepted theory is that it is the result of repeated bleeding from the outer membranes of the hematoma. Many causes for the repeated bleeding are explained.[17–20] observed infiltration of eosinophils in the vascularized and hynalized granulation tissue of the subdural membrane. Yamashima[17] postulated that the eosinophils in the outer membrane may contribute to the development of local hyperfibrinolysis and recurrent subdural bleedings.

Mere removal of CSDH, although leaving the entire outer membrane intact, is almost always effective. Weir[21] proposed that the removal of CSDH brings about hemostasis and fibrosis by stopping the self-perpetuating cycles in the subdural neo-capillaries by removal of hemorrhagic fluid that probably contains anticlotting factors.

Pneumocephalus is common after intracranial surgery and trauma. It is commonly encountered after surgical evacuation of CSDH. Although simple pneumocephalus is typically asymptomatic, TP is a rare neurosurgical emergency; if not diagnosed early and treated properly, it can be fatal. As little as 25 mL of air can cause TP.[22] In this study some amount of air was present in all cases in immediate postoperative CT scans, and clinically these cases were asymptomatic. This air was resolved in all 1-month follow-up CT scans. In the study by Zidan Ihab, recurrence of CSDH was observed in nine (18%) patients and pneumocephalus was a common finding in recurrent cases found in seven out of nine patients.[1] Similarly, in the series by Zakaraia et al,[23] in the patients with pneumocephalus, recurrence rate was 7.3%, whereas in patients without pneumocephalus, it was 4.9%. Their study

indicated that there was a slight increase in the recurrence rate in patients with pneumocephalus. The difference in the outcome between the two groups was not statistically significant. Recurrence rate (5.45%) in this study comparable to that of other studies without pneumocephalus shows no significant increase in recurrence with presence of simple pneumocephalus.

In this series, TP was present in one (1.8%) case. Reported incidence in the literature is 0 to 16.[24–26] Clinical presentation of TP in this case included decreased consciousness, hemiparesis, and headache with progressive neurologic deterioration in postoperative period. On the CT scan, Mount Fuji sign was present. Mount Fuji sign seen on the CT occurs when the subdural air separates and compresses the frontal lobes, creating a widened interhemispheric space between the tips of the frontal lobes, which mimics the silhouette of Mount Fuji. The characteristic separation of the tips of the frontal lobes indicates that the tension of the air exceeds the surface tension of the CSF between the frontal lobes.[27–29] Mount Fuji sign alone in not considered a diagnosis of TP. Pop et al[30] proposed "peaking sign" as another sign of TP. Ishiwata et al[31] identified "air bubble sign" as a sign of TP (the presence of multiple small air bubbles scattered through several cisterns). Diagnosis of TP was based on clinical and radiologic finding. For treatment, reopening of the wound with evacuation of air and saline irrigation was done. The patient showed clinical improvement in postoperative period.

Conclusion

Complete evacuation of unilateral CSDH by two burr holes at highest point of hematoma is sufficient. Factors affecting recurrence rate include old age, gross midline shift, and single burr hole. Postoperative simple pneumocephalus is a common radiologic finding that is clinically asymptomatic and requires no treatment. TP is a serious complication that requires emergent treatment.

References

1 Ihab Z. Pneumocephalus after surgical evacuation of chronic subdural hematoma: is it a serious complication? Asian J Neurosurg 2012;7(2):66–74
2 Richard Winn H. Youmans Neurological Surgery. 6th ed. Amsterdam, The Netherlands: Elsevier Saunders; 2011: 532–536
3 Miele VJ, Sadrolhefazi A, Bailes JE. Influence of head position on the effectiveness of twist drill craniostomy for chronic subdural hematoma. Surg Neurol 2005;63(5):420–423, discussion 423
4 Schirmer CM, Heilman CB, Bhardwaj A. Pneumocephalus: case illustrations and review. Neurocrit Care 2010;13(1):152–158
5 Markwalder TM. Chronic subdural hematomas: a review. J Neurosurg 1981;54(5):637–645
6 Gelabert-González M, Iglesias-Pais M, García-Allut A, Martínez-Rumbo R. Chronic subdural haematoma: surgical treatment and outcome in 1000 cases. Clin Neurol Neurosurg 2005;107(3):223–229
7 Murata K. Chronic subdural haematoma be preceded by persistent traumatic subdural effusion. Neurol Med Chir (Tokyo) 1993;33:691–696
8 Ohno K, Suzuki R, Masaoka H, Matsushima Y, Inaba Y, Monma S. Chronic subdural haematoma preceded by persistent traumatic subdural fluid collection. J Neurol Neurosurg Psychiatry 1987;50(12):1694–1697
9 Mori K, Maeda M. Surgical treatment of chronic subdural hematoma in 500 consecutive cases: clinical characteristics, surgical outcome, complications, and recurrence rate. Neurol Med Chir (Tokyo) 2001;41(8):371–381
10 Delgado PD, Cogolludo FJ, Mateo O, Cancela P, García R, Carrillo R. [Early prognosis in chronic subdural hematomas. Multivariate analysis of 137 cases] [n Spanish] Rev Neurol 2000;30(9):811–817
11 Sambasivan M. An overview of chronic subdural hematoma: experience with 2300 cases. Surg Neurol 1997;47(5):418–422
12 Han H-J, Park C-W, Kim E-Y, Yoo CJ, Kim YB, Kim WK. One vs. two burr hole craniostomy in surgical treatment of chronic subdural hematoma. J Korean Neurosurg Soc 2009;46(2): 87–92
13 Gurunathan J. Treatment of chronic subdural hematoma with burr-hole craniostomy and irrigation. Indian J Neurotrauma 2005;2(2):127–130
14 Markwalder TM, Seiler RW. Chronic subdural hematomas: to drain or not to drain? Neurosurgery 1985;16(2):185–188
15 Erol FS, Topsakal C, Faik Ozveren M, Kaplan M, Tiftikci MT. Irrigation vs. closed drainage in the treatment of chronic subdural hematoma. J Clin Neurosci 2005;12(3):261–263
16 Hamilton MG, Frizzell JB, Tranmer BI. Chronic subdural hematoma: the role for craniotomy reevaluated. Neurosurgery 1993;33(1):67–72
17 Yamashima T. The inner membrane of chronic subdural hematomas: pathology and pathophysiology. Neurosurg Clin N Am 2000;11(3):413–424
18 Murakami H, Hirose Y, Sagoh M, et al. Why do chronic subdural hematomas continue to grow slowly and not coagulate? Role of thrombomodulin in the mechanism. J Neurosurg 2002;96(5):877–884
19 Sarkar C, Lakhtakia R, Gill SS, Sharma MC, Mahapatra AK, Mehta VS. Chronic subdural haematoma and the enigmatic eosinophil. Acta Neurochir (Wien) 2002;144(10):983–988, discussion 988
20 Lee KS. Natural history of chronic subdural haematoma. Brain Inj 2004;18(4):351–358
21 Weir B. Oncotic pressure of subdural fluids. J Neurosurg 1980;53(4):512–515
22 Shaikh N, Masood I, Hanssens Y, Louon A, Hafiz A. Tension pneumocephalus as complication of burr-hole drainage of chronic subdural hematoma: a case report. Surg Neurol Int 2010;1:27
23 Zakaraia AM, Adnan JS, Haspani MS, Naing NN, Abdullah JM. Outcome of 2 different types of operative techniques practiced for chronic subdural hematoma in Malaysia: an analysis. Surg Neurol 2008;69(6):608–615, discussion 616
24 Thapa A, Agrawal B. Mount Fuji sign in tension pneumocephalus. Indian J Neurotrauma. 2009;6:161–162
25 Caron JL, Worthington C, Bertrand G. Tension pneumocephalus after evacuation of chronic subdural hematoma and subsequent treatment with continuous lumbar subarachnoid infusion and craniostomy drainage. Neurosurgery 1985;16(1):107–110
26 Lavano A, Benvenuti D, Volpentesta G, et al. Symptomatic tension pneumocephalus after evacuation of chronic subdural haematoma: report of seven cases. Clin Neurol Neurosurg 1990;92(1):35–41
27 Hong W, Yoo C, Park C, Lee S. Two cases of delay tension pneumocephalus. J Korean Neurosurg Soc 2005;37:59–62
28 Eltorai IM, Montroy RE, Kaplan SL, Ho WH. Pneumocephalus secondary to cerebrospinal fluid leak associated with a lumbar pressure ulcer in a man with paraplegia. J Spinal Cord Med 2003;26(3):262–269

29 Yamashita S, Tsuchimochi W, Yonekawa T, Kyoraku I, Shiomi K, Nakazato M. The Mount Fuji sign on MRI. Intern Med 2009;48(17):1567–1568
30 Pop PM, Thompson JR, Zinke DE, Hasso AN, Hinshaw DB. Tension pneumocephalus. J Comput Assist Tomogr 1982;6(5): 894–901
31 Ishiwata Y, Fujitsu K, Sekino T, et al. Subdural tension pneumocephalus following surgery for chronic subdural hematoma. J Neurosurg 1988;68(1):58–61