Pedicled Temporalis Fascia Graft to Repair the Dural Defect in a Case of Compound Depressed Fracture

Amit Agrawal[1] Ranjan Kumar Jena[1] Yashawanth Sandeep[1] Ninad Nareschandra Shrikhande [1]

[1]Department of Neurosurgery, Narayana Medical College Hospital, Chinthareddypalem, Nellore, Andhra Pradesh, India

Address for correspondence Dr. Amit Agrawal, MCh, Department of Neurosurgery, Narayana Medical College Hospital, Chinthareddypalem, Nellore 524003, Andhra Pradesh, India (e-mail: dramitagrawal@gmail.com; dramit_in@yahoo.com).

Indian J Neurotrauma 2017;14:101–103

Gross contamination, dural tear, brain herniation, and underlying intracerebral hematoma/contusion are the indications for an emergency neurosurgical intervention in cases of compound skull fractures.[1,2] In the presence of gross contamination and tissue loss, surgical repair of the defect can be challenging.[3] In this article, we describe the use of pedicled ipsilateral temporalis fascia flap to repair a defect in the dura created by compound depressed skull fracture fragments. A 30-year-old man presented with the history of road traffic accident while he was going on the motorbike and hit by a lorry. There was no history of loss of consciousness; vomiting; seizures; or bleeding from the ear, nose, or mouth. At the time of presentation to the emergency room, the patient was conscious; alert; and oriented to time, place, and person. Glasgow coma scale (GCS) was E4, V5, M6, and pupils were bilaterally equal and reacting to light. Cranial nerve, motor, and sensory examination was normal. General, systemic, and spinal examination was normal. He had a large lacerated wound over the right side of the forehead with underlying palpable depressed fracture of the frontal bone (►**Fig. 1A**). Through the lacerated wound brain matter was coming out, and there was active bleeding from the wound. The wound was covered with sterile gauge

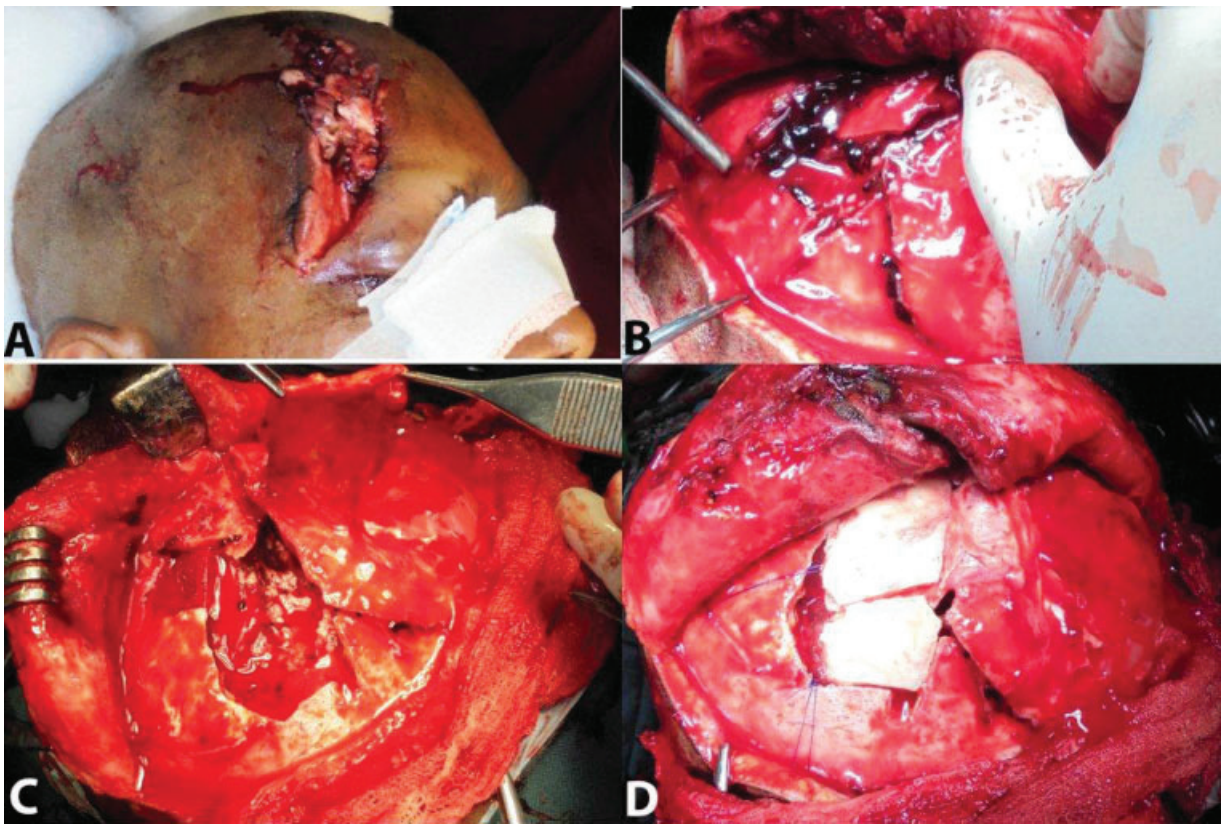

Fig. 1 (**A, B**) Clinical photograph of the patients showing open, contaminated wound with active bleeding and herniation of the brain matter. (**C**) Pedicled graft harvested from right temporal region. (**D**) Intraoperative photograph showing placement of the bone fragments.

received
September 8, 2016
accepted
June 19, 2017

DOI https://doi.org/10.1055/s-0037-1606209.
ISSN 0973-0508.

pieces to control the bleeding. The patient was shifted for the computed tomographic (CT) scan of the brain. CT scan of the brain with bone window showed a compound comminuted and depressed fracture of the right frontal bone with underlying frontal contusion (►**Fig. 2**). His blood investigations including coagulation profile were normal. The patient was taken for emergency surgery to debride the wound. Fracture fragments were exposed by a right frontal hairline incision approach extending across the midline (►**Fig. 1B**). Loose bone fragments, necrotic tissue, and underlying contused brain parenchyma were removed (►**Fig. 1C**). Wound was thoroughly irrigated with saline. To close the dural defect, a pedicled temporalis fascia graft was harvested on right side and stitched to the dural edges (►**Fig. 1C**). Large pieces of retrieved bone fragments were washed thoroughly and replaced (►**Fig. 1D**). Wound was closed in layers. The patient recovered well after surgery. Postoperative CT scan and skull radiographs showed good alignment of the bone fragments and evacuation of the cerebral contusion (►**Figs. 3, 4**).

The layered reconstruction of the skull defects (either following surgery or trauma) is essential to reduce the postoperative cerebrospinal fluid (CSF) leak and resultant morbidity and mortality.[3,4] Temporoparietal fascia or superficial temporal fascia is a thin, highly vascular layer that is supplied by the superficial temporal artery.[5,6] It is firmly attached to the overlying skin and subcutaneous tissue; however, it is relatively mobile on the temporalis muscle and can easily be separated.[7,8] Because of its versatile nature, pliability, reliable blood supply, wide arc of rotation, and availability in different sizes, temporoparietal pedicled facial flap was described to repair such defects in the head and neck region.[9–13] It has been suggested that even in the presence of gross contamination of the scalp wounds, one should perform a through debridement and repair of the defect as it helps reduce the morbidity and mortality.[1,2] To achieve the layered reconstruction, autologous pedicled temporalis fascia graft is a versatile yet simple, durable, cost-effective, efficient option to repair the dural defects.[4,9,14]

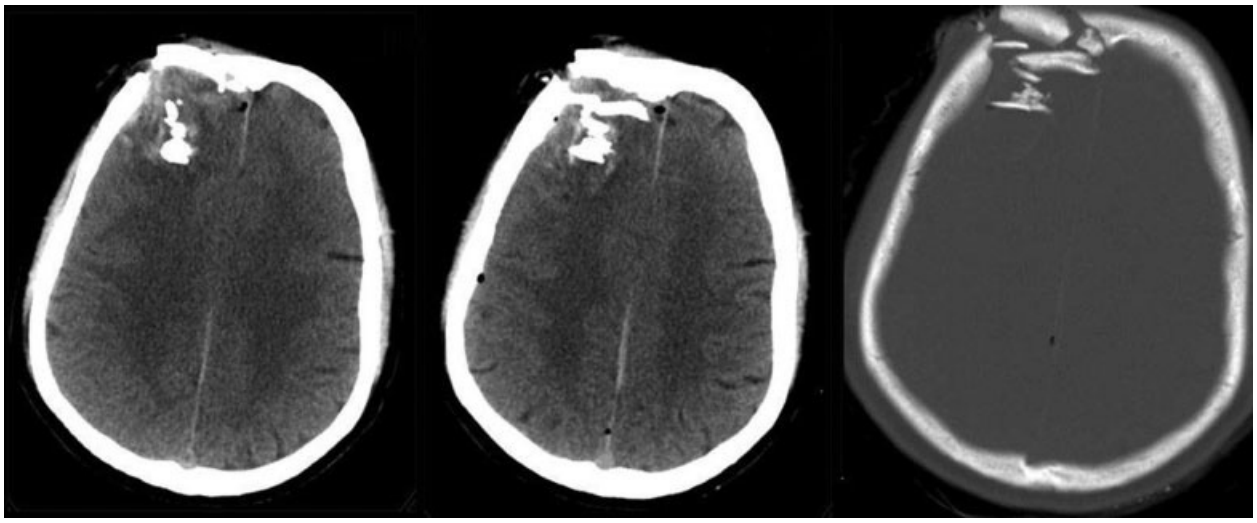

Fig. 2 Preoperative CT scan of the brain with bone window compound comminuted depressed skull fracture of right frontal bone with underlying frontal contusion. CT, computed tomography.

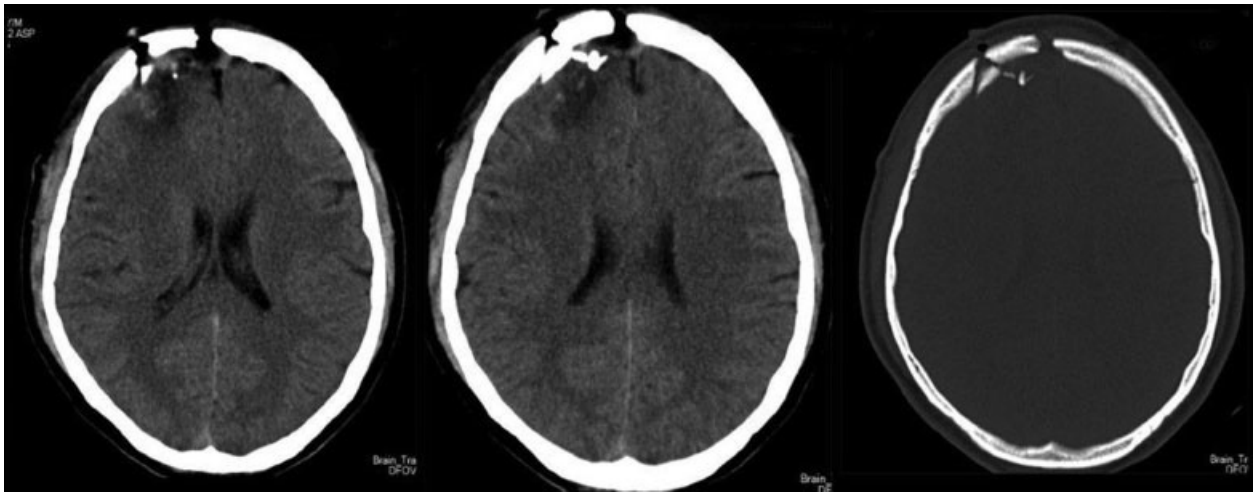

Fig. 3 Postoperative CT scan of the brain showing removal of loose bone fragments, evacuation of the contusion, and replacement of loose bone fragments. CT, computed tomography.

Fig. 4 Postoperative radiograph (AP and lateral view) showing good placement and alignment of bone fragments. AP view, anteroposterior view.

References

1 Vijaya S, Ramprasad K, Kavita K. Open skull fractures with brain function: simple principles for good outcome—our experience. Int Arch Integreated Med 2015;2(09):65–69

2 Hossain MZ, Mondle M, Hoque MM. Depressed skull fracture: outcome of surgical treatment TAJ: Journal of Teachers Association 2008;21:140–146

3 Zanetti D, Garavello W, Gaini L. Transmastoid repair of temporal meningoencephaloceles and cerebrospinal fluid otorrhea. Otorhinolaryngol Clin Int J 2011;3:31–41

4 Reinard K, Basheer A, Jones L, Standring R, Lee I, Rock J. Surgical technique for repair of complex anterior skull base defects. Surg Neurol Int 2015;6:20

5 Mokal NJ, Ghalme AN, Kothari DS, Desai M. The use of the temporoparietal fascia flap in various clinical scenarios: a review of 71 cases. Indian J Plast Surg 2013;46(03):493–501

6 Abul-Hassan HS, von Drasek Ascher G, Acland RD. Surgical anatomy and blood supply of the fascial layers of the temporal region. Plast Reconstr Surg 1986;77(01):17–28

7 Tremolada C, Candiani P, Signorini M, Vigano M, Donati L. The surgical anatomy of the subcutaneous fascial system of the scalp. Ann Plast Surg 1994;32(01):8–14

8 Tolhurst DE, Carstens MH, Greco RJ, Hurwitz DJ. The surgical anatomy of the scalp. Plast Reconstr Surg 1991;87(04):603–612, discussion 613–614

9 Siddiqua A, Joshi U, Patil SG, Thakur N. Temporoparietal fascial flap—a review. Int J Dental Clinics 2010;2(04):46–48

10 Brown WH. A form of neuralgia occurring in cyclists. BMJ 1898;1(1939):553

11 Monks GH. The restoration of a lower eyelid by a new method. Boston Med Surg J 1898;139:385–387

12 Gillies HD, Pilcher LS. Plastic surgery of the face Ann Surg 1920;72:766

13 Brent B, Byrd HS. Secondary ear reconstruction with cartilage grafts covered by axial, random, and free flaps of temporoparietal fascia. Plast Reconstr Surg 1983;72(02):141–152

14 Abuzayed B, Kafadar AM, Oğuzoğlu SA, Canbaz B, Kaynar MY. Duraplasty using autologous fascia lata reenforced by on-site pedicled muscle flap: technical note. J Craniofac Surg 2009;20(02):435–438