The Osteocutaneous Fibular Flap for Mandibular Replacement—Which Factors Influence Long-Term Success?

Andreas Kolk, MD, DDS[1] S. Haidari, MD, DDS[1] K.-D. Wolff, MD, DDS[1] A. M. Fichter, MD, DDS[1] V. Kehl, MSc[2] C. Götz, MD, DDS[1] M. R. Kesting, MD, DDS[1] J. Weitz, MD, DDS[1]

[1] Department of Oral and Maxillofacial Surgery, Technical University of Munich, Munich, Germany
[2] Department of Medical Statistics and Epidemiology, Technical University of Munich, Munich, Germany

Address for correspondence Andreas Kolk, MD, DDS, Department of Oral and Maxillofacial Surgery, Technical University of Munich, Klinikum rechts der Isar, Ismaninger Street 22, 81675 Munich, Germany (e-mail: andreas.kolk@tum.de).

J Reconstr Microsurg Open 2017;2:e103–e110.

Abstract

Background The free fibular flap (FFF) is established for mandibular reconstruction. Some complications, such as non-union, fistulas, and complete graft loss, are sometimes unavoidable. There are no clinically relevant data regarding the optimum selection of osteosynthesis and risk analysis prior to reconstruction.

Methods Eighty-three FFFs with up to four osteotomies were analyzed for possible complications during the course of a longitudinal analysis. Forty-one patients underwent simultaneous mandibular reconstruction after tumor resection, and another 42 subjects received FFFs due to infected osteoradionecrosis (ORN). Patients who experienced transplant losses due to vascular occlusion in the grafts were excluded from the study.

Results The most common complications were fistulas, bony non-union, and failure of osteosynthesis material. Major contributing risk factors were radiotherapy ($p = 0.004$), number of osteosynthesis plates >6 ($p = 0.002$), length of the harvested fibula ($p = 0.027$), the size of the skin island ($p = 0.002$), and the number of osteotomies ($p = 0.001$).

Conclusion For the success of FFF, there are many influencing factors. If the mentioned risk factors are considered, the number of osteotomies, size of the skin paddle, and fibula are as small as possible, and a suitable osteosynthesis material is chosen, the FFF is a safe solution for mandibular reconstruction.

Keywords
- free vascularized bone transfer
- osteocutaneous free fibula flap
- mandibular reconstruction

The partial or even complete loss of the mandible may cause considerable functional, aesthetic, and social problems. Simultaneous reconstruction of the mandible is, therefore, the primary treatment goal. The aim is to achieve restoration of oral function, including the possibility of implant-supported prosthetic restoration and improved aesthetic appearance, which enhance quality of life.[1,2]

Compared with the alternative iliac crest or scapula grafts, the advantages of free fibular flap (FFF) include the presence of bicortical dense bone of usually adequate quality, the predictable incorporation of an individualized skin island, and vascularization that is achieved via perforators and only to a small extent via the periosteum allowing multiple osteotomies to restore the original design of the resected part of the mandible, predominantly in the chin region.[3,4]

Although the success rates of FFF for mandibular reconstruction are reported to be >90%, some major and minor obstacles arise, especially in patients undergoing simultaneous malignant

received
February 19, 2017
accepted after revision
June 11, 2017

DOI https://doi.org/10.1055/s-0037-1604343.
ISSN 2377-0813.

tumor resection or mandibular reconstruction attributable to infected osteoradionecrosis (ORN).[5,6]

Many patients suffer not only from a bone defect, but also from an intra- and/or extra-oral soft tissue deficiency that requires a composite or even double flap replacement. The challenge in bony reconstructions of lower jaw defects is the attainment of the correct three-dimensional shape and size and the placement of the bones in the suitable position with sufficient contact areas between the respective FFF segments due to anatomical and biomechanical aspects.[7] Interestingly, even after bony and soft tissue reconstruction, only a minority of patients achieve sufficient prosthodontic rehabilitation in terms of restitutio ad integrum.[4,8,9] The primary objective of this longitudinal study was to evaluate risk factors for the postoperative outcome of FFF. Therefore, patients were recruited with the following goals:

(1) to evaluate the results of mandibular reconstruction with FFF simultaneous to the resection of tumors adjacent to the mandible or with secured bone invasion or infected ORN (ORN) and
(2) to analyze the long-term risk factors for postoperative flap complications especially impaired bony graft consolidation.

Patients and Methods

Study Design

Between December 2007 and April 2011, all patients admitted for mandibular reconstruction with an FFF were considered for this study. To exclude the immediate risk of flap loss and associated complications, patients were included in this study 6 months after receiving an FFF.

Out of total 126 FFF transfers, a homogeneous subgroup of 83 patients (51 men and 32 women) was recruited for this longitudinal analysis comprising of two sub-groups: (I) primary mandibular reconstruction after segmental mandibulectomy for simultaneous curative surgical treatment of oral squamous cell carcinoma (OSCC) invading the mandible in 41 cases and (II) lower jaw replacement after resection of a defective mandibular part attributable to severely infected ORN ($n = 42$) (►**Table 1**). The average time between the end of radiation therapy (RT) and decision making for bone replacement via an FFF was 26 months (range 18–88).

This study was approved by the hospital's ethics committee of the Klinikum rechts der Isar, University of Technology, Munich, Germany and was conducted in accordance with the Declaration of Helsinki. All patients provided written informed consent for the operation and follow-up protocol.

Planning and Reconstruction of the Lower Jaw

For definitive planning of lower jaw reconstruction, the final extension of the resulting mandibular defects after tumor resection or replacement of the osteoradionecrotic bone were subdivided using the BSB classification of Urken (S, B, R, and combinations of each) (►**Table 2**).[6]

All FFFs were harvested with a skin paddle with an average size of 16 cm^2 (range 10–25 cm^2) from the central or distal third of the lower limb with careful protection of the perforators. The skin paddle served as intra- or extra-oral defect coverage and as a monitor for FFF perfusion.

Decision-making regarding the size and shape or number of osteotomies was performed according to preoperative planning and intraoperative assessment of the required extent of mandibular resection. In cases of secondary reconstruction attributable to infected ORN or mandibular reconstruction requiring two or more osteotomies of the FFF, osteotomy sites of the jaw and FFF as well as reconstruction were planned via an stereolithographic model.

Table 1 Baseline characteristics and medical conditions

Variables	
Age (y)	22–83 (MA 56.17)
Sex	
Male	51
Female	32
Smokers	
Yes	43
No	40
Alcohol abusers	
Yes	61
No	22
General disorders	
Arteriosclerosis	8
Hypertension	16
COPD	6
Hepatitis C	1
Hepatitis B	3
Hyperthyreosis	2
Hypothyreosis	13
ASA-score 1/2	43
ASA-score 3	40

Abbreviations: COPD, chronic obstructive pulmonary disease; MA, mean age; y, years.
Note: Baseline characteristics and medical conditions of patients with FFF ($N = 83$).

Table 2 Proportion of resulting jaw defects

Defect	Number in %	No.
B	39.76	33
BS	19.28	16
S	6.02	5
BSB	25.30	21
BR	6.02	5
SBR	3.61	3

Note: Proportion of resulting jaw defects according to Urken et al.[6]
Abbreviations: B, body; S, symphysis; R, ramus of the mandible, respective combinations of different mandibular parts.

For representation of the perfusion of the respective FFF segments and to assess the flap perfusion patterns in general after harvesting and prior to the transfer to the neck and again after anastomosis, Indocyanine Green (ICG) fluorescence angiography was utilized as a real-time intraoperative tool.[13,14] The specific goal of ICG angiography in this study was to focus on the perfusion of the most distal segments of the two to three times segmented FFF.

Within the first 48 hours after surgery, all FFF were clinically analyzed for regular vascular perfusion according to a standard protocol and, in cases of critical clinical perfusion, by a laser Doppler flowmetry.[15]

Osteosyntheses

For osteosynthetic fixation of the fibula, two different types of 2.0 plates, either MODUS 2.0 (w/ or w/o bar) or MODUS TriLock 2.0, made by Medartis (Basel, Switzerland) were used.

MODUS TriLock plates provide a multidirectional and angular stable fixation by allowing locking screws to be fixed within a range of $\pm$ 15°, ensuring higher stability and reduction in the risk of screw loosening or dislocation. Compared with regular MODUS plates, the application of TriLock plates is more time consuming and requires a more experienced surgeon.

The choice of the osteosynthesis material (OM) and shape was made by the surgeon according to a biomechanical analysis from a previous study.[16]

In cases with three or more segments, MODUS TriLock 2.0 plates were preferred. MODUS 2.0 plates with bar were preferred in cases where the osteotomy was fixed with a small angle.

For all B, S, or BS defects, the FFF was connected with the remaining anterior and posterior lower jaw stumps in its basal part independent of the range of mouth opening.

Postoperative Treatment

In sub-group I, according to the German and various European guidelines for the treatment of OSCC (GEGTO), 34 patients received additional RT due to lower jaw bone infiltration of the OSCC or lymph node involvement.

RT was applied on the primary oral tumor region, including the replaced part of the mandible (50–66 Gy) and the involved neck regions, after unilateral or bilateral consecutive neck dissection for cases with positive lymph nodes (70 Gy).[17,18] RT was initiated at an average of 34 days (26–45 days) after surgery, so that the complete treatment was finished no later than 11 weeks after the initial diagnosis. For this study, a homogeneous sample was a prerequisite. Thus, patients who underwent preoperative RT or chemotherapy or who exhibited generally poor health or limited prognosis for any reason were excluded.

Postoperative Assessments

All patients received regular oncological follow-ups according to GEGTO during which the data presented in this study were acquired.[17,18]

In addition to a CT scan every 6 months after surgery, panoramic radiographs were performed at 1 week and 6 months (and 12 months if indicated) postoperatively to assess the ingrowth situation of the replaced lower jaw and to obtain a basis for decision-making, such as removing the OM and further bone augmentation prior to definite dental rehabilitation.

During the oncological follow-up, all patients were examined for bony union, fistulas, recurrent disease, function, aesthetics, and their individual judgement of the outcome. Postoperative functional outcomes included diet type (regular, soft, or liquid) and speech function (normal, nearly normal, intelligible, or unintelligible), which were obtained from a questionnaire issued within the first 2 years postoperatively.

Statistical Analyses

Descriptive statistics for quantitative variables are provided as the means $\pm$ standard deviations and, where appropriate, as medians and ranges. All figures were generated by and all data were analyzed with the "Statistical Package for the Social Sciences" (SPSS for Windows, release 17.0.0 2013; SPSS Inc.). All p-values (p) were unadjusted, two-sided, and subject to a significance level of $p < 0.05$. For exploration of different aspects and their complications in microsurgical reconstruction with the FFF, we performed a univariate logistic regression analysis. For the analysis of underlying factors (that were apparent during the long follow-up), a multivariate logistic regression analysis was performed with any complication considered as a dependent variable.

Results

Almost 50% of the patients, independent of the necessity for FFF replacement of the mandible, presented with compromised medical conditions as summarized by the ASA score 3 (►**Table 1**). This score had a significant influence on the immediate postoperative course, but not on the long-term success of the FFF, which was the focus of this study.

The average length of the harvested fibula was 13.1 cm (range 9.0–18.0 cm). An additional skin paddle, which had an average size of 16 cm^2 (range 10–25 cm^2), was used to repair intra-oral soft tissue defects in 82 patients and for an extra-oral soft tissue defect in only 1 patient.

The most frequently observed complications in this study were fistulas (34 out of 83 patients), which were treated according to ►**Table 3**.

The second most often observed complication within this cohort affected 22 patients and was associated with OM (►**Table 4**). All patients affected by this complication had been subject to at least two osteotomies. A total of 540 plates were applied, out of which 45 plates in 22 patients led to complications and formed a sub-collective that was divided in to three groups: fracture of OM, pseudarthrosis, and fistulas with exposure of OM.

The most common complication within this subgroup was fractures of OM. In this group, we witnessed significant differences based on the choice of OM, while 26.8% of the MODUS plates w/o bar failed, only 16.2% of the MODUS plates w/ bar and 6.7% of the TriLock plates were unsuccessful (►**Table 4**). Furthermore, we observed pseudarthrosis and

Table 3 Complication management

Long-term treatment of complications	($n = 83$ patients)
1	13
2	16
3	45 plates in 22 patients
4	3
5	5
6	5
7	16

Note: Number of patients requiring treatment of fistulas/wound healing disturbances after free fibular flap:
1 Successful non-surgical treatment (use of antibiotics and rinsing).
2 Excision of the fistula, revision of underlying bone and closure of wound defect with local flap.
3 Partial removal (and, if required, replacement of the OM).
4 Closure of extraoral wound defect with pectoralis major flap.
5 Closure of extraoral wound defect with radial forearm flap.
6 Closure of intraoral wound defect with tongue flap.
7 Partial loss of the FFF + 2/4/5.

fistulas with exposition of the OM and bone. These complications were also associated with the choice of OM, while 21.3% of the patients with MODUS plates w/o bar developed pseudarthrosis; only 13.5% of the patients with MODUS plates w/ bar and 0% with TriLock plates did. Moreover, 16.8% of the patients treated with MODUS plates w/o bar, 9.4% of the patients with MODUS w/o bar, and 0% of the patients with TriLock plates experienced a fistula with bone and OM exposition.

This complication mostly occurred with BSB or BS defects in the mandibular angle, especially in cases with reduced dentition of only one or two remaining molars on the contralateral angle site with succeeding biomechanical overload. It represented an additional risk factor with bony shaving that negatively influenced long-term success[6,10] (►**Tables 2** and **5**).

The above-mentioned complications led to partial removal and, if required, replacement of the OM in 18 cases (►**Table 3**). Among these removals, additional exposition of the respective FFF segment was necessary in 16 cases. If indicated, the necrotic bony part of the FFF was completely removed (fluorescence guided) (use of fluorescence light after 1 week administration of 2 × 100 mg/d tetracycline) according to the protocol as previously described for the treatment of ORN (►**Fig. 1**).[19]

Table 5 Numbers of free fibular flap segments

Number of osteotomies	Number of patients
0	30
1	26
2	22
3	4
4	1

Note: Characteristics of the free fibular flap.

Overall, several factors contributed to the complication rate as shown in the logistic regression analysis (►**Tables 6** and **7**). Further multivariate regression analysis revealed that five factors dominated with significant impacts on the long-term outcomes: male sex ($p = 0.04$), smoking >20 pack years ($p = 0.006$), the effective size of the skin paddle (>14.5 cm^2) predominantly in cases of two to three osteotomies ($p = 0.002$), FFF length of >10 cm, and number of OM plates >4. More than one osteotomy resulted in an increased rate of non-union and wound healing disturbance ($p = 0.027$). Additionally, in subgroup I, a time difference of <28 days between the FFF and the start of RT had a negative impact on the outcome ($p = 0.004$) (►**Tables 6** and **7**).

In addition to common and well-known risk factors, such as smoking and male sex, we identified further risk issues.

More than eight osteosynthesis plates also lead to a significant risk of material-associated complications with loosening and consecutive non-union ($p = 0.02$). According to a more extensive analysis, especially in the canine region, the distance between the first osteosynthesis of the osteotomy gap is responsible for non-union due to loosening of the plate and fistulas ($p < 0.05$). The contact surface of the grafts did not influence graft survival. However, the profile of the osteotomy significantly influenced graft survival (straight versus stepped ($p < 0.01$). In these cases, the choice of the OM was highly relevant regarding complications (►**Table 4**).

Postoperative RT, which was applied in subgroup I (34 out of 42), significantly increased the complication rate ($p = 0.004$) and was the main reason for long-term impaired healing complications.

Table 4 Complications associated with applied osteosynthesis

Complication (45 plates)	MODUS 2.0	MODUS 2.0 + bar	MODUS 2.0 TriLock®
Pseudarthrosis/non-union	21.3%	13.5%	0%
Plate fracture	26.8	16.2%	6.7%
Fistula with bone exposition	16.8%	9.4%	0%

Note: In this study, a total of 540, 297 MODUS, 160 MODUS 2.0 + bar, and 83 MODUS TriLock, plates, were applied in 83 patients. Twenty-two out of 83 patients experienced complication with applied osteosynthesis material, affecting 32 MODUS 2.0, 9 MODUS 2.0 + bar, and 4 MODUS 2.0 TriLock plates.

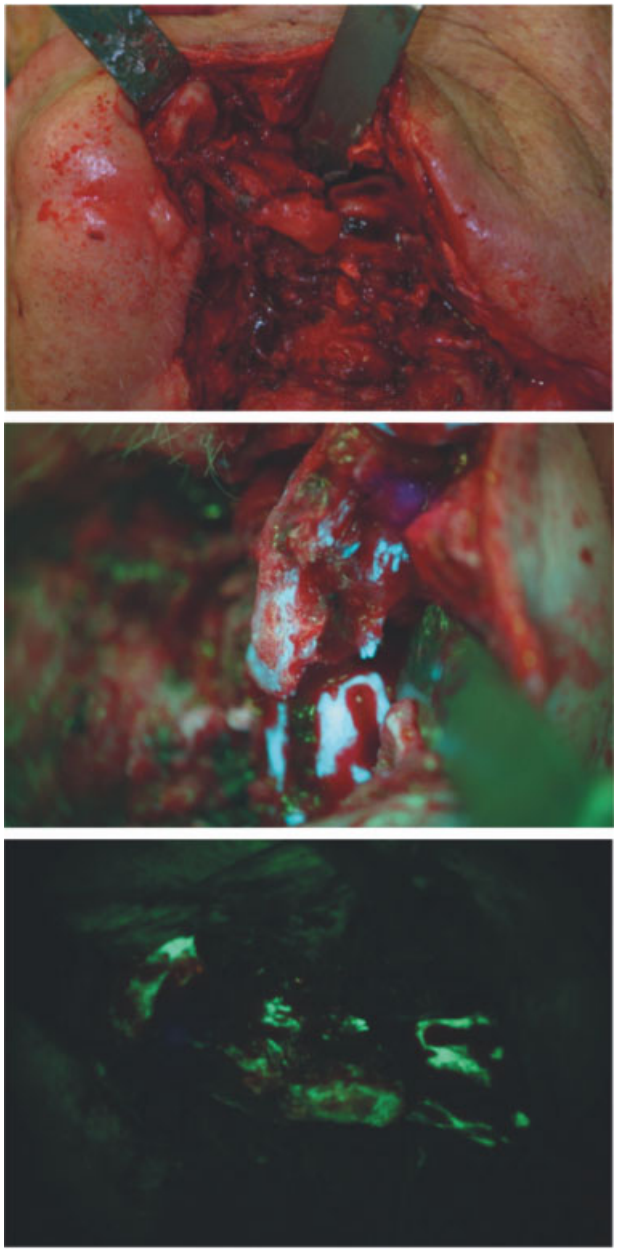

Fig. 1 Method of revision of osteotomy sites with incomplete bone ingrowth under assistance of ultraviolet -light and previous application of 100 mg tetracycline/day over 1 week.

Especially in the case of three to four FFF segments, the complication rate was 50% higher if followed by RT. Starting RT <28 days after FFF transfer led to even significantly more complications with additional wound healing problems regarding bone exposition and non-union ($p = 0.01$).

Generally, more than one osteotomy of the FFF, which is equivalent to three or more bony segments, led to a significantly higher rate of loosening of the OM and non-union or respective wound healing disturbances ($p = 0.001$). To analyze the underlying causes of the increased rate of complications in cases of three or four FFF segments, ICG was applied intraoperatively after transfer of the FFF from the lower leg to the neck and the completion of microvascular anastomosis.[13] ICG perfusion within the posterior segments was evaluated via a special camera (►**Fig. 2**). In a preliminary series, the graft exhibited a significantly weakened signal at the end of the last FFF segment, despite a constant enhancement in all segments displaying a weaker and partially insufficient perfusion (►**Fig. 2**).[14]

Patient age and impairments in general health exhibited no significant influence on the complication rate.

Discussion

Generally, the FFF is reliable for mandibular reconstruction following ablation of bone-invading OSCC or defects after unavoidable jaw resection due to ORN infections. The FFF has many advantages over other microvascular bone transplant.[2] In most cases, the functional deficit at the donor site was limited, and most patients were not troubled by their residual symptoms.[8] Although the FFF survival rate has been reported to range from 85 to 98%, data from other studies are difficult to compare with the results presented here as many cofactors can influence the outcome, and the initial condition of each patient is often highly variable.[20]

One of the major complication-promoting factors was postoperative RT of the graft bed leading to vascular fibrosis and endothelial damage[21] and lowered bone regeneration.[11] Patients in our series, with primary OSCC and bone infiltration or lymph node involvement as established by the pathologist, received RT with a resulting total dosage of 63 to 70 Gy. In sub-group I, the time between mandibular replacement and the start of RT was 42 days on average (range 24–59 days).

In sub-group II, patients underwent FFF reconstruction due to partial loss of the mandible after developing an ORN infection.

Only a few publications have reported the influence of RT on flap success.[22–24]

The duration between RT and FFF transfer significantly impacted the success (prolonged duration leads to an irregular capillary distribution).[21] This finding emphasizes the need for early decision-making to replace the mandible with microvascular free bone flaps if there are signs of irreversibly infected ORN. Smaller (local) revision concepts empirically do not lead to durable success concerning the preservation of the affected region of the jaw in this type of patient. The long period between the initial RT in sub-group II and the FFF (average 26 month) explains the high complication rate in this cohort. The impaired vascularization and microcirculation due to previous RT (sub-group II) caused a compromised wound healing basis and an insufficient local immune response to infections initiating complications especially in larger skin paddles.[25]

As mentioned, another risk factor proved to be a skin paddle size of >14.5 cm^2 ($p = 0.002$). Interestingly, in the beginning of the FFF era, harvesting long fibular skin islands was recommended to provide the highest chance for skin survival, presumably due to the presence of more perforating vessels in these flaps.[26–28] According to our results, the skin island should not be very large or small, which is possible

Table 6 Univariate logistic regression

	p	OR	95% CI	
Sex (male)	0.040	4.028	1.063	–15.268
Age	0.663	1.009	0.969	–1.051
Smoker (>20 pack years)	0.006	6.607	1.742	–25.064
Skin paddle size >16 cm^2	0.002	6.841	2.011	–23.269
Length of transplant >13.4 cm	0.027	3.533	1.152	–10.841
Osteotomy >1 (>2 bony FFF segments)	0.001	6.667	2.138	–20.787
Postoperative adjuvant RT	0.004	5.700	1.737	–18.703
No. of plates >6	0.002	6.841	2.011	–23.269
ASA score III	0.043	6.429	2.042	–18.091

Abbreviations: ASA score, American Society of Anestesiologists physical status classification system I–IV; CI, confidence interval; FFF, free fibular flap; No., number; OR, odds ratio; RT, radiation therapy.
Note: Risk factors for complications.

Table 7 Univariate and multivariate logistic regression

	Univariate				Multivariate			
	p	OR	95% CI		*p*	OR	95% CI	
Sex (male)	0.040	4.028	1.063	–15.268				
Age	0.663	1.009	0.969	–1.051				
Smoker	0.006	6.607	1.742	–25.064	0.020	6.217	1.340	–28.840
Skin paddle size ≥16 cm^2	0.002	6.841	2.011	–23.269	0.004	8.566	1.984	–36.985
Length FFF > 10 cm	0.027	3.533	1.152	–10.841				
Osteotomy > 1x	0.001	6.667	2.138	–20.787	0.003	8.452	2.106	–33.920
RTx post OP	0.004	5.700	1.737	–18.703				
Number OSM Plates > 6	0.002	6.841	2.011	–23.269				

Abbreviations: CI, confidence interval; FFF, free fibular flap; after OP, after operating procedure; OSM, osteosynthesis material; RTx, radiotherapy.

when the perforators are visualized before outlining the required skin island. In contrast, the skin island must be sufficiently large to ensure an adequate venous backflow, according to the vascular territories described by Taylor et al[29] Larger skin islands seem to cause a steel effect and prolong the time until autonomization of the FFF. Larger skin islands also have a larger predilection site for the development of saliva fistulas.

Although the FFF is a very flexible transplant, a length over 10 cm poses an additional risk factor. The longer the transplant, the more distally it must be harvested, which is accompanied by a smaller amount of septal perforators in this distal part.

Therefore, we observed significantly more losses of the distal segments in our series. Several possible causes can be proposed for this fact.

Generally distal losses may be attributable to the shorter length of the most distal segment, which decreases the reliability of complete and sufficient perfusion. It has to be taken into consideration that due to the lower number of septal perforators in the caudal part of the fibula, perfusion of these relatively small distal FFF-segments relies on sufficient periosteal perfusion. Damaging this integrity, e.g., by osteotomies, undermines the microcirculation, endangers the distal segment, and makes it more vulnerable to RT. Additionally, the thinning peroneal artery in the proximal-distal direction may create a trophic problem for this distal segments. Lastly, the optimal pattern of perfusion in the distal leg remains unclear; this is a more qualitative than quantitative issue. These thoughts are supported by the ICG perfusion analysis, which demonstrated decreased perfusion in the distal segments.

Regarding OM, which seems to be a crucial factor for long-term success especially for patients with more than one osteotomy, MODUS plates w/ bars and MODUS TriLock plates seem to break significantly less often than plates without bars. In the latter, the strain forces of the titanium are divided within a much smaller surface or diameter than those in the bar, and the screws are positioned very close to the osteotomy gap.

Furthermore, because of the screw angulation, TriLock plates ensure a better stabilization of the contacting fragments, and therefore granting a more sufficient bone healing. Consequently, in cases of more than one osteotomy, MODUS TriLock plates are favorable and significantly reduce the amount of OM-associated complications. To further reduce

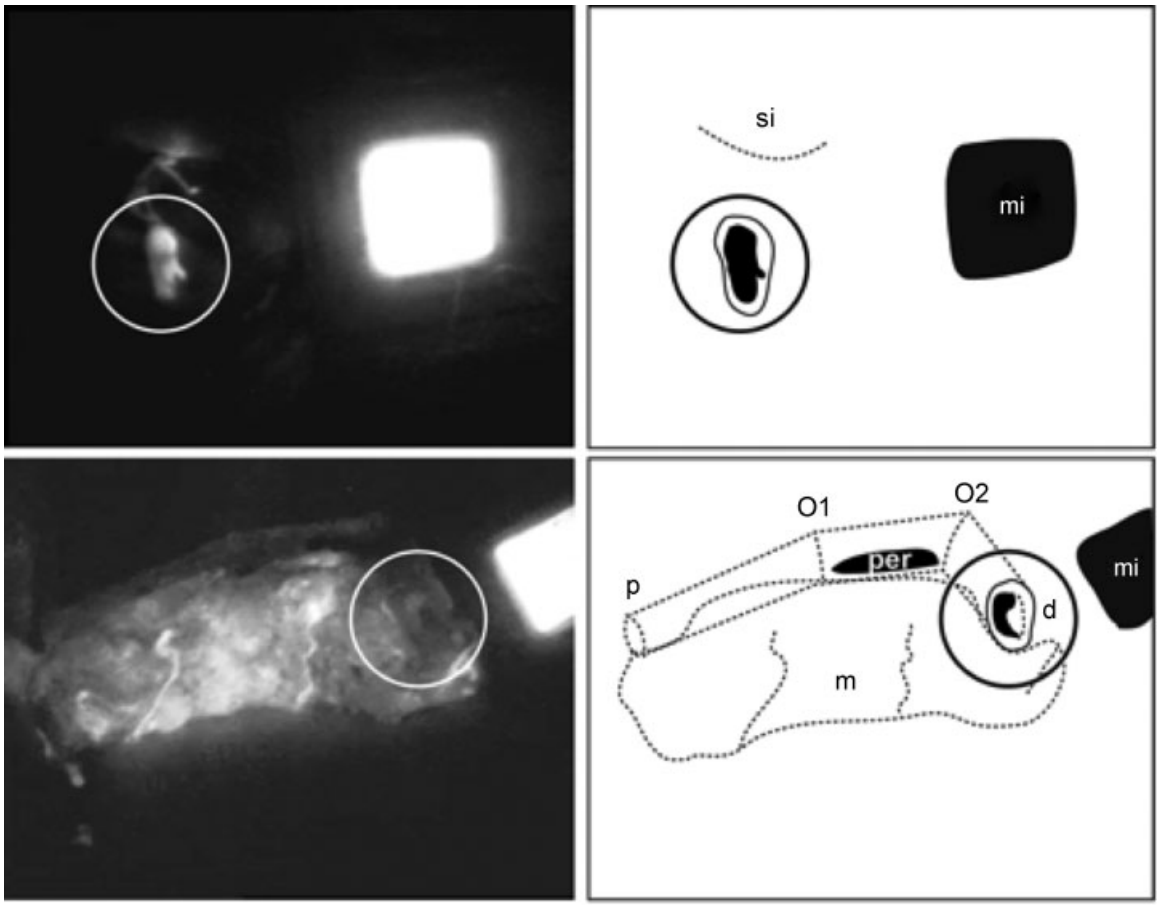

Fig. 2 Impact of the number of osteotomies on bone perfusion. Indocyanine-Green (ICG) fluorescence angiography was performed (1) directly after flap raise and proximal and distal osteotomy of the fibular bone (top images), as well as (2) after additional osteotomies and osteosynthesis (bottom images). The fluorescence signal was recorded using a mobile near infrared fluorescence camera (PDE Photodynamic Eye, Pulsion Medical Systems SE, Feldkirchen, Germany). Flow analysis was performed with IC-CALC (Version 2.0, Pulsion Medical Systems SE, Feldkirchen, Germany). Preliminary results show that after multiple osteotomies (bottom images) the ICG signal was weaker in comparison with fewer osteotomies (top images). The circles indicate the region of interest (distal fibular segment). Since ICG still images are usually hard to interpret, schematic drawings (left) were added. Si, skin island; mi, maximum intensity (reference); p, proximal osteotomy; d, distal osteotomy; O1, additional osteotomy 1; O2, additional osteotomy 2; m, muscle part; per, periostium.

the risk of plate loosening paramedian, a stepped osteotomy is favorable.

Other risk factors are the remaining teeth in the molar area, mostly on the contralateral side, which may cause atypical or strong bending forces on the plates with subsequent plate fracture, and screws located close to the osteotomy gap, which reduce vascularization and new bone formation. Hence, we do not advise leaving single teeth that will not play an eminently important prosthetic role. These teeth lead to abnormal biomechanical overload on the contralateral site, which can loosen the load-bearing OM.

Compared with Brown et al's extensive review, this study reports a relatively high complication rate concerning fistulas and especially non-unions.[12] We ascribe these findings to the fact that most of our patients experienced RT within their previous (sub-group II) or current (sub-group I) treatment, which we identified as a major risk factor. On the other hand, Brown et al discussed that especially non-unions are sometimes difficult to obtain without open revision and might therefore be underrepresented in studies about FFF in literature.[12]

Conclusion

Principally, the FFF is a suitable solution for the replacement of the resected lower jaw. However, some major factors can cause severe long-term complications. The choice of the OM, the question of RT combined with FFF, the size of the skin paddle, and the length of the harvested fibula should be addressed during planning. If these aspects are considered, and the number of osteotomies and size of the skin paddle and fibula are as small as possible, FFF is a very safe bone transplant option and is one of the most important steps for patients with oral tumors to regain their quality of life.

Note

The content of this article has been seen, read, and agreed upon by all designated authors. This article has not been submitted or published elsewhere.

Funding

None.

Conflict of Interest
None.

References

1 Hanken H, Wilkens R, Riecke B, et al. Is immediate bony microsurgical reconstruction after head and neck tumor ablation associated with a higher rate of local recurrence? J Craniomaxillofac Surg 2015;43(03):373–375
2 Papadopulos NA, Schaff J, Sader R, et al. Mandibular reconstruction with free osteofasciocutaneous fibula flap: a 10 years experience. Injury 2008;39(Suppl 3):S75–S82
3 Wolff KD, Ervens J, Herzog K, Hoffmeister B. Experience with the osteocutaneous fibula flap: an analysis of 24 consecutive reconstructions of composite mandibular defects. J Craniomaxillofac Surg 1996;24(06):330–338
4 Taylor GI, Corlett RJ, Ashton MW. The evolution of free vascularized bone transfer: a 40-year experience. Plast Reconstr Surg 2016;137(04):1292–1305
5 Weitz J, Kreutzer K, Bauer FJ, Wolff KD, Nobis CP, Kesting MR. Sandwich flaps as a feasible solution for the management of huge mandibular composite tissue defects. J Craniomaxillofac Surg 2015;43(09):1769–1775
6 Urken ML, Weinberg H, Vickery C, Buchbinder D, Lawson W, Biller HF. Oromandibular reconstruction using microvascular composite free flaps. Report of 71 cases and a new classification scheme for bony, soft-tissue, and neurologic defects. Arch Otolaryngol Head Neck Surg 1991;117(07):733–744
7 Götz C, Warnke PH, Kolk A. Current and future options of regeneration methods and reconstructive surgery of the facial skeleton. Oral Surg Oral Med Oral Pathol Oral Radiol 2015;120 (03):315–323
8 Hölzle F, Kesting MR, Hölzle G, et al. Clinical outcome and patient satisfaction after mandibular reconstruction with free fibula flaps. Int J Oral Maxillofac Surg 2007;36(09):802–806
9 van Gemert JT, van Es RJ, Rosenberg AJ, van der Bilt A, Koole R, Van Cann EM. Free vascularized flaps for reconstruction of the mandible: complications, success, and dental rehabilitation. J Oral Maxillofac Surg 2012;70(07):1692–1698
10 Jewer DD, Boyd JB, Manktelow RT, et al. Orofacial and mandibular reconstruction with the iliac crest free flap: a review of 60 cases and a new method of classification. Plast Reconstr Surg 1989;84 (03):391–403, discussion 404–405
11 Rocha FS, Dias PC, Limirio PH, Lara VC, Batista JD, Dechichi P. High doses of ionizing radiation on bone repair: is there effect outside the irradiated site? Injury 2017;48(03):671–673
12 Brown JS, Lowe D, Kanatas A, Schache A. Mandibular reconstruction with vascularised bone flaps: a systematic review over 25 years. Br J Oral Maxillofac Surg 2017;55(02):113–126
13 Ducic Y. Intraoperative free flap monitoring using Indocyanine Green. JAMA Facial Plast Surg 2015;17(06):427
14 Valerio I, Green JM III, Sacks JM, Thomas S, Sabino J, Acarturk TO. Vascularized osseous flaps and assessing their bipartate perfusion pattern via intraoperative fluorescence angiography. J Reconstr Microsurg 2015;31(01):45–53
15 Hölzle F, Loeffelbein DJ, Nolte D, Wolff KD. Free flap monitoring using simultaneous non-invasive laser Doppler flowmetry and tissue spectrophotometry. J Craniomaxillofac Surg 2006;34(01): 25–33
16 Trainotti S, Raith S, Kesting M, et al. Locking versus nonlocking plates in mandibular reconstruction with fibular graft–a biomechanical ex vivo study. Clin Oral Investig 2014;18(04):1291–1298
17 Kolk A, Jubitz N, Mengele K, et al. Expression of Y-box-binding protein YB-1 allows stratification into long- and short-term survivors of head and neck cancer patients. Br J Cancer 2011; 105(12):1864–1873
18 Wolff KD, Follmann M, Nast A. The diagnosis and treatment of oral cavity cancer. Dtsch Arztebl Int 2012;109(48):829–835
19 Pautke C, Bauer F, Bissinger O, et al. Tetracycline bone fluorescence: a valuable marker for osteonecrosis characterization and therapy. J Oral Maxillofac Surg 2010;68(01):125–129
20 Kruse AL, Luebbers HT, Grätz KW, Obwegeser JA. Factors influencing survival of free-flap in reconstruction for cancer of the head and neck: a literature review. Microsurgery 2010;30(03):242–248
21 Schultze-Mosgau S, Grabenbauer GG, Radespiel-Tröger M, et al. Vascularization in the transition area between free grafted soft tissues and pre-irradiated graft bed tissues following preoperative radiotherapy in the head and neck region. Head Neck 2002;24 (01):42–51
22 Aitasalo K, Relander M, Virolainen E. Microvascular free tissue transfers after preoperative irradiation in head and neck reconstructions. Acta Otolaryngol Suppl 1997;529:247–250
23 Gürlek A, Miller MJ, Amin AA, et al. Reconstruction of complex radiation-induced injuries using free-tissue transfer. J Reconstr Microsurg 1998;14(05):337–340
24 Mulholland S, Boyd JB, McCabe S, et al. Recipient vessels in head and neck microsurgery: radiation effect and vessel access. Plast Reconstr Surg 1993;92(04):628–632
25 Miller MW, Dean NR, Cannady SB, Rosenthal EL, Wax MK. Free tissue transfer for head and neck reconstruction in solid organ transplant patients. Head Neck 2012;34(08):1143–1146
26 Anthony JP, Ritter EF, Young DM, Singer MI. Enhancing fibula free flap skin island reliability and versatility for mandibular reconstruction. Ann Plast Surg 1993;31(02):106–111
27 Sanger JR, Matloub HS, Yousif NJ. Sequential connection of flaps: a logical approach to customized mandibular reconstruction. Am J Surg 1990;160(04):402–404
28 Hidalgo DA. Fibula free flap: a new method of mandible reconstruction. Plast Reconstr Surg 1989;84(01):71–79
29 Taylor GI, Palmer JH. The vascular territories (angiosomes) of the body: experimental study and clinical applications. Br J Plast Surg 1987;40(02):113–141