

# Bilateral Chronic Subdural Hematoma and Blindness: Bilateral Infarction to the Posterior Cerebral Artery following Evacuation of Bilateral Chronic Subdural Hematoma – A Rare Case Report and Review of Literature

Sneha Chitra Balasubramanian<sup>1</sup> Sendilkumar Adimoolam<sup>1</sup> Syamala Shunmugam<sup>1</sup>

<sup>1</sup>Institute of Neurosurgery, Madras Medical College and Rajiv Gandhi Government General Hospital, Chennai, Tamil Nadu, India

Address for correspondence Sneha Chitra Balasubramanian, MBBS, Institute of Neurosurgery, Madras Medical College, Chennai, Tamil Nadu 600003, India (e-mail: bsnehachitra@gmail.com).

Indian J Neurotrauma 2017;14:46–52.

## Abstract

**Objective** The authors report a rare scenario in which evacuation of bilateral chronic subdural hematoma (CSDH) was followed by bilateral PCA infarction and blindness. A literature review was also conducted, which revealed only four cases of blindness after CSDH evacuation.

**Methods** A 45-year-old man was admitted with the chief complaint of holocranial headache for 2 months with past history of head trauma. Clinical examination was normal. CT and MRI scanning showed bilateral frontotemperoparietal CSDH without midline shift and parenchymal and vascular abnormality. Bilateral frontal and parietal burr holes and evacuation of CSDH was done.

**Results** The patient developed progressive blindness in both the eyes in the postoperative period. MRI revealed bilateral PCA infarction.

**Discussion** Bilateral PCA infarction following bilateral CSDH evacuation is an extremely rare entity. Only four case of blindness following CSDH evacuation have been reported so far, and all the patients suffered permanent visual loss. The exact etiopathogenesis and mechanism of this rare complication remain unknown.

**Conclusion** Bilateral CSDH is a separate entity with altered pathophysiology and deranged cerebral autoregulation. The authors conclude that Bilateral CSDH may be sentinel tags for bilateral PCA infarction secondary to altered hemodynamics in the posterior circulation, and hence, needs to be evaluated and treated with greater diligence.

## Keywords

- ▶ bilateral CSDH
- ▶ bilateral PCA infarction
- ▶ postoperative cortical blindness

## Introduction

Chronic subdural hematoma (CSDH) is a common condition requiring neurosurgical intervention and most often results in a favorable outcome. It is usually seen after a trivial head trauma leading to the rupture of the cortical bridging veins, but it can also occur spontaneously in the presence of

coagulopathy. Although unilateral CSDHs occur more commonly, bilateral CSDHs are being increasingly diagnosed. The incidence of bilateral CSDH has been reported as 16 to 20%.<sup>1</sup> Bilateral CSDHs usually manifest without any neurologic deficits, and have been reported to be associated with rapid progression requiring early

received  
April 2, 2017  
accepted  
May 29, 2017  
published online  
July 24, 2017

© 2017 Neurotrauma Society of India DOI <https://doi.org/10.1055/s-0037-1604052>.  
ISSN 0973-0508.

decompression. They are also known to have higher recurrence rates. Blindness due to bilateral infarction of the posterior cerebral artery (PCA) following bilateral chronic subdural evacuation is an extremely rare entity. Only four cases have been reported so far, with this case being the fifth one. The exact etiopathogenesis and mechanism of this rare complication remain unknown. In all the previously reported cases, the patients suffered permanent visual loss. The authors evaluate one such scenario in which evacuation of bilateral chronic subdural hemorrhage was followed by bilateral PCA infarction and cortical blindness.

## Case Report

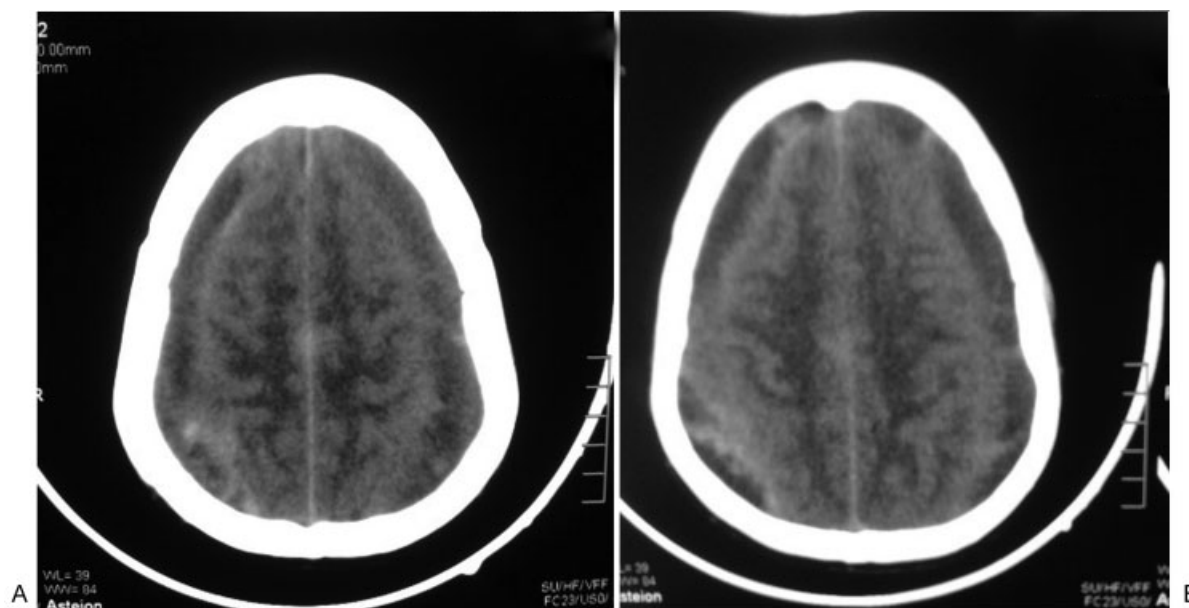
A 45-year-old man was admitted with complaint of holocranial headache for 2 months, which progressively worsened and was not associated with vomiting or visual obscuration. The patient had history of head trauma caused by fall from a two-wheeler 2 months back. Clinical examination revealed no abnormalities. Computed tomography (CT) and magnetic resonance imaging (MRI) scanning showed bilateral frontotemporoparietal chronic SDH without parenchymal and vascular abnormality. There was no midline shift (→Fig. 1A to D). Magnetic resonance angiography (MRA) and magnetic resonance venography (MRV) were normal. Blood investigations were normal. There were no comorbid medical illness or risk factors associated with coagulopathy. Bilateral frontal and parietal burr holes and evacuation of CSDH was done. The procedure was uneventful.

The patient developed decreased vision in both the eyes in the immediate postoperative period that proceeded on to complete blindness by the second postoperative day. On

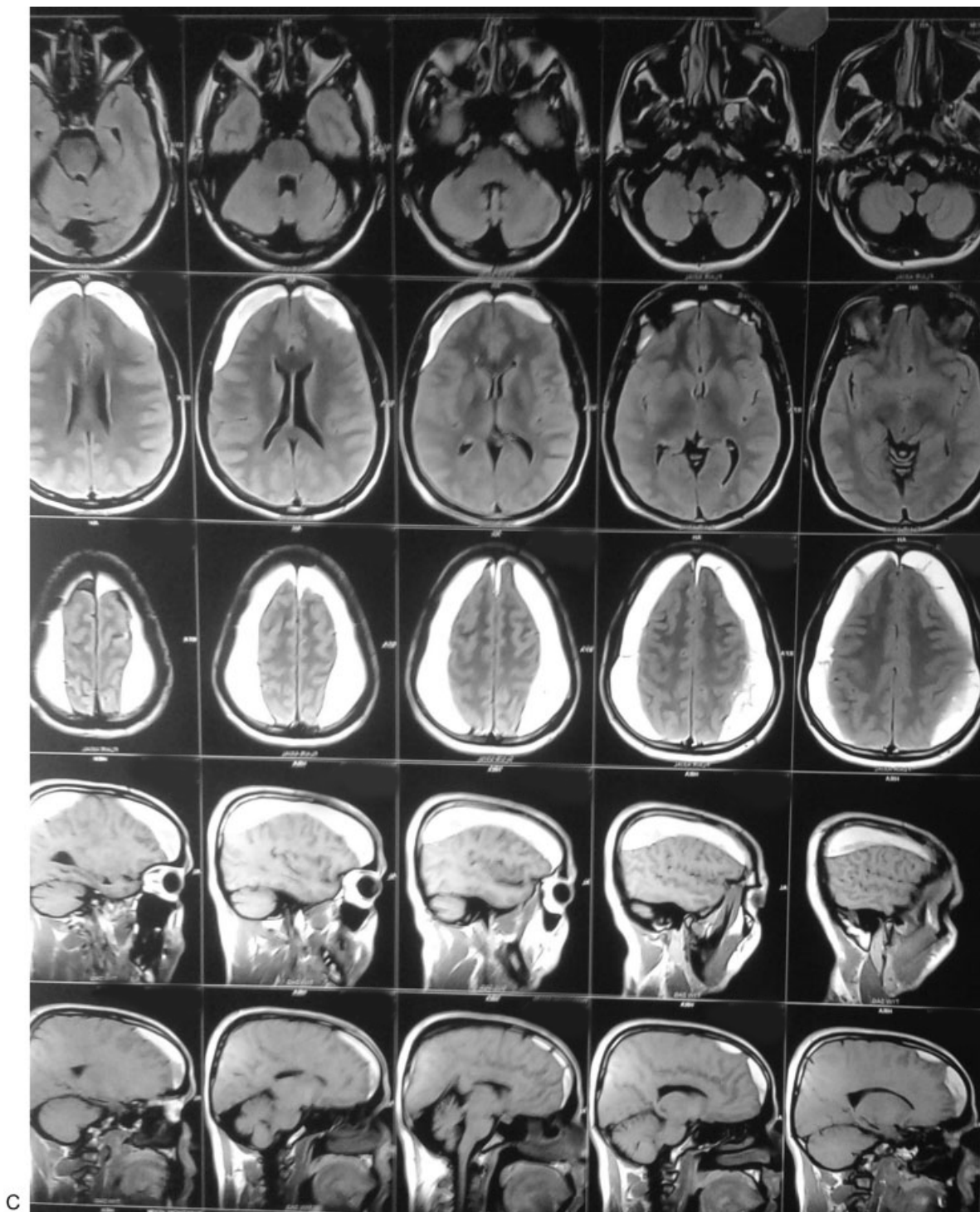
clinical examination, there was no perception of light, the pupils were equal, and reacting and fundus examination was normal. Except for cortical blindness, the patient did not have any other neurologic deficit. Postoperative MRI revealed bilateral PCA infarction. There was no midline shift and only a minimal residual subdural hemorrhage (→Fig. 1E to K). Hematologic and rheumatologic assessment for coagulopathy was negative. Cardiac assessment was normal. The lipid profile of the patient was within normal limits. Transcranial ultrasound (USG) Doppler was done, which showed no abnormality in both the intracranial and extracranial arteries. The blood flow and velocity in bilateral PCAs were normal and symmetrical. A repeat MRI done after 2 weeks showed persistent bilateral occipital lobe infarction. The patient was followed up for a period of 1 year during which there was no recovery in the vision.

## Discussion

Cortical blindness is a rare neurologic condition characterized by loss of vision in the presence of an intact anterior pathway. It is usually binocular with preserved pupillary reflexes.<sup>2</sup> It occurs due to ischemia of the occipital cortex due to a local event such as embolism or hemorrhage or, more commonly, due to global hypoperfusion. Aldrich et al have postulated that the occipital cortex is very sensitive to systemic hypoxia because of its distant location from the central cerebral circulation.<sup>3</sup> Cortical blindness has been associated with cerebral venous thrombosis, during pregnancy, and PCA infarction. Rarer causes include occipital head trauma causing extradural or subdural hemorrhage, carbon monoxide poisoning, and neoplasms. Common etiologic factors for a PCA stroke include cardiogenic embolization,



**Fig. 1** Preoperative CT of brain (A, B); preoperative MRI (C–E); postoperative CT (F, G); postoperative MRI (H); postoperative MRI: DWI (I); MRA (J); MRV (K, L). A–D showing bilateral frontotemporoparietal chronic SDH without midline shift. E–G showing postcraniotomy status with minimal residual chronic subdural without any midline shift. H postoperative MRI DWI showing bilateral PCA territory infarction; with normal MRA (I) and MRV (J and K).



**Fig. 1** (Continued)

atheromatous disease of the proximal vessels, dissection of the proximal vessel, and intrinsic PCA atheromatous disease. Less common etiologies include migrainous cerebral infarction, hypercoagulable disorders, illicit substance use, vasculitis, and fibromuscular dysplasia. Rare causes include postsurgical especially cardiac surgery and following angiography—both cerebral and coronary, wherein cortical blindness may occur due to disruption of the blood-brain

barrier following angiography, concurrent hypotension, embolism, and vasospasm.<sup>3</sup>

Cortical blindness occurring due to bilateral PCA infarction following bilateral chronic subdural evacuation in the absence of any other associated risk factor is an extremely rare presentation. Only four cases of blindness following surgical decompression of CSDH have been reported and published in the literature so far. The exact

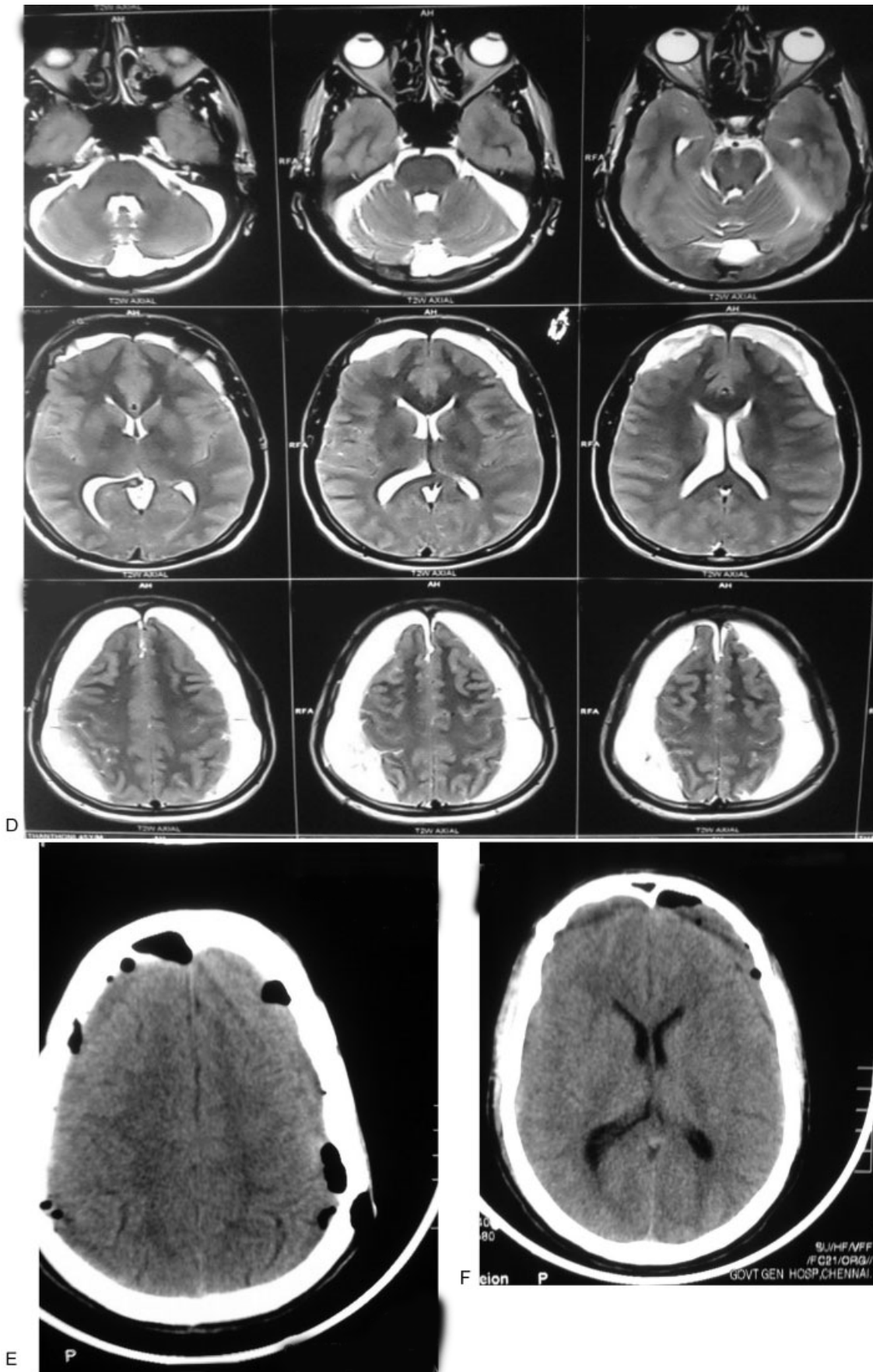
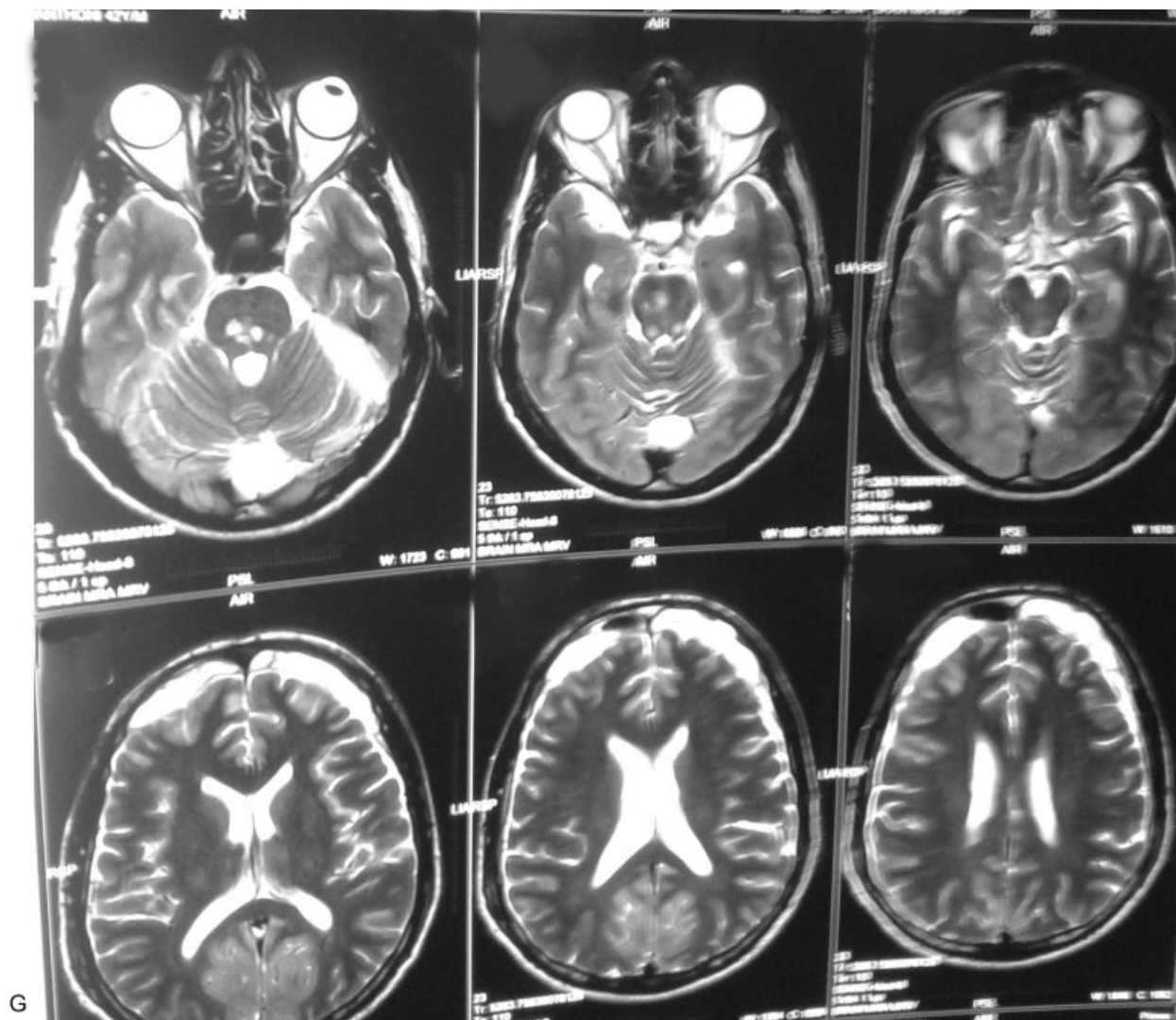


Fig. 1 (Continued)



**Fig. 1** (Continued)

pathophysiology behind this rare complication remains to be understood.

Kaene reported the first case in 1980 when the author documented seven cases with permanent visual loss following decompression for tentorial herniation. The causes were unilateral subdural hematoma in three patients and bilateral CSDH, bilateral subdural empyema, traumatic intracerebral hematoma, and postoperative infarction in one patient each. The authors speculated that descending transtentorial herniation occurring during the decompression could have led to the kinking of the bilateral posterior cerebral arteries and consequent occipital lobe polar ischemia and infarction. Among these patients, three went on to develop optic atrophy that indicated that both damage to the anterior visual pathway and posterior circulation compression had occurred.<sup>4</sup>

Russeger et al have reported the second case of a 51-year-old patient who developed bilateral blindness following decompression of a traumatic CSDH. The patient

had bilateral optic atrophy, and the authors have postulated breakdown of the altered vasoregulation of the optic nerve occurring at the time of intracranial pressure drop during the decompression had caused the optic atrophy and consequent amaurosis.<sup>5</sup>

The third and fourth case reports by Kudo et al describe two patients developing occipital infarction and blindness following bilateral chronic subdural evacuation. Both the patients had a poor Glasgow coma scale (GCS) on admission, and their CTs revealed ambient and interpeduncular cistern compression. The authors have attributed the severe sequelae to occipital infarction caused by central transtentorial herniation.<sup>6</sup>

The patient in this case reported by the authors presented with GCS 15, and preoperative imaging did not reveal any midline shift. Also, there were no associated comorbid illness or risk factors for stroke. A sudden drop in intracranial pressure (ICP) during the decompression could cause vascular jeopardization to the optic pathways

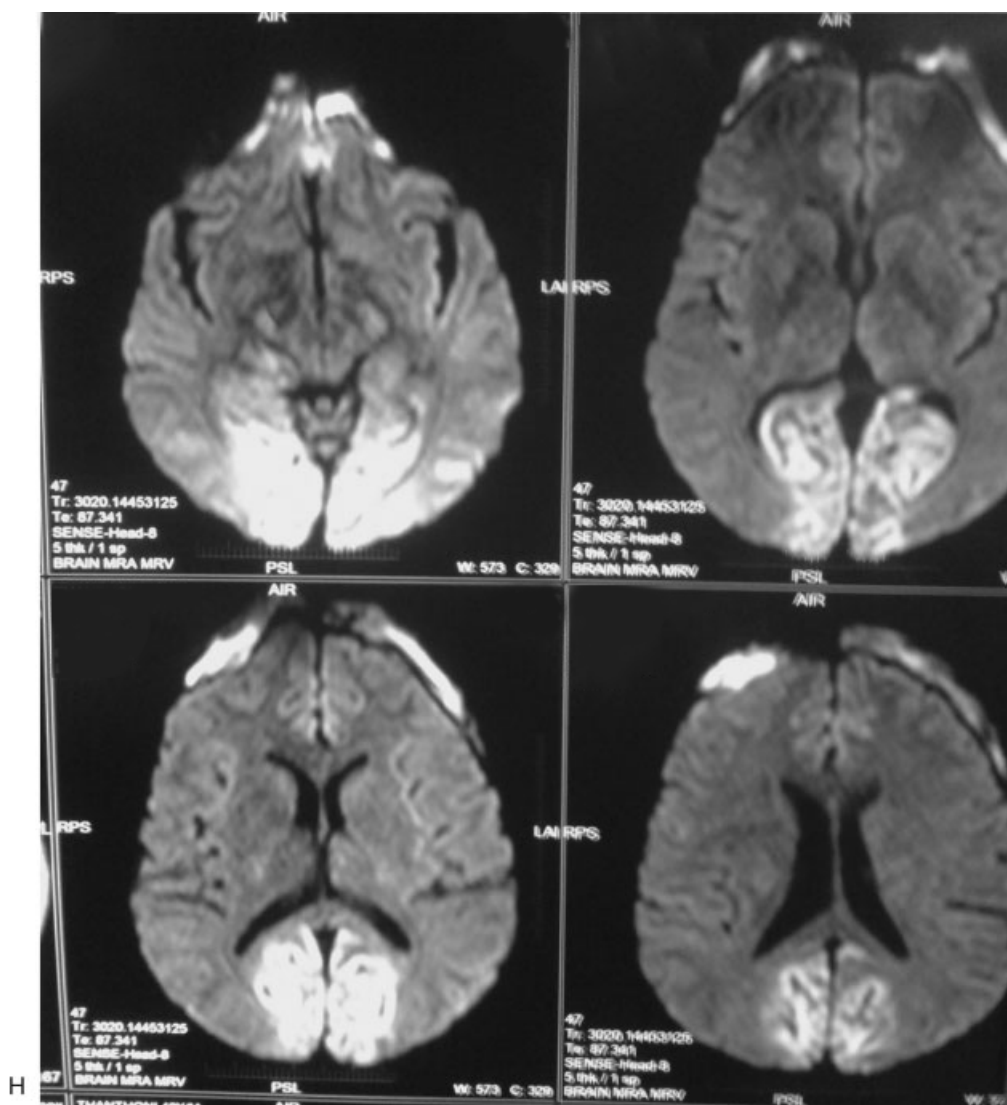


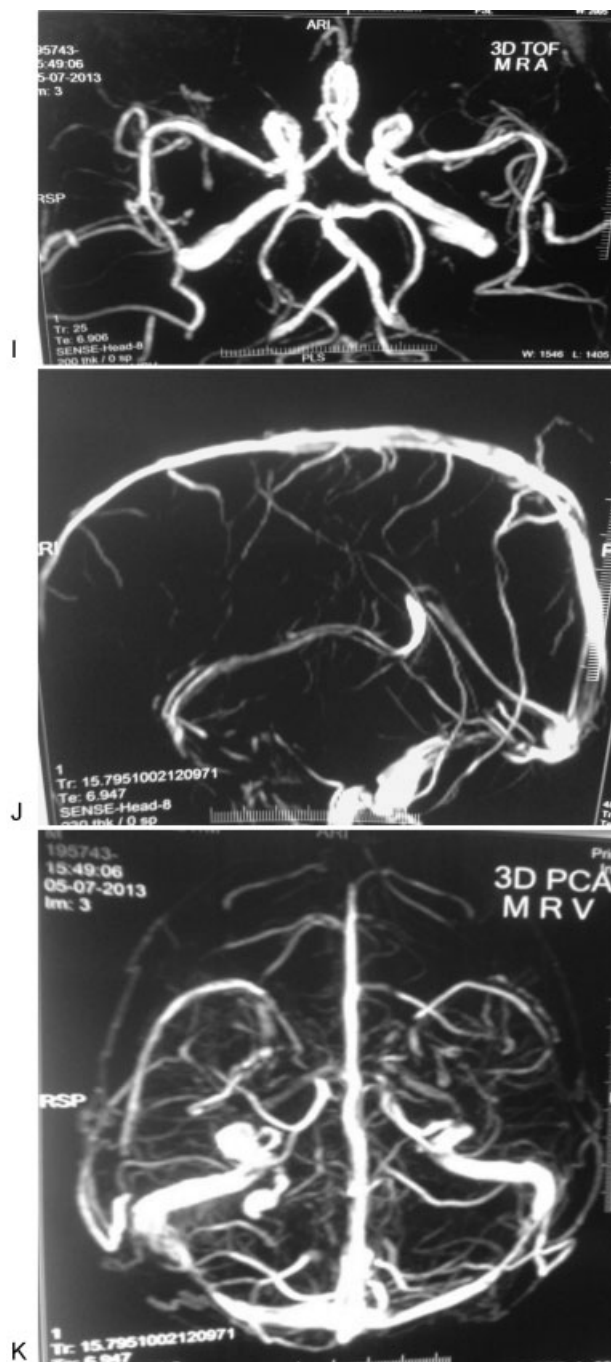
Fig. 1 (Continued)

bilaterally, but the presence of normal anterior pathway and selective posterior pathway involvement occurring with cortical blindness as in our case goes against this theory. The authors postulate descending transtentorial herniation that occurred during the evacuation of the hematoma as the reason for the bilateral occipital infarction caused by the kinking of bilateral PCAs against the tentorial margin. Another possible explanation is the preexisting hypoxic insult to the PCA due to the chronic compression by the bilateral subdural hematoma could have aggravated the infarction following the decompression. In our case, the authors believe that preexisting chronic ischemia has led to the decrease in brain volume, thereby giving space for the collection of the chronic subdural hemorrhage, and subsequent surgical evacuation has caused the worsening of the ischemia resulting in PCA infarction.

In recent times, bilateral CSDH is being recognized as a distinct entity with altered hemodynamics in the cerebral circulation. Although the pathophysiology behind bilateral

subdurals is not well known, it is postulated that trauma to the bridging veins leads to the hematoma similar to that of a unilateral chronic subdural hemorrhage. Age more than 75 years, use of antiplatelet and anticoagulation medication, hemodialysis, and preexisting coagulopathy are known to be risk factors for the occurrence of bilateral CSDHs.<sup>1</sup> The clinical presentation is usually vague and variable, and neurologic deficits occur less commonly. Most patients with bilateral CSDH present with headache, nausea, and vomiting. Bilateral CSDHs are more common in the old-aged men and do not have any midline shift on CT.<sup>7</sup> Several studies have also shown bilateral CSDH as a risk factor for recurrence.

Kurokawa et al have found rapid deterioration occurring in patients with CSDHs and advocate early and simultaneous decompression in these patients even if they show no or minor clinical deficits. They attribute the rapid aggravation due to the impaired autonomic buffering capacity of the raised ICP and coagulofibrinolytic abnormality in the hematoma.<sup>8</sup>



**Fig. 1** (Continued)

Tanaka et al in their study have suggested that CSDH may induce neurologic dysfunction primarily through mechanical distortion of the central brain regions and transneuronal depression occurring in the distant regions<sup>9</sup> Okuyama et al measured cerebral blood flow (CBF) in 34 patients with bilateral CSDH and found that in the patients with brain shift, the CBF reductions are noted in the frontal, parietal, and occipital cortices in the thin hematoma side and in the putamen in the thick hematoma side. Based on their results, the authors postulated the shifted force of the CSDH is accompanied by a secondary CBF reduction in the deep cerebral regions and is the major cause of neurologic dysfunction.<sup>10</sup>

## Conclusion

CSDH is a frequently encountered problem in neurosurgical practice. As Gelabert-Gonzalez et al have stated: CSDHs are perceived as “common lesions that are easily treated with a minimum morbidity and mortality.” Bilateral CSDH, however, is a separate entity with altered pathophysiology and deranged cerebrovascular autoregulatory mechanisms, and it needs to be treated with greater diligence. Early and simultaneous decompression is recommended for bilateral CSDH to prevent rapid deterioration and neurologic sequelae. Blindness following the evacuation of bilateral CSDH is an extremely rare complication, and yet again it reinforces the fact that bilateral chronic subdural hemorrhage should not be dismissed as a benign disorder.

### Conference Presentation

This case was presented (as a flash paper presentation) by Dr. B. Sneha Chitra at NSICON (Neurological Society of India), 2014, Coimbatore, Tamil Nadu, India.

### Funding

None.

### Conflict of Interest

None.

### Acknowledgment

None.

## References

- Huang Y-H, Yang K-Y, Lee T-C, Liao C-C. Bilateral chronic subdural hematoma: what is the clinical significance? *Int J Surg* 2013; 11(07):544–548
- Galetović D, Karlica D, Bojić L, Znaor L. Bilateral cortical blindness—Anton syndrome: case report. *Coll Antropol* 2005; 29(Suppl 1):145–147
- Aldrich MS, Alessi AG, Beck RW, Gilman S. Cortical blindness: etiology, diagnosis, and prognosis. *Ann Neurol* 1987;21(02):149–158
- Keane JR. Blindness following tentorial herniation. *Ann Neurol* 1980;8(02):186–190
- Russeger L, Langmayr JJ, Twerdy K. [Chronic subdural hematoma as a cause for blindness] [in German]. *Neurochirurgia (Stuttg)* 1992;35(06):207–209
- Kudo K, Naraoka M, Shimamura N, Ohkuma H. [Chronic subdural hematoma (CSH) complicated by bilateral occipital lobe infarction: two case reports] [in Japanese]. *No Shinkei Geka* 2013;41(04):319–322
- Gelabert-González M, Arán-Echabe E, Bandín-Diéguez FJ, et al. [Bilateral chronic subdural haematoma: analysis of a series of 190 patients] [in Spanish]. *Neurocirugia (Astur)* 2016;27(03):103–111
- Kurokawa Y, Ishizaki E, Inaba K. Bilateral chronic subdural hematoma cases showing rapid and progressive aggravation. *Surg Neurol* 2005;64(05):444–449, discussion 449
- Tanaka A, Nakayama Y, Yoshinaga S. Cerebral blood flow and intracranial pressure in chronic subdural hematomas. *Surg Neurol* 1997;47(04):346–351
- Okuyama T, Saito K, Fukuyama K, Yamamoto K, Morimoto M, Aburano T. [Clinical study of cerebral blood flow in bilateral chronic subdural hematoma measured by 99mTc-HMPAO SPECT] [in Japanese]. *No To Shinkei* 2000;52(08):709–714